

Esthetic rehabilitation of anterior teeth by fiber-reinforced composite: A case report

Krishna Kumar Varshney^{1*}, Vishwas Bhatia², Punit Raj Singh Khurana³

¹Post Graduate, ²Professor, ³Professor and Head, Dept. of Prosthodontics, I.T.S Dental College, Hospital and Research Centre, Greater Noida, Uttar Pradesh, India

***Corresponding Author: Krishna Kumar Varshney**

Email: krishnakrvarshney@gmail.com

Abstract

Patients refusing implant surgery for psychological reasons, where minimal reduction of tooth is preferred, a fiber-reinforced composite fixed partial denture can be a good alternative to conventional prosthetic techniques. In comparison to other restorative systems this is a conservative approach carries a minimum jeopardy of pulp exposure or sensitivity and periodontal inflammation, maintaining the health of supporting tissues. The aim of this case report is to describe the clinical procedure for fabricating an IFPD with a pre-impregnated glass fiber system and a hybrid composite. Fiber-reinforced composite, in combination with adhesive techniques, appears promising for an IFPD. Further clinical investigation will be required to provide additional information on this technique.

Keywords: Adhesive dentistry, Fiber-reinforced composite, Glass fibers, Metal-free restorations.

Introduction

A variety of treatment modalities, ranging from implants to conventional Maryland bridges, can be used for the replacement of a missing anterior tooth. Nowadays, the fibre reinforcement composite resins have adequate fracture toughness and hardness.¹ Fiber-reinforced composite (FRC) bridges can be a good substitute for conventional prosthetic techniques. An Indirect technique was used to fabricate a Maryland-like composite bridge for the replacement of a missing central permanent incisors.^{2,3} This treatment modality offers non invasive, conservative and esthetic treatment. Also, this technique is economical, non - iatrogenic and non – irritating.^{4,5} FRC bridges can be considered as a permanent treatment or a provisional treatment depending upon the situation.

Indirect fibre-reinforced composite bridges can be an alternative treatment modality for patients who cannot afford the expenses of implant.⁶ It can also act as a short term temporary prosthesis in case where planning for implant prosthesis in future.⁷ While for definitive long-term treatment there is limited evidences.^{8,9} So, the indirect fibre reinforced composite resin bridges can be considered as a economical and conservative treatment option for single missing tooth.¹ Here we are reporting a clinical case in which a Fibre reinforced bridge was fabricated using indirect technique for the replacement of missing central permanent incisors.

Case Report

A 22-year-old girl visited the department of Prosthodontics with a chief complaint of missing anterior teeth since 8 months. The patient revealed no specific medical history, with the dental history of periodontitis which was accountable for the extraction of the mandibular permanent central incisors (Fig. 1).

Since the patient was a female patient, esthetic aspect plays a very important role in the treatment. All treatment options, from implant to conventional Maryland bridge, were possible to the patient. After explaining all therapeutic

options to the patient, it was planned to place a FRC Maryland-like bridge until implant treatment was planned. After the lingual preparation of the teeth, an impression was made with putty light body for the FRC bridge fabrication. The impression was poured in die stone. The ribbon was directly adapted to the working cast.

Using instruments, the ribbon was placed over the cast and uncured composite was applied. The ribbon lies between the prepared abutment crossing the pontic. The composite between the teeth and ribbon was kept very thin. The ribbon was light cured for 40 seconds which became a strong framework. Then, a second fragment was placed in the pontic region. Using Teflon coated instruments, pontic teeth was built on the model with the help of composite resin. This technique provided a smooth and hard surface. To obtain a life like esthetic results, a composite system (Swiss TEC, Coltene) containing various shades of enamel and dentin was used.

Dentin shades were placed internally and then covered by enamel shades. The bridge was finished and polished using polishing abrasives kit (Shofu). The bridge was checked for its fit and rinsed with alcohol then, rinsed with water and air dried. Acid-etching was done (Scotchbond™ Universal Etchant, 3M ESPE) for 1 minute and again rinsed and completely air dried. After that porcelain primer (Silane, 3M ESPE) was applied for 30 seconds and air dried (Fig. 2).

Enamel were etched with 32 per cent phosphoric acid (Scotchbond™ Universal Etchant, 3M ESPE) for 30 seconds. After rinsing, it was air dried, and double coat of a universal adhesive was applied (One Coat Bond, Coltene). It was light cured for 10 seconds and a thin layer of luting composite (RelyX U200, 3M ESPE) was applied on the internal surface of wings. The bridge was then inserted. Once in place, it was held firmly in position. Using a probe and brush, excess cement was removed. The bridge was light cured for 2 minutes and then, occlusion was checked before intraoral polishing. The final bridge was a well-adapted with a life like esthetic results (Fig. 3,4).

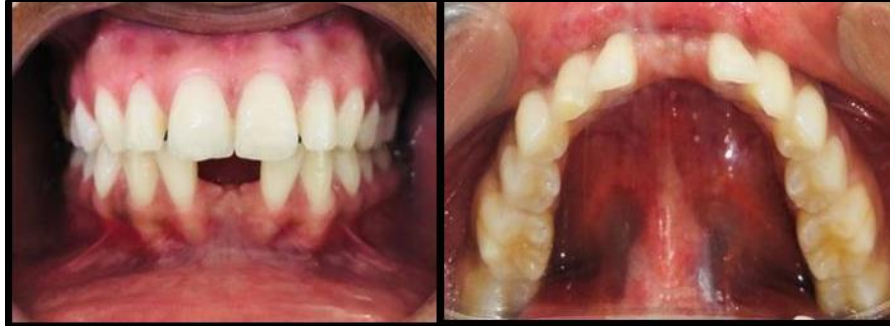

Fig. 1: Preoperative frontal view with a missing mandibular central incisors

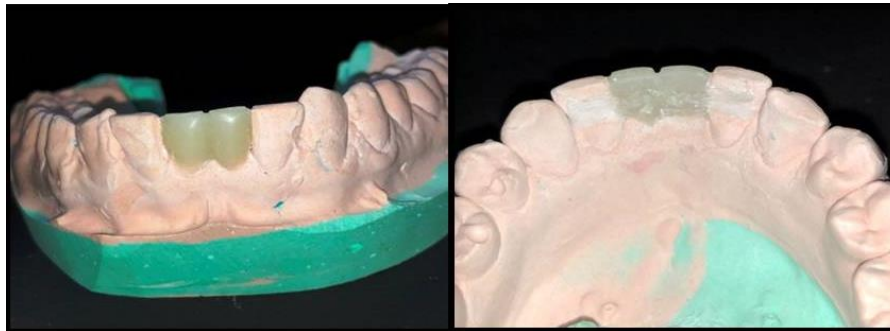


Fig. 2: Final prosthesis after finishing and polishing

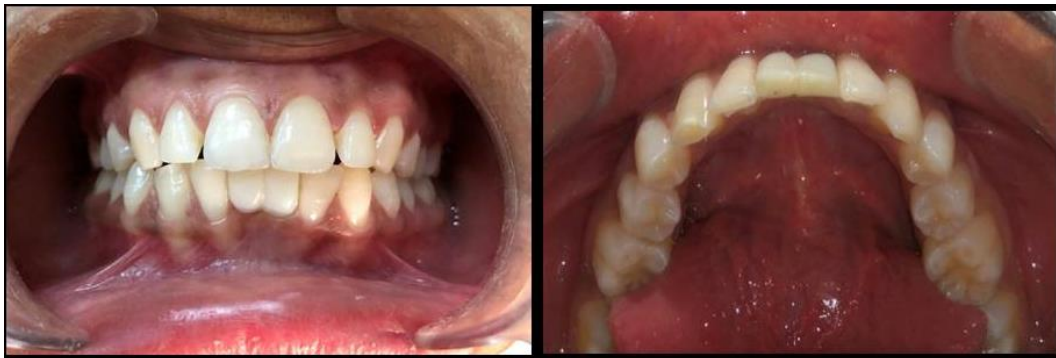

Fig. 3: Final intraoral view of the finished bridge

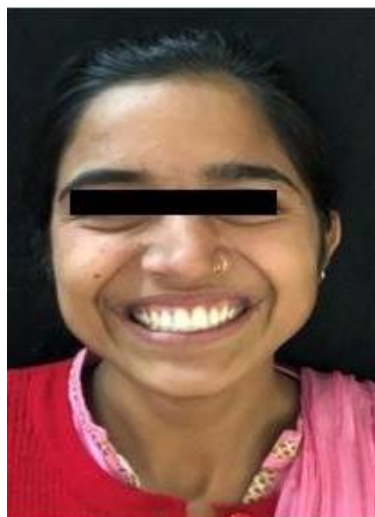

Fig. 4: Post-operative extra oral photograph

Discussion

The replacement of missing tooth could be performed using various therapeutic options. FRC bridges are one of these options, with several advantages including bonding, repairable property, fabrication technique, and cost effective & labor intensive.¹¹ This procedure involves minimum tooth preparation. The indirect technique in comparison with direct technique reduces chair side time and provides better results. The direct Technique is time consuming and imprecise. The finishing and polishing is not easy in direct technique and achieving these procedures with clean dry field becomes very difficult. FRC bridge compared to metal Maryland bridge is more esthetic and shows natural appearance.

The anatomical layering technique is used to build up the intermediate tooth in which different dentin and enamel composites are used. This technique provides natural opalescence and translucency. The denture tooth can be used in place of direct fabrication of the missing teeth. This method is faster and more esthetically acceptable.^{12,13}

The FRC must have improved mechanical properties so that risk of clinical failure is reduced. The fracture strength of FRC depends on the elastic modulus of substructure, the preparation design, occlusal load of the span, the manufacturing process and the materials used for fabrication of prosthesis.¹⁴

Emphasis is made on mechanical and biological properties in choosing the preparation design when the teeth are intact, the proximal box must be deep so that an adequate amount of bulk of resin present which provides more strength. And also, the margins should be placed in the enamel only for better marginal adaptation.¹⁵ The manufacturing process also influence the mechanical properties of the FPD.

Conclusion

Replacement of missing tooth with FRC technique can be considered as an innovative treatment modality. Fibre Reinforced technique provides prosthesis which are cost effective, restoring esthetic and function, implant temporization, congenitally missing tooth. It is comfortable, non-irritating, and oral hygiene can be easily maintained. It requires only minimum tooth reduction. It can be easily modified and repaired. It can be considered as a long-lasting and economical provisional treatment. Non-invasive or minimum preparation of this treatment leads it superior to all other options.

Conflict of Interest: None.

References

1. Vallittu PK. Survival rates of resin-bonded, glass fiber-reinforced composite fixed partial dentures with a mean follow-up of 42 months: A pilot study. *J Prosthet Dent* 2004;3:241-6.
2. Nixon RL, Weinstock A. An immediate-extraction anterior single-tooth replacement utilizing a fiber-reinforced dual-component bridge. *Pract Periodontics Aesthet Dent* 1998;10:17-26.

3. Belli S, Ozer F. A simple method for single anterior tooth replacement. *J Adhes Dent* 2000;2:67-70.
4. Feinman RA, Smidt A. A combination porcelain/fiber-reinforced composite bridge: A case report. *Pract Periodontics Aesthet Dent* 1997;9:925-9.
5. Miller MB. Aesthetic anterior reconstruction using a combined periodontal/restorative approach. *Pract Periodontics Aesthet Dent* 1993;5:33-40.
6. van Wijlen P. A modified technique for direct, fiber-reinforced, resin-bonded bridges: Clinical case reports. *J Can Dent Assoc* 2000;66:367-71.
7. Vanini L. Light and color in anterior composite restorations. *Pract Periodontics Aesthet Dent* 1996;8:673-82.
8. Rudo DN, Karbhari VM. Physical behaviors of fiber reinforcement as applied to tooth stabilization. *Dent Clin North Am* 1999;43:7-35.
9. Pfeiffer P, Grube L. In vitro resistance of reinforced interim fixed partial dentures. *J Prosthet Dent* 2003;89:170-4.
10. Fahl N Jr. Restoration of the maxillary arch utilizing a composite resin buildup and a fiber framework. *Pract Periodontics Aesthet Dent* 1998;10:363-7.
11. Tezvergil A, Lassila LV, Vallittu PK. The effect of fiber orientation on the thermal expansion coefficients of fiber-reinforced composites. *Dent Mater* 2003;19:471-7.
12. Kanie T, Fujii K, Arikawa H, Inoue K. Flexural properties and impact strength of denture base polymer reinforced with woven glass fibers. *Dent Mater* 2000;16:150-8.
13. Behr M, Rosentritt M, Lang R, Handel G. Flexural properties of fiber reinforced composite using a vacuum/pressure or a manual adaptation manufacturing process. *J Dent* 2000;28:509-14.
14. Kelly JR. Perspectives on strength. *Dent Mater* 1995;11:103-110.
15. Song HY, Yi YJ, Cho LR, Park DY. Effects of two preparation designs and pontic distance on bending and fracture strength of fiber-reinforced composite inlay fixed partial dentures. *J Prosthet Dent* 2003;90(4):347-53.

How to cite the article: Varshney KK, Bhatia V, Khurana PRS. Esthetic rehabilitation of anterior teeth by fiber-reinforced composite: A case report. *J Dent Specialities* 2019;7(1):42-4.