

## Oral melanoacanthoma: Case report with review of literature

Nivedita<sup>1\*</sup>, Swati Sharma<sup>2</sup>, Mohit Sharma<sup>3</sup>, Monica Mehendiratta<sup>4</sup>

<sup>1,2</sup>M.D.S Student, <sup>3,4</sup>Reader, Dept. of Oral and Maxillofacial Pathology, I.T.S. Dental College, Hospital and Research Centre, Greater Noida, Uttar Pradesh, India

**\*Corresponding Author:**

Email: nivedita.chaudhary@gmail.com

### Abstract

Oral melanoacanthoma is a rare, benign pigmented lesion that presents most commonly on the buccal mucosa. It is characterized clinically by the sudden appearance and rapid growth of a macular brown-black lesion and histologically by hyperplasia of spinous keratinocytes and dendritic melanocytes. We report a case of oral melanoacanthoma in a 37-year-old Indian male, who presented with an intra-oral brown macular lesion on the right buccal mucosa with a duration of ten days. Microscopic examination revealed acanthosis of stratified squamous surface epithelium with dendritic melanocytes in the basal and suprabasal layers and presence of melanophages in the underlying connective tissue. Based on the history, clinical features and histological presentation, the lesion was diagnosed as oral melanoacanthoma.

**Keywords:** Melanocytes, Melanoacanthoma, Dendritic.

### Introduction

Melanoacanthoma (melano-acanthosis) is a rare mucocutaneous lesion. It is a benign, pigmented lesion affecting the skin and the mucous membranes. The histologic characterization of this entity is done by the presence of dendritic melanocytes which are seen spreading throughout the acanthotic as well as spongiotic epithelium, in contrast to their presence in the basal layer of the normal epithelium. This lesion was initially defined as a benign tumour of the keratinocytes and melanocytes of skin, but as of now it is well known that the lesions occurring within the oral cavity are strikingly different from those reported on the skin.<sup>1</sup>

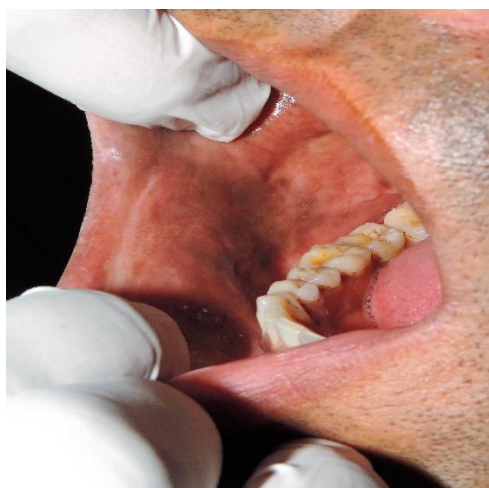
Melanoacanthoma of the skin (Cutaneous melanoacanthoma) was first described by Bloch in the year 1927. The term was later put forward by Mishima and Pinkus (1960).<sup>2</sup> The first ever documented case of melanoacanthoma in the oral cavity was reported in the year 1978 by Tomich.<sup>3</sup>

Cutaneous Melanoacanthoma is considered as a variety/type of seborrheic keratosis. Most patients of this condition are adults, above the age of 40 years.<sup>4</sup> These are located mostly on the trunk, although lesions have also been diagnosed on the scalp, neck and extremities with some frequency. These lesions are almost seen exclusively in the whites in middle to late age groups and develop slowly over an extended period.<sup>4,5</sup>

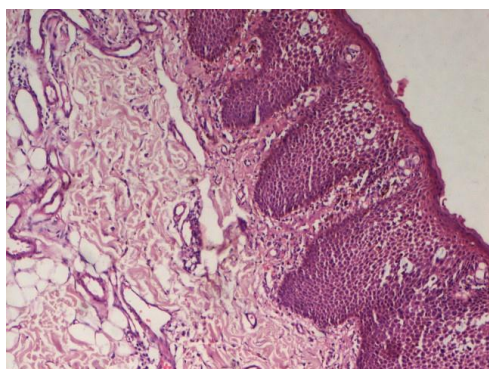
On the contrary, intraoral melanoacanthosis affects a much younger population and mostly encountered in blacks. These lesions exhibit a female predilection. The buccal mucosa is the most common site of occurrence of oral melanoacanthomas. The lesion can be smooth, completely flat or it may be slightly raised, and dark-brown through black to intensely dark black in colour. Lesions often show a fast increment in their size, and in many instances, are seen to attain a maximum diameter of several centimetres in a short time frame of a few weeks.<sup>6</sup> The lesions are mostly seen as unilateral and solitary pigmentations.<sup>7</sup> In the following case-report we present a case of focal oral pigmentation in a 37-year-old male, which was diagnosed as oral melanoacanthoma.

### Case Report

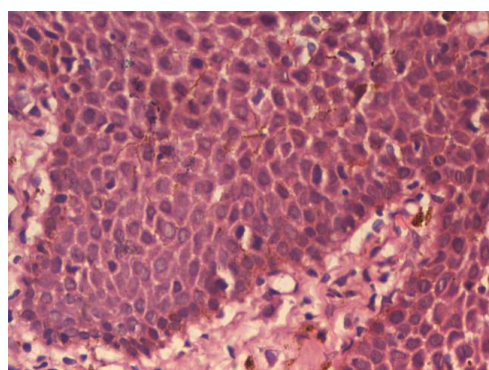
A 37-year-old Indian male presented to the Oral Medicine, Diagnosis and Radiology Department with the chief complaint of change in colour and texture of the right buccal mucosa. It was reported by the patient that the duration of the pigmentation was around ten days. The patient initially noticed a small area of pigmentation/alterd colour of right buccal mucosa which, to his concern, had rapidly increased to the present size (Fig 1). Upon inspection it was seen that the lesion was brownish to black in colour. It was a macular lesion and present with respect to the right buccal mucosa. It was well demarcated from the surrounding normal oral mucosa. The lesion extended anteriorly from the region of the right mandibular canine (43) to the first molar of the same quadrant (46). It measured 15 mm antero-posteriorly and 20 mm supero-inferiorly. The patient did not report any discomfort/pain associated with the lesion, except for an altered texture of the mucosa in the affected area. Personal history, as provided by the patient revealed that he was not taking any medication and had no deleterious habits. An incisional biopsy was performed in the Department of Oral Medicine, Diagnosis and Radiology and the specimen was sent for histopathological evaluation to the Department of Oral and Maxillofacial Pathology. The H&E stained sections of the specimen revealed parakeratinized stratified squamous epithelium exhibiting acanthosis of the spinous layer with intraepithelial dendritic melanocytes evident within the basal and suprabasal layers (Fig 2). The underlying connective tissue was loose with mild amount of chronic inflammatory cell infiltrate (chiefly lymphocytes) and also showing some evidence of melanophagic activity in the subepithelial zone. Melanin incontinence was also appreciable in the connective tissue (Fig 3). Considering the history given by the patient, clinical features noted upon examination and the histopathological picture of the lesion, the final diagnosis of oral melanoacanthoma was achieved.



**Fig. 1: Black-brown pigmentation involving the right buccal mucosa**



**Fig. 2: Marked acanthosis of epithelium with dendritic melanocytes throughout the epithelium**



**Fig. 3: Melanin incontinence and melanophages in the subepithelial connective tissue**

### Discussion

Oral melanoacanthoma/melanoacanthosis is a benign condition and believed to be a reactive process. This fact is reinforced by the evidence provided by the clinical course of the lesion. The age of presentation of oral melanoacanthoma ranges from 9 to 77 years, with a reported mean age of occurrence of 29 years.<sup>1,8</sup> The lesion is largely observed among blacks, though few occurrences have been seen in the Caucasian, Hispanic and Asian populations.<sup>8</sup> Oral melanoacanthomas exhibits a female preponderance, with a reported male to female ratio of 1:2.<sup>8</sup> The main etiologic factor elicited is local irritation. The site most commonly seen to be affected is the buccal mucosa. The mucous membrane of the lip, palate, gingiva and the

alveolar mucosa are other sites of occurrence of this lesion.<sup>8</sup>

The clinical picture of this lesion is identical to many other pigmented lesions of the oral cavity. All pigmented lesions of oral cavity should be assessed for development regarding their size, colour, surface, shape texture and symptoms overtime.<sup>6</sup> The alarmingly fast growth rate of this lesion in the oral cavity makes it clinically indistinguishable from the oral malignant melanoma (malignant neoplasm of the melanocytes). Hence, biopsy should be always performed without fail in such cases to rule out the possibility of the lesion being malignant melanoma. Once the final diagnosis has been made, no other treatment is needed further for oral melanoacanthoma cases. Many cases have documented spontaneous regression.<sup>1,9</sup> The other differentials of melanoacanthoma include smoker's melanosis, drug induced pigmentation, post-inflammatory melanosis, Addison's disease, pigmented nevi, melanotic macule and Spitz nevus.<sup>9</sup>

Melanoacanthoma is regarded as a reparative lesion and has no reported malignant potential. The treatment of the lesion/condition should be aimed in the direction of removing the local cause of trauma or irritation and excluding any other causes which can lead to the pigmentation, particularly malignant melanoma.<sup>9</sup>

### References

1. Rohilla K, Ramesh V, Balamurali P, Singh N. Oral melanoacanthoma of a rare intraoral site: case report and review of literature. *Int J Clin Pediatr Dent* 2013;6(1):40–3.
2. Chandler K, Chaudhry Z, Kumar N, Barrett AW, Porter SR. Melanoacanthoma: A rare cause of oral pigmentation. *Oral Surg Oral Med Oral Pathol Oral Radiol Endod* 1997;84(5):492–4.
3. Tomich CE. Oral presentation. Paper presented at: 32nd Annual Meeting of the American Academy of Oral Pathology 1978:23–8.
4. LeBoit PE, Burg G, Weedon D, Sarasin A, editors. *Pathology and genetics of skin tumours (IARC WHO Classification of tumours)*. Oxford: Oxford University Press;2009. p. 355.
5. Tomich C, Zunt S. Melanoacanthosis (melanoacanthoma) of the oral mucosa. *J Dermatol Surg Oncol* 1990;16(3):231–6.
6. Neville BW, Damm DD, Allen CM, Bouquot J. *Oral and maxillofacial pathology*. 3rd ed. Philadelphia: WB Saunders Company; 2009. p. 984 p.
7. Landwehr DJ, Halkias LE, Allen CM. A rapidly growing pigmented plaque. *Oral Surg Oral Med Oral Pathol Oral Radiol Endod* 1997;84(4):332–4.
8. Lakshminarayanan V, Ranganathan K. Oral melanoacanthoma: a case report and review of the literature. *J Med Case Rep* 2009;13;3:11.
9. Carlos-Bregni R, Contreras E, Netto AC, Mosqueda-Taylor A, Vargas PA, Jorge J et al. Oral melanoacanthoma and oral melanotic macule: A report of 8 cases, review of the literature, and immunohistochemical analysis. *Med Oral Patol Oral Cir Bucal* 2007;12(5):E374–9.