

## Natal teeth retained for 3 years: A rare case report

Nidhi Agarwal<sup>1</sup>, Manpreet Kour<sup>2\*</sup>, Ashish Anand<sup>3</sup>

<sup>1</sup>Professor & HOD, <sup>2</sup>PG Student, <sup>3</sup>Senior Lecturer, Dept. of Pedodontics & Preventive Dentistry, Institute of Dental Studies & Technologies, Ghaziabad, Uttar Pradesh, India

**\*Corresponding Author:**

Email: mkaur0240@gmail.com

### Abstract

Teeth present at the time of birth are termed as natal teeth and most of them represent the early eruption of normal primary teeth. Its occurrence is a rare condition and when present can be associated with numerous clinical complications. Due to this, majority of natal teeth are prematurely lost or extracted and the presence of retained natal teeth is uncommon. The purpose of this case report is to document a rare case of retained natal teeth in a 3 year old child and to highlight the importance of the periodic examination program in such cases.

**Keywords:** Natal teeth, Child, Hypoplastic Enamel.

### Introduction

In 1950, Massler and Savara introduced the commonly used term “natal teeth” for teeth present at birth<sup>(1)</sup> also known as congenital teeth, fetal teeth, predeciduous teeth, premature teeth, or dentitia praecox.<sup>(2)</sup> The incidence of natal teeth has been studied extensively which ranges from 1:2000-1:3,500 live births.<sup>(3)</sup> The etiology of natal teeth is unknown but several conditions such as infection or malnutrition, trauma, hypovitaminosis, febrile states, hormonal stimulation and maternal exposure to environmental toxins have been implicated as causative factors.<sup>(4,5)</sup> However, the current concept proposed that, these teeth are attributed to a superficial position of the developing tooth germ, which predisposes the tooth to erupt early.<sup>(4,5)</sup> The majority of the natal teeth represent the early eruption of the normal primary dentition while less than 10% are supernumerary.<sup>(6-8)</sup> Morphologically, it might resemble normal primary dentition in size and shape; though the teeth are often smaller, conical and yellowish, and have hypoplastic enamel and dentin with poor or absent root formation.<sup>(2,8)</sup>

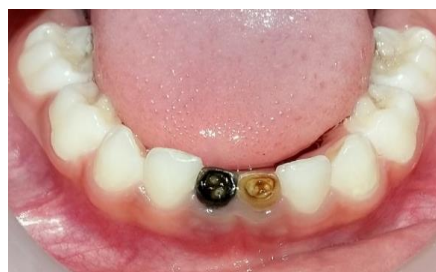The presence of natal teeth can be associated with numerous clinical complications, the most common being the discomfort during suckling, laceration of the mother’s breasts, sublingual laceration (Riga-Fede disease) with resultant feeding refusal, mobility and aspiration of the natal teeth.<sup>(6,7)</sup> Due to these complications majority of the natal teeth are being prematurely lost or extracted and as a result the documentation regarding retained natal teeth is rarely reported in dental literature. With this preview, a description of a rare case of retained natal teeth present in the mandibular anterior region of a 3 year old child is reported.

### Case Report

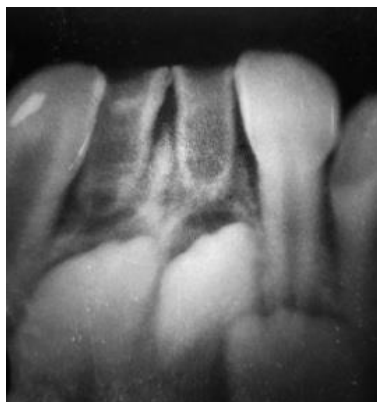
A 3-year old healthy male patient was brought to the outpatient Department of Pedodontics by his parents with the chief complaint of black discoloration of his two lower front teeth. The parents reported that both the

teeth were present at the time of birth of the child and since then no further eruption of any new teeth occurred in the central incisor region of the mandibular arch. The parents revealed that the child was born to normal full term pregnancy and was physically normal at the time of birth. The teeth present at the time of birth were associated with no complications, so the parents never consulted a dentist at that time.

The intra oral examination revealed the presence of fully erupted teeth with brownish and blackish discoloration corresponding to position of teeth 71 and 81 (Fig. 1). The teeth were smaller in overall dimension than the corresponding primary teeth with the presence of hypocalcified and hypoplastic enamel that were firmly attached to the alveolus exhibiting no mobility. Moreover, all the other primary teeth showed normal color, appearance and eruption pattern. The radiographic examination revealed the erupted teeth were 71 and 81, the mandibular primary central incisors. These teeth showed thin shell of hypoplastic enamel and dentin with poorly outlined short roots giving a ghost-like appearance. The pulp chambers were large with the wide root canals as the hypoplastic dentin was thin and seemed to be just serving the outline of the image of the root (Fig. 2). Based on the clinical and radiographic findings, a diagnosis of retained natal teeth was made.



**Fig. 1:** Intra oral examination showing presence of fully erupted teeth with brownish and blackish discoloration corresponding to position of teeth 71 and 81



**Fig. 2: Radiographic image showing large pulp chambers with wide root canals in relation to 71 and 81**

The importance of these teeth in the growth of the child was explained to the parents after the fluoride application and reinforcement of the oral hygiene and home care measures. A regular 6 month periodic recall visit was established.

### Discussion

The term natal and neonatal teeth simply represent the time of eruption and not the anatomical, morphological and structural characteristics of these teeth. Spouge and Feasby classified these teeth on the basis of clinical characteristics as “mature” teeth which are almost fully developed with moderately good prognosis, and “immature” which are incompletely formed with a poor prognosis.<sup>(9)</sup> Hebling also classified natal teeth into 4 clinical categories: shell shaped crown poorly fixed to the alveolus by gingival tissue and absence of a root; solid crown poorly fixed to alveolus by gingival tissue and little or no root; eruption of the incisal margin of the crown through gingival tissue and edema of gingival tissue with an unerupted but palpable tooth.<sup>(10)</sup> As per these classifications described above the present case was of immature teeth with shell shaped crown and little root which were firmly fixed to the alveolus by the gingival tissue. However in the present case, these retained teeth presented with very little development of the root still, the teeth were firmly fixated to the underlying alveolus by the gingival tissue. This clinical presentation has never been reported in the dental literature.

The presence of natal and neonatal teeth may be a source of uncertainty about the treatment plan. In the decision of maintenance or removal of these teeth in the oral cavity, there is an agreement in clinical studies that these teeth should be retained because they are most commonly the teeth of normal dentition.<sup>(6,10)</sup> As a result, it is strongly recommended that natal and neonatal teeth should be left in place, if possible, and be removed only if extremely mobile. The preservation of these teeth of the normal dentition is imperative, since

the premature loss of a primary tooth may cause loss of space and collapse of the developing mandibular arch resulting in malocclusion of permanent dentition.<sup>(6)</sup> In the present case the natal teeth was of normal primary dentition and represented the true normal eruption with no clinical complications, therefore it was decided to periodic follow up the case till the eruption of permanent mandibular incisors.

This case report emphasizes that the periodic examination program in the children with the retained natal teeth should be carried out in order to observe the mobility, shape, color and any associated clinical complications. Moreover, longitudinal studies in order to determine the cause and effect of survival of natal and neonatal teeth should be planned in future.

### References

1. Massler M, Savara BS. Natal and neonatal teeth: a review of 24 cases reported in the literature. *J Pediatr* 1950; 36: 349-59.
2. Zhu J, King D. Natal and neonatal teeth. *J Dent Child* 1995; 62:123-8.
3. Chow MH. Natal and Neonatal teeth. *J Am Dent Assoc* 1980; 100: 215-6.
4. Cunha RF, Boer FAC, Torriani DD, Frossard WT, Natal and neonatal teeth: review of the literature. *Pediatr Dent* 2001;23:158-62.
5. Gladen BC, Taylor JS, Wu YC. Dermatological findings in children exposed transplacentally to heat-degraded polychlorinated biphenyls in Taiwan. *Br J Dermatol* 1990; 122: 799-808.
6. Leung AK. Natal teeth. *Am J Dis Child* 1986;140:249-51.
7. Buchanan S, Jenkins CR. Riga-Fedes syndrome: natal or neonatal teeth associated with tongue ulceration. Case report. *Aust Dent J* 1997;42:225-7.
8. Galassi MS, Santos-Pinto L, Ramalho LT. Natal maxillary primary molars: case report. *J Clin Pediatr Dent* 2004; 29(1): 41-4.
9. Spouge JD, Feasby WH. Erupted teeth in the newborn. *Oral Surg Oral Med Oral Pathol* 1966; 22: 198-208.
10. Hebling J, Zuanon ACC, Vianna DR. Dente Natal—A case of natal teeth. *Odontol Clín* 1997; 7: 37-40.