

Phenytoin – induced gingival overgrowth: a case report

Reetika Gaddale^{1*}, Shrikar R. Desai², Ilangovan Karthikeyan³, Sangeeta S. Kulkarni⁴

¹Reader, Dept. of Periodontics & Oral Implantology, AME's Dental College & Hospital, Raichur, Karnataka, ²Professor, Dept. of Periodontics, H.K.E. Society's S. Nijalingappa Institute of Dental Sciences & Research, Gulbarga, Karnataka, ³Senior Lecturer, Dept. of Periodontics, Indira Gandhi Institute of Dental Sciences, Pondicherry, Tamil Nadu, ⁴Reader, Dept. of Conservative Dentistry & Endodontics, Al-Badar Rural Dental College & Hospital, Gulbarga, Karnataka, India

***Corresponding Author:**

Email: reetikag_25@yahoo.co.in

Abstract

Drug-induced gingival overgrowth (DIGO) is a common clinical finding which can be treated either by nonsurgical and/or surgical techniques which will reduce the rate of recurrence. Wherever possible the required management strategy should be adopted as per the case. This case report describes the management of a patient with phenytoin-induced gingival overgrowth by both non-surgical and surgical approaches.

Keywords: Drug-induced gingival overgrowth, Phenytoin-induced gingival overgrowth, Gingival enlargement, Gingivectomy.

Introduction

“Gingival enlargement” or “gingival overgrowth” is the preferred term for all medication-related gingival lesions previously termed “gingival hyperplasia” or “gingival hypertrophy.” These earlier terms did not accurately reflect the histologic composition of the pharmacologically modified gingiva.⁽¹⁾

Phenytoin, nifedipine and cyclosporine, are well-known iatrogenic causes of gingival enlargement.^(2,3) Of the above drugs, phenytoin is the most studied, its association with gingival enlargement dating back to 1939.⁽⁴⁾

The prevalence of DIGO varies between drugs though clinically and histologically, DIGO are virtually indistinguishable,^(5,6) with approximately 50% of patients medicated with phenytoin experiencing significant gingival changes,⁽⁷⁾ whilst the figures for cyclosporin and nifedipine are closer to 30% and 20% respectively.⁽⁸⁾ The risk factors identified in the expression of DIGO are age and other demographic factors; drug variables; concomitant medication; periodontal variables and genetic factors.⁽⁵⁾ Severe forms of DIGO leads to disfiguring and interference with speech and mastication.

DIGO appears to be more prevalent in children and adolescents and has a predilection for the anterior gingival tissues. Gingival changes can occur within 3 months of dosage.⁽⁹⁾ The pattern of overgrowth development shows intra-patient variation, but may reach a "state of equilibrium" often within the first year of commencing medication. Changes in drug therapy, or systemic illness may alter this state and lead to further gingival changes.⁽¹⁰⁾

The relationship between the various drugs and gingival tissue components is influenced by several risk factors. DIGO has high recurrence rate due to chronic usage of the listed medications and other risk factors.⁽¹¹⁾ This is a case report of the management of a patient

with phenytoin-induced gingival overgrowth by both non-surgical and surgical approaches.

Case Report

A 20-years old female patient reported to a private clinic, with a chief complaint of swollen gums since 4 years. Patient gave history of epilepsy, which was diagnosed at the age of 14 years and she was on medication, phenytoin 100mg bid since then. Patient first noticed changes in the gingiva after 2 years of starting of medication but ignored it. When the gingival overgrowth exceeded to the extent that she developed pain, bleeding and abscess along with difficulty in mastication, she visited the clinic for treatment.

Extra-oral examination showed facial disfigurement with incompetent lips displaying swollen gums (Fig. 1). Intraoral examination showed gingival overgrowth covering more than two-third of the tooth surface in the anterior teeth and till the occlusal surface of the posterior teeth (Fig. 2).

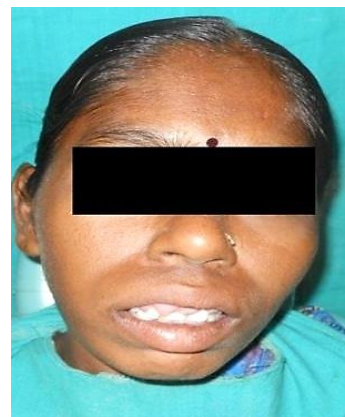

Fig. 1: Facial disfigurement due to phenytoin-induced gingival overgrowth

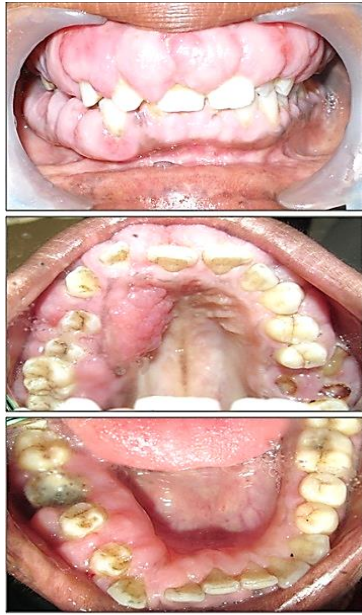

Fig. 2: Intraoral view

The gingival overgrowth showed pebbled surface with some areas having firm and leathery consistency while the other areas having soft and oedematous consistency as a result of secondary inflammatory changes due to the presence of abundant local factors with spontaneous bleeding on probing. Generalized periodontal pockets were present with generalized mobility of teeth. Deep carious lesions were present in relation to 26 and 46. Radiographic examination showed generalized bone loss, case was diagnosed as generalized chronic periodontitis with combined (phenytoin – induced and inflammatory) gingival overgrowth.

Patient was referred to the physician for the possible change of antiepileptic drugs. Patient reported after 2 days and the physician changed the medication to Carbamazepine 200mg bid. Scaling was done followed by the extraction of 26 and 46. Patient was asked to report after 2 months.

Following 2 months, moderate reduction in the gingival overgrowth was noticed in maxillary anterior region, but patient was not maintaining the oral hygiene (Fig. 3). Scaling and root planing was performed and oral hygiene instructions were reinforced and patient was motivated to perform good oral hygiene and was asked to report after 2 months.

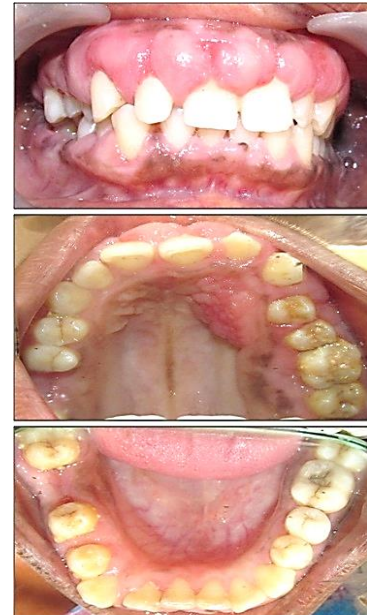

Fig. 3: Two months after the change of drug and non-surgical periodontal therapy

During patient's subsequent visit, significant reduction in gingival overgrowth was noticed in maxillary posterior and mandibular teeth. Some amount of gingival overgrowth was still present in the maxillary anterior sextant, for which flap surgery was planned (Fig. 4).

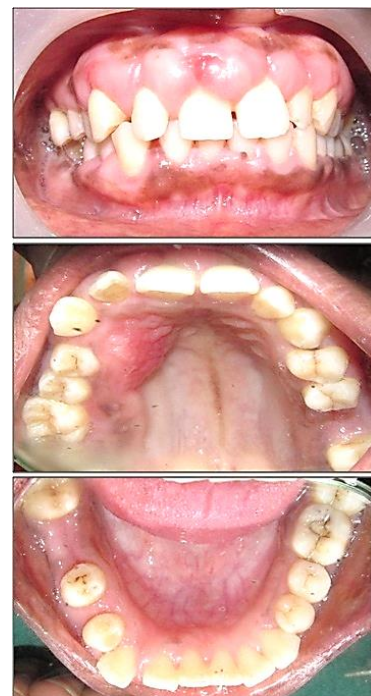

Fig. 4: Four months after change of drugs and SRP

Pockets were marked with a pocket marker after anesthetizing the area (Fig. 5a). With a 15 no BP blade, an internal bevel incision and intra-crevicular incisions

were made from 13 to 23 (Fig. 5b) followed by flap elevation, after which an inter-dental incision was given to remove the excess tissue. The area was debrided, root planing was done (Fig. 5c) and sutures were placed after approximation of the flaps (Fig. 5d). Post-operative instructions were given, antibiotics and analgesics were prescribed and patient was recalled after 1 week for suture removal.

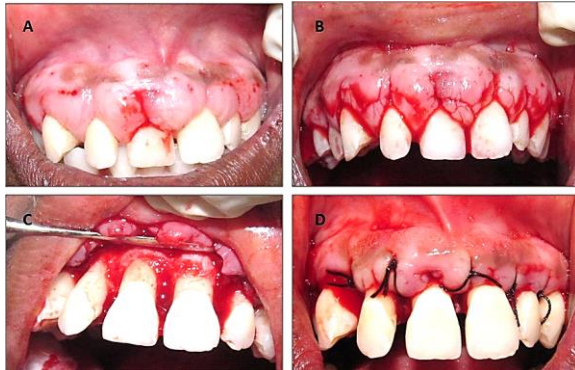

Fig. 5: (a) Pockets marked with a pocket marker (b) Internal bevel and intracrevicular incisions given (c) After removal of excess tissue and debridement (d) Sutures placed

Histopathological report revealed hyperplasia of epithelial and connective tissue cells along with the proliferation of blood vessels. Inflammatory cells were seen in the connective tissue. (Fig. 6).

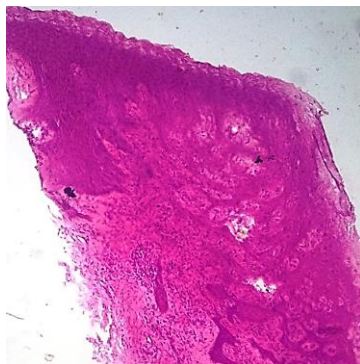


Fig. 6: Histopathological image (H & E staining)

Satisfactory healing was seen one-week post-operative. Significant reduction in gingival overgrowth was seen one-month post-operative with reappearance of the gingival pigmentation (Fig. 7).

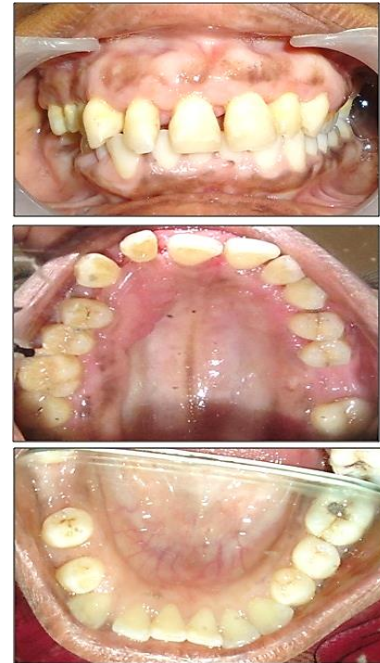

Fig. 7: One – month post-operative

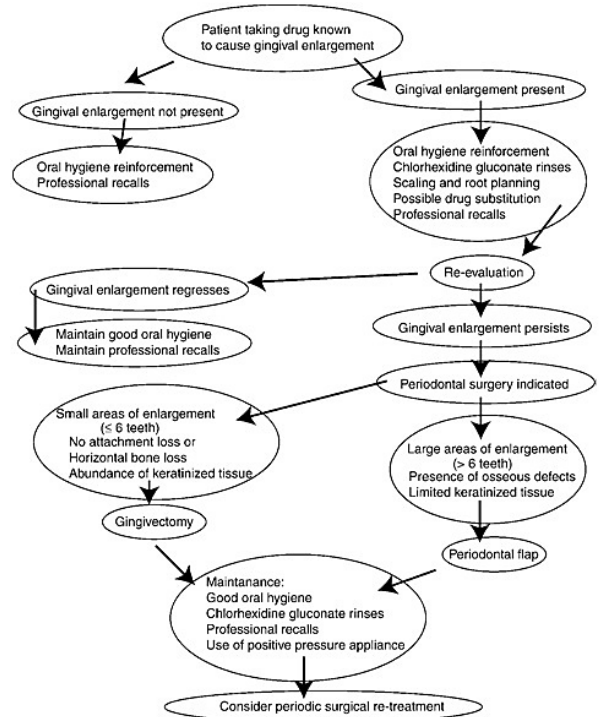


Fig. 8: Treatment of drug-induced gingival overgrowth

Discussion

Phenytoin is a hydantoin, 5,5-diphenylhydantoin, which abolishes post-tetanic hyperpolarization and reduces post-tetanic potentiation of synaptic transmission. This results in a stabilization of excitable membranes and reduces the spread of electrical discharge from an active epileptogenic focus.⁽¹²⁾

A discontinuation of phenytoin should not be recommended simply on the basis of moderate to severe hyperplasia. Conservative periodontal measures include vigorous gingival massage coupled with efficient toothbrushing and gum stimulators.⁽¹³⁾ When surgical measures are indicated, the drug treatment plan of the physician managing the epilepsy should be discussed and the date of surgery postponed if the physician is planning to discontinue the phenytoin.

Neurologic indications for discontinuing phenytoin include the following:⁽¹²⁾

1. Discontinuation of all medications in cases in which the individual may have outgrown the seizure disorder.
2. The patient is antagonistic toward phenytoin and another drug is to be tried.
3. The persistence of seizures despite therapeutic drug levels (A more effective drug is to be tried in place of phenytoin).
4. Inadequate drug levels of phenytoin has prompted a drug alternative.
5. The persistence of oral disfigurement despite active periodontal treatment in a patient with problems relating to self image may prompt a drug alternative.

Carbamazepine and valproic acid, the alternative medications to phenytoin, have shown lesser impact in inducing gingival enlargement.⁽¹⁴⁾ Oral folic acid was found to decrease the incidence of gingival overgrowth in children on phenytoin monotherapy, in a statistically significant and clinically relevant manner.⁽¹⁵⁾

Indications of periodontal flap technique to treat gingival enlargement are; gingival enlargement on larger areas (more than six teeth), areas where attachment loss combined with osseous defects is present, areas which will result in the elimination of all keratinized tissue following gingivectomy and end up with mucogingival problems.⁽¹⁶⁾ Fig. 8 summarizes the treatment of drug induced gingival overgrowth.

Drug induced gingival overgrowth treated surgically do show recurrence, but this can be decreased by proper home care, chlorhexidine gluconate rinses and professional cleaning. Use of bite guard at night has shown to control recurrence.⁽¹⁷⁾ Post-surgical recurrence rate varies from 3-6 months, but in most cases, the results are well maintained for 12 months.⁽¹⁶⁾

Conclusion

A full periodontal assessment should be done of all patients who are about to be medicated with cyclosporin, phenytoin or a calcium channel blocker and if any periodontal disease is present, it should be treated appropriately. But for many of such patients, this is not possible and often present with gingival overgrowth. For most of the patients, surgical approach is the treatment of choice, but prevention of recurrence

is the biggest challenge to the periodontist and the dental team.

References

1. Dongari-Bagtzoglou A. Drug-Associated Gingival Enlargement. *J Periodontol* 2004;75:1424-31.
2. Butler RT, Kalkwarf KL, Kaldahl WB. Drug-Induced Gingival Hyperplasia: Phenytoin, Cyclosporin and Nifedipine. *J Am Dent Assoc* 1987;114: 56–60.
3. Botha PJ. Drug-induced gingival hyperplasia and its management. A literature review. *J Dent Assoc S Afr* 1997; 52:659–64.
4. Angelopoulos AP. Diphenylhydantoin gingival hyperplasia. A clinico-pathological review. Incidence, clinical features and histopathology. *J Can Dent Assoc* 1975; 41: 103–6.
5. Angelopoulos AP, Goaz. PW. Incidence of diphenylhydantoin gingival hyperplasia. *Oral Surgery Oral Medicine Oral Pathology* 1972;34: 898-906.
6. Seymour RA, Smith DG, Rogers SR. The comparative effect of azathioprine and cyclosporin on some gingival health parameters of renal transplant patients. *J Clin Periodontol* 1987; 14: 610-3.
7. Seymour RA, Ellis JS, Thomason JM. Risk factors for drug-induced gingival overgrowth. *J Clin Periodontol* 2000; 27: 217–23.
8. Wysocki GP, Gretzinger HA, Laupacis A, Ulan RA, Stiller CR.. Fibrous hyperplasia of the gingiva: A side effect of cyclosporin A therapy. *Oral Surg Oral Med Oral Pathol* 1983;55: 274-8.
9. Seymour RA, Jacobs DJ. Cyclosporin and the gingival tissues. *J Clin Periodontol* 1992;19: 1-11.
10. Seymour RA, Thomason JM, Ellis JS. The pathogenesis of drug-induced gingival overgrowth. *J Clin Periodontol* 1996; 23: 165-75.
11. Mavrogiannis M, Ellis JS, Thomason JM, Seymour RA. The management of drug induced gingival overgrowth. *J Clin Periodontol* 2006; 33: 434-9.
12. Reynolds NC Jr, Kirkham DB. Therapeutic alternatives in phenytoin-induced gingival hyperplasia - a case report and discussion. *J Periodontol* 1980;51: 516-20.
13. Esterberg HL, White PH. Sodium dilantin gingival hyperplasia. *J Am Dent Assoc* 1945; 32:16.
14. Dahllof G, Preber H, Eliasson S, Ryden H, Karsten J, Modeer T. Periodontal condition of epileptic adults treated with phenytoin or carbamazepine. *Epilepsia* 1993;34: 960–4.
15. Arya R, Gulati S, Kabra M, Sahu JK, Kalra V. Folic acid supplementation prevents phenytoin-induced gingival overgrowth in children. *Neurology* 2011;76:1338-43.
16. Camargo PM, Melnick PR, Pirihi FQ, Lagos R, Takei HH. Treatment of drug-induced gingival enlargement: aesthetic and functional considerations. *Periodontol* 2000. 2001; 27: 131-8.
17. Babcock JR. The successful use of a new therapy for dilantin gingival hyperplasia. *Periodontics* 1965; 3:196-9.