

Orthopantomogram study of mental foramen in Muradnagar-Ghaziabad Population

Mohit Mangla^{1*}, Lily Rajput², Amit Kumar³, Pradeep Sharma⁴, Vidhi C. Rathi⁵, Sanjeev Kumar⁶

^{1,2,3}PG Student, ^{4,5}Senior Lecturer, ⁶Professor & HOD, Dept. of Oral & Maxillofacial Surgery, I.T.S Centre for Dental Studies and Research, Ghaziabad, Uttar Pradesh, India

***Corresponding Author:**

Email: drmohitmangla@gmail.com

Abstract

Introduction: Mental foramen is a minute circular/oval shaped opening present bilaterally in the anterior surface of the body of the mandible. The mental foramen marks the termination of mandibular canal in the mandible, through which the inferior alveolar neurovascular bundle passes. Evaluation of the position of the mental foramen in various surgical procedures like fracture of body of mandible, nerve lateralization procedure, dental implant, orthognathic surgery etc. helps in preventing damage to neurovascular bundle thus preventing paresthesia of lower lip, gums and lower anterior teeth. The aim of this study was to determine the position of the mental foramen in the Muradnagar-Ghaziabad population using digital panoramic radiographs in order to keep a record of the variations of the morphologic features of the mental foramen in anethnic population of Muradnagar.

Materials and Method: A total of 1000 digital orthopantomogram of 635 male and 365 female patients within the age group of 15 to 55years were collected and the position of mental foramen along the vertical and horizontal axis was analyzed.

Results: The most common position of mental foramen was found to be in line with second premolar tooth (51%), in the horizontal axis and along the vertical axis, it was inferior to the apex of second premolar (68.1%).

Conclusion: This Study supports the earlier literature regarding the position of mental foramen among north Indian population and suggests that variations are present between populations of different geographical areas.

Keywords: Mental foramen, Orthopantomogram, Muradnagar-Ghaziabad Population.

Introduction

Mental foramen is a small round/oval structure present in the body of the mandible and is commonly seen apical to the second mandibular premolar or between the apices of the premolars. It opens in a posterior direction and the mental nerve and vessels supplying sensation to the lower lip and the labial mucosa traverses via the mental foramen.^(1,2) Studying the position and morphological variations of mental foramen is very important because it is a critical and distinctive landmark for localizing the neurovascular bundle passing through it, in order to perform meticulous osteotomies and dental implant placement without causing any neurosensory dysfunction. The most common position of the mental foramen is in line

with the longitudinal axis of the second premolar tooth followed by the location between the first and second premolar tooth.⁽³⁾ In literature, the position of mental foramen is stated to vary with different races and populations, so the present study was undertaken, to determine the position of mental foramen among the population of Muradnagar city of Ghaziabad.

Materials and Method

Total of 1000 digital panoramic radiographs of 635 male and 365 female patients within the age group of 15-55 years who were advised for radiographs for various purposes were studied and the position of mental foramen was determined on the radiographs.

The radiographs were chosen according to the following criteria given in Table 1:

Table 1: Inclusion and Exclusion Criteria

Inclusion criteria	Exclusion criteria
<ul style="list-style-type: none"> Orthopantomogram in which all mandibular teeth were present upto first molars. OPGs showing all erupted teeth. The films which did not have any radiolucent or radiopaque lesion in the lower jaw and presented no radiographic artifacts. 	<ul style="list-style-type: none"> OPGs in which the lower teeth (between 36 and 46) were missing, presence of an endodontic lesion, root canal treatment or any restorations were left out because of possible associated periapical changes. Radiographs with missing lower canine were excluded. Orthopantomogram of degraded quality with superimposition of structures.

The position (Vertical and Horizontal axis) of the mental foramen was recorded as follows: (Table 2)⁽⁴⁾

Horizontal Axis (H)

H-1: Position depicting the foramen anterior to the first premolar.

H-2: Position depicting the foramen along the line with the first premolar.

H-3: Position depicting the foramen between the premolars.

H-4: Position depicting the foramen along the line with the second premolar.

H-5: Position depicting the foramen between the second premolar and molar.

Vertical Axis (V)

V-1: Position depicting the foramen inferior to the apex of the first premolar.

V-2: Position depicting the foramen inferior to the apex of the second premolar.

V-3: Position depicting the foramen at the level of the apex of the first premolar.

V-4: Position depicting the foramen at the level of the apex of the second premolar.

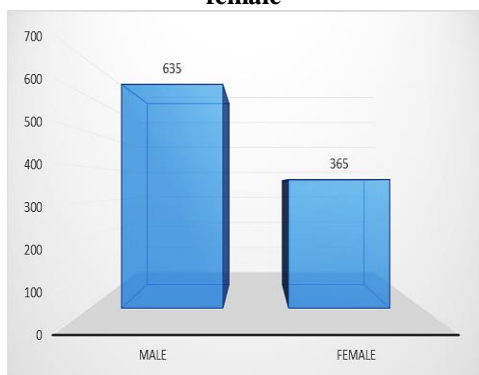
V-5: Position depicting the foramen lying superior to the apex of the first premolar.

V-6: Position depicting the foramen lying superior to the apex of the second premolar

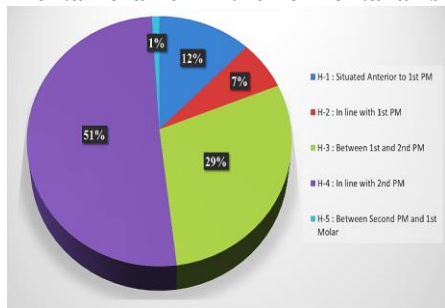
Results

A total of 1000 OPGs were assessed, therefore radiologically 2000 mental foramen were assessed, 1000 on each side i.e., left and right. Mean age for males was 38.73 years and that for females were 34.43. The results are depicted in Graphs 1-3.

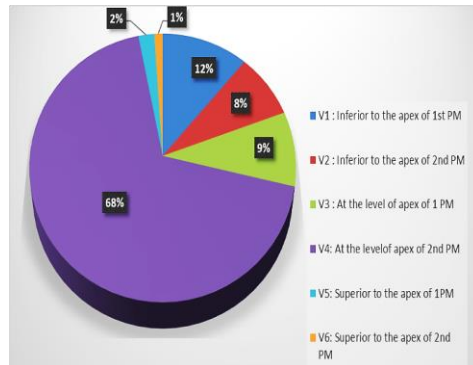
Graph 1: Depicts the total number of male and female



Graph 2: Depicts percentage of the position of the mental foramen in the horizontal axis



Graph 3: Depicts percentage of position of mental foramen in the vertical axis



Discussion

Mandible being the largest and strongest bone of facial region has evolved in morphology in homosapiens from primates through ages. The changes in size and shape of jaws have been studied immensely. The mandible shows extensive variation in its size, weight and location of bony structures during an individual's lifetime. Morphological variations are also seen in mandible among different gender, ethnicities, and races. Out of all the components of the mandible, the identification of mental foramen holds a distinct primacy as an important landmark in numerous maxillofacial surgical procedures.⁽⁵⁾ Mental foramen represents the terminal part of the mandibular canal and the mental nerve and vascular structures pass through it, supplying sensory innervation to the mucosa of lower lip, a vestibular region on the buccal aspect of lower jaw, and the gingival portion of lower jaw, of anterior region.^(6,7) Placement of mandibular endosseous implants, pose a problem in the area of neurovascular bundles leading to certain complications, such as altered sensation, numbness and pain, often due to damage to structures, such as inferior alveolar nerve (IAN) and mental foramen. The damage of related vascular structures can lead to hemorrhage, which can be difficult to control. Damage to these structures is mostly arising from iatrogenic mistakes and sometimes due to failure in identification structures. Identification of mental foramen is also of utmost importance while administering regional anesthesia, performing genioplasties, placing cuts for orthognathic procedures, while performing corticotomies in nerve lateralization and apicotectomy. Therefore, it is critical to determine the location and as well as the morphological configuration of the IAN canal and foramen, in order to minimize the damages.

In the present study, the most common position of mental foramen was found to be in line with second premolar tooth (51%) on the horizontal axis and in the vertical axis, it was found to be inferior to the apex of the second premolar (68.1%). (Table 3)

Table 2: Comparison of position of mental foramen in Horizontal axis with other studies

Authors	Most common Location of Mental foramen in Horizontal Axis
Fishel et al ⁽⁸⁾ (1976)	Was found to be present between two premolars.
Afkhami et al ⁽⁹⁾ (2013)	24% of the cases had foramen located between the premolars.
Gada and Nagda et al ⁽¹⁰⁾ (2014)	63% of the patients had foramen located between the two premolars followed by a position behind the second premolar (20.67%).
Moogala et al ⁽¹¹⁾ (2014)	40–50% of cases had foramen between premolars
Babshet et al ⁽¹²⁾ (2015)	43% in between the two premolars and 39% along the vertical line with the second premolar.
Present Study	Showed that most of the OPGs had foramen in line with Second Premolar

Table 3: Comparison of position of mental foramen in vertical axis with other studies

Authors	Location of Mental foramen in Vertical Axis	% of most common Location of Mental foramen
Wang et al ⁽¹³⁾ (1986)	Present below the apex of 2 nd premolar	58.98%
Santini & Land et al ⁽¹⁴⁾ (1990)	Present below the apex of 2 nd premolar	52.90%
Olasoji et al ⁽¹⁵⁾ (2004)	Present between 1 st and 2 nd premolar	Most common
Apinhasmit et al ⁽¹⁶⁾ (2006)	Present below the apex of 1 st premolar	Most common
Sumit Gupta et al ⁽¹⁸⁾ (2012)	Present below the apex of 2 nd premolar	75.8%
Present study	Present inferior to the apex of the 2 nd premolar.	68.1%

Conclusion

The location of mental foramen, most commonly found in Muradnagar population, was in line with second premolar tooth, along the horizontal axis and in the vertical axis, it was found to be inferior to the apex of the second premolar. The shape of the mental foramen was circular in most of the OPG's and the foramina were observed to be bilaterally symmetrical. Our findings are congruous with earlier data reviewed in literature in different populations among different varied geographic locations. It is discernible from the previous vast literary works, that the location of the mental foramen is indeed differed among different races. Accordingly, our study may add the valuable data regarding mental foramen position among different races and can provide handy inputs to the maxillofacial surgeons and dental practitioners to identify and locate it so as to accomplish uneventful surgical procedures.

References

- Igbigbi PS, Lebona S. The position and dimensions of the mental foramen in adult Malawian mandibles. *West African J of Med* 2005;24:184-9.
- Rowe AHR. In: *Clinical Dentistry*. Blackwell Scientific Publications 1986;3:372-83.
- Mbajjorgu EF, Mawera G, Asala SA, Zivanovic S. Position of the mental foramen in adult black Zimbabwean mandibles: a clinical anatomical study. *Central African J of Med* 1998;44:24-30.
- Ngeow WC, Yuzawati Y. The location of the mental foramen in a selected Malay population. *J Oral Sci* 2003;45:171-5.
- Seema S, Bhavana D, Kamlesh T, Penci CA. Morphometric analysis of mental foramen in human mandibles of Gujarat region. *Int J Sci Res* 2014;3:36-7.
- Green RM. The position of the mental foramen: A comparison between the southern (Hong Kong) Chinese and other ethnic and racial groups. *Oral Surg Oral Med Oral Pathol* 1987;63:287-90.
- Moiseiwitsch JR. The position of the mental foramen in a North American, white population. *Oral Surg Oral Med Oral Pathol Oral Radiol Endo* 1998;85:457-60.
- Fishel D, Buchner A, Hershkowitz A, Kaffe I. Roentgen logic study of the mental foramen. *Oral Surg Oral Med Oral Pathol* 1976;41(5):682-6.
- Afkhami F, Haraji A, Boostani HR. Radiographic localization of the mental foramen and mandibular canal. *J Dent (Tehran)* 2013 Sep;10(5):436-42.
- Gada SK, Nagda SJ. Assessment of position and bilateral symmetry of occurrence of the mental foramen in the dentate Asian population. *J Clin Diagn Res* 2014 Feb;8(2):203-5.
- Moogala S, Sanivarapu S, Boyapati R, Devulapalli NS, Chakrapani S, Kolaparthi L. Anthropometrics of the mental foramen in dry dentate and edentulous mandibles in Coastal Andhra population of Andhra Pradesh State. *J Indian Soc Periodontol* 2014 Jul;18(4):497-502.
- Babshet M, Sandeep R, Burde K, Nandimath K. Evaluation of the position of mental foramen and its correlation with age in the selected Indian population, using digital panoramic radiograph. *Int J Dent Sci Res* 2015;3(4):87-91.
- Wang TM, Shih C, Liu, JC, Kook J. A clinical and anatomical study of the location of the mental foramen in Chinese mandibles. *Acta Anat (Basel)* 1986;126: 29-33.
- Santini A, Land M. A comparison of the position of the mental foramen in Chinese and British mandibles. *Acta Anat (Basel)* 1990;137:208-12.
- Olasoji HO, Tahir A, Ekanem AU, Abubakar AA. Radiographic and anatomic locations of the mental foramen in Nigerian adults. *Niger Postgrad Med J* 2004;11:230-33.
- Apinhasmit W, Methathathip D, Chompoonpong S, Sangvichien S. Mental foramen in Thais: an anatomical

- variation related to gender and side. *Surg Radiol Anat.*, 2006;28:529-33.
17. Gupta S, Soni J. Study of anatomical variations and incidence of mental foramen and accessory mental foramen in dry human mandibles. *Nat J Med Res* 2012;2(1):28-30.