

## Fluid retained denture a relief for flabby ridge: A case report

Deol S<sup>1</sup>, Pathak S<sup>2</sup>, Arora A<sup>3</sup>

### ABSTRACT

<sup>1,2</sup>PG Student, <sup>3</sup>Professor, Dept. of Prosthodontics, I.T.S Dental College, Hospital and Research Centre, Grater Noida

Resorption of alveolar ridges is a dynamic process. It is a continuous process, with varying rates in individual at different times. Due to residual ridge resorption, complete denture prosthesis seldom remains in close adaptation to underlying soft tissues, causing tissue irritation and alteration in underlying mucosa. Denture base have to be flexible to adapt underlying mucosa, and rigid to withstand masticatory forces. Also the incorrect tooth placement and arbitrary shaping of the polished surfaces also questions the success of prosthesis, which can be managed by using neutral zone concept. This case report presents the use neutral zone for atrophic mandibular ridge and fluid retained denture for flabby tissue in anterior maxillary arch.

Received: 02-03-2015  
Accepted: 26-03-2015

**Keywords:** Flabby tissue, Neutral zone, Liquid supported denture

### INTRODUCTION

Resorption of alveolar ridges is a dynamic process. It is a continuous process, with varying rates in individual at different times.<sup>1</sup> Due to residual ridge resorption, complete denture prosthesis seldom remains in close adaptation to underlying soft tissues, causing tissue irritation and alteration in underlying mucosa.<sup>2</sup> Several materials have been introduced including soft liners, tissue conditioners for the application on tissue side of dentures in cases with atrophic alveolar ridges, flabby ridges, and diabetes, since 1961, when Chase introduced the use of elastic impression material to relieve tissue soreness.<sup>3</sup> Denture base have to be flexible to adapt underlying mucosa, and rigid to withstand masticatory forces.<sup>4</sup> Also the incorrect tooth placement and arbitrary shaping of the polished surfaces also questions the success of prosthesis, which can be managed by using neutral zone concept. This case report presents the use neutral zone for atrophic mandibular ridge and fluid retained denture for flabby tissue in anterior maxillary arch.

### CASE REPORT

A 65 year old male patient reported to I.T.S dental college, hospital & research Centre greater Noida. Patient was a complete denture wearer from past 8 years, having chief complaint of poorly fitting dentures. On examination, it revealed flabby tissue in anterior maxillary arch with points of tissue irritation, and atrophic mandibular ridge. Patient was advised to discontinue old dentures and massage the abused tissue with Dologel-CT for 5 days. It was decided to make fluid retained maxillary complete denture, and conventional

mandibular dentures with neutral zone concept to provide good stability.

Primary impression of maxillary arch was made in irreversible hydrocolloid material, for mandibular arch it was obtained by using Mc-Cords technique<sup>5</sup> by mixing 7 parts of green stick compound and 3 parts of impression compound. Special trays were fabricated using full spacer design and border moulding was performed using low fusing green stick compound. Wash impression with zinc oxide eugenol for mandibular arch (Fig.1) and firm mucosa of maxillary arch was made. Flabby area was marked with indelible pencil over the maxillary ridge and it was transferred over special tray, and a window was created after trimming out the marked area (Fig. 2) Flabby tissue was recorded in non-displaced form by painting quick setting impression plaster over it (liddelow technique<sup>6</sup>) (Fig.3). After complete setting impression was removed from mouth and poured with dental stone (type III).

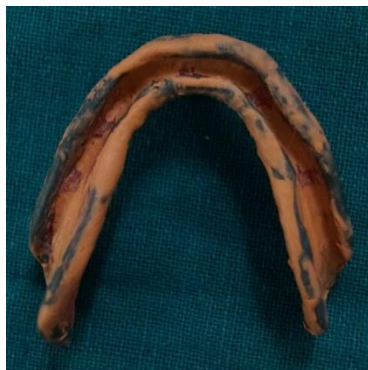Jaw relation was recorded; face bow transfer was done and mounted on semi adjustable articulator (Hanau, Wide View). Impression compound was adapted over the mandibular record base for neutral zone record, this was placed in patient's mouth and patient was instructed to perform various movements such as puckering of lips, whistling, swallowing, smiling (Fig. 4). Neutral zone record obtained was indexed in putty (Fig. 5). Wax was allowed to flow in the index replacing impression compound (Fig. 6). Teeth arrangement was done and tried in patient's mouth. Impression of polished surface for mandibular denture was made by applying light body silicone impression material after removing wax apical to teeth surface (Fig. 7). Patient once again asked to perform similar movements of puckering lips, smiling etc. After obtaining master cast a 1.5mm thick soft and flexible vacuum heat pressed polyethylene sheet was adapted over it 2mm short of sulcus using

#### Address for Correspondence:

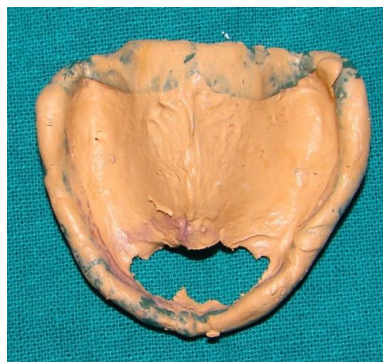Dr. Saloni Deol, PG Student, Dept. of Prosthodontics, I.T.S Dental College, Hospital and Research Centre, Grater Noida, Email: salonideol123@gmail.com

vacuum forming machine (Fig. 8). This sheet will be kept aside to be used as temporary sheet later. Dentures were flaked in conventional manner. Dewaxing was carried out. Mandibular denture was packed heat cured acrylic resin and cured in conventional manner. Petroleum jelly was applied over the adapted temporary sheet and it was placed back on maxillary master cast, followed by packing and curing for maxillary denture. Finishing and polishing was done and dentures were inserted in patient's mouth. (Fig. 9) After 1-2 weeks Silicone impression putty of tissue side of maxillary denture was made and the cast was obtained (Fig. 10). Junction of acrylic and soft

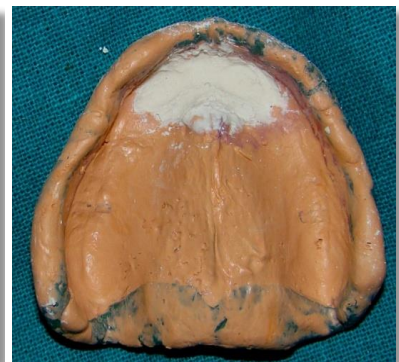sheet was marked on the cast. Another sheet of 0.5mm thickness was adapted over this cast (Fig. 11). Earlier adapted sheet of 1.5mm thickness was carefully separated from denture and latter is adapted to create a space of 1.0mm for liquid. The junction of the sheet and the acrylic was carefully sealed with the help of light cure acrylic. Two holes were made in the distobuccal region on maxillary denture and glycerin was injected through these inlets (Fig. 12). They were closed with light cure acrylic resin. Denture was checked for any sharp points, roughness and leakage. Follow up of patient was done after 24hours to check for any soreness.



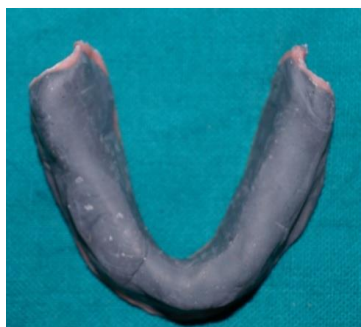**Fig. 1:** Final impression for mandibular arch



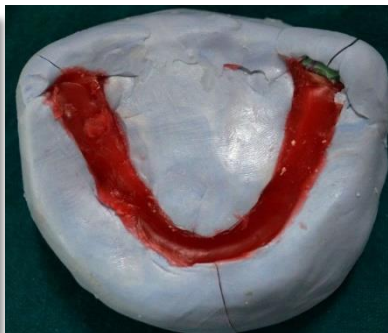**Fig. 2:** Window created for flabby tissue



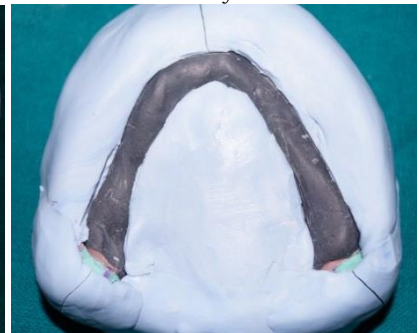
**Fig. 3:** Final impression of maxillary arch



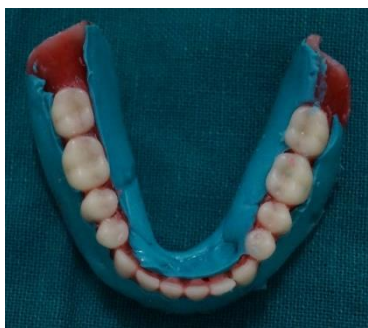**Fig. 4:** Neutral zone record



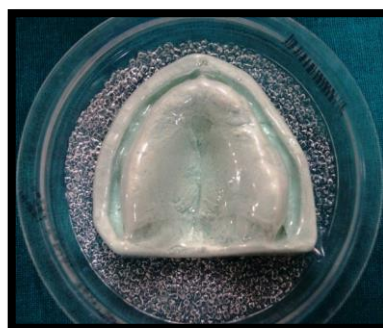**Fig. 5:** Putty index



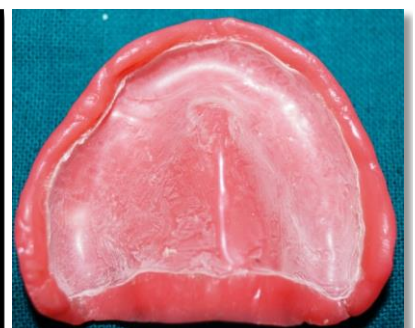**Fig. 6:** Wax replacing impression compound



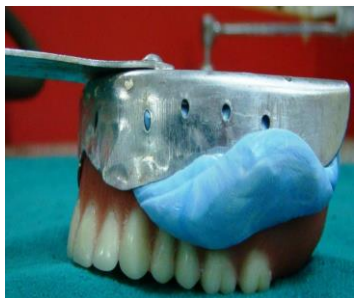**Fig. 7:** Impression of polished surface



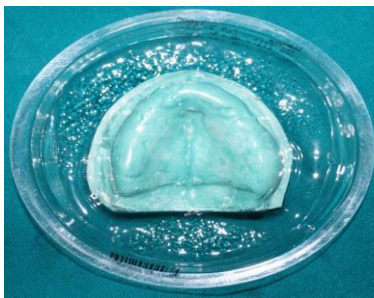
**Fig. 8:** 1.5mm bioplast sheet adaptation



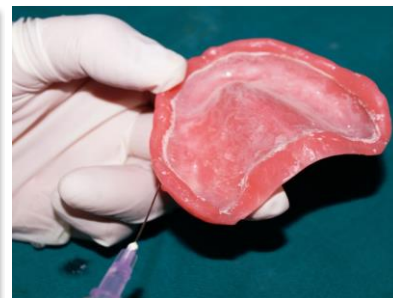**Fig. 9:** Denture with 1.5mm sheet



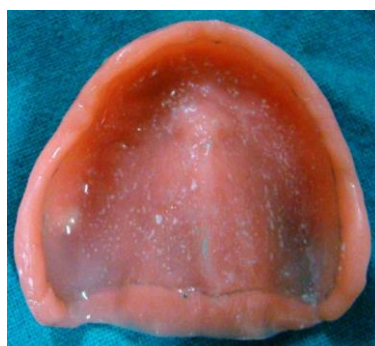**Fig. 10:** Silicone impression of tissue side



**Fig. 11:** Adapting 0.5mm bioplast sheet



**Fig. 12:** Injecting glycerin



**Fig. 13:** Maxillary final impression

## DISCUSSION

The design of fluid retained denture incorporates both the plastic and elastic properties. The flexible nature of polyethylene sheet aids in the adaptation of the denture over the flabby tissue, moreover, it is acting as soft liner at rest to prevent tissue soreness. Denture is rigid enough to support teeth.<sup>7</sup> Liquid used is nontoxic, odorless, having good biocompatibility. It also has good thermal stability, moisture repellency, and low surface tension and vapour pressure.<sup>8</sup>

The “neutral zone” technique is an important procedure in the complete denture prosthesis, especially for atrophic ridges where locations of anterior and posterior denture tooth positions are difficult to determine. Added advantage of locating neutral zone is to neutralize the forces of musculature. It also helps in decreasing the denture bearing area, buccally and labially.

## CONCLUSION

A flabby ridge and atrophic ridge poses a great challenge to denture stability and retention. Fluid retained denture is a unique design for denture fabrication in cases where surgical removal of the flabby tissue cannot be achieved. Concept of neutral zone harmonizes the balance between teeth and musculature, because the patient functionally molds the mandibular rim into the area of the neutral zone, a more stable record base is created.

## REFERENCES:

1. Zarb G A, Bolender C L, Carlsson G E. Boucher's Prosthodontic Treatment for edentulous patients. 11th ed. p 36. London; St. Louis: Mosby, 1997.
2. D. A. Atwood, “Post extraction changes in the adult mandible as illustrated by microradiographs of midsagittal sections and serial cephalometric roentgenograms,” The Journal of Prosthetic Dentistry, vol. 13, no. 5, pp.810-824,1963.
3. Chase WW. Tissue conditioning using dynamic adaptive stress. J Prosthet Dent 1961;11:804-15
4. C. L. Davidson and G. Boere, “Liquid-supported dentures, part I: theoretical and technical considerations,” The Journal of Prosthetic Dentistry, vol. 63, no. 3, pp.303-306,1990.
5. Mc Cord JF, Tyson KW. A conservative prosthodontics option for treatment of edentulous patients with atrophic(flat) mandibular ridges. Br Dent J 1997;182:469-72.
6. Liddelov K P. the prosthetic treatment of the elderly. Br Dent J 1964; 117:307-315
7. D. Kakade, S. Athavale, S. Shingote, and B. Dammani. Liquid-supported denture: a gentle option. Journal of Indian Prosthodontist Society,2007;7:35-9.
8. Pahwa S. et al Liquid Supported Dentures: a viable option for atrophic edentulous ridges. IJDS, 2013;5(5):79-81.

**How to cite this Article:** Deol S, Pathak S, Arora A. Fluid retained denture a relief for flabby ridge: A case report. J Dent Specialities, 2015;3(1):109-111

**Source of Support:** NIL

**Conflict of Interest:** None Declared