

Pedicle flap design- A newer technique in mandibular third molar surgery for reduction of post-operative complications

Choudhury R¹, Kukreja P², Kumar S³, Bhatnagar A⁴, Anand KR⁵, Chhabra V⁶

ABSTRACT

¹PG Student, ²Associate Professor, ³Professor & Head, ⁴Senior Lecturer, ⁵Senior Lecturer, ⁶Senior Lecturer, Dept. of Oral and Maxillofacial Surgery, I.T.S-Centre for Dental Studies & Research, Ghaziabad

Purpose: The aim of this study was to investigate the effects of a new flap design, the pedicle flap used for the removal of mandibular third molars on postoperative morbidity.

Materials and Method: 10 patients with partially erupted mandibular third molar were studied. Swelling, pain, trismus, dry socket and wound dehiscence measures were recorded on days 2 and 7. Data were analysed using the t-independent test and Fischer's exact test.

Results: Facial swelling, pain, restricted mouth opening was seen in the postoperative period. Wound dehiscence was seen in only 1 patient and no incidence of dry socket was noted.

Conclusion: Pedicle flap design has led to better wound healing and lesser incidence of dry socket.

Received: 13-01-2015
Accepted: 28-03-2015

Keywords: Impacted mandibular third molar, Pedicle flap, Pain, Swelling, Trismus, Dry socket, Wound dehiscence.

INTRODUCTION

Third molars are the most likely teeth to be impacted with around 33% of the population having at least one impaction. Studies have showed mandibular third molar impaction occurring with higher incidence over other teeth. This impaction is probably the result of both genetic and environmental factors. A variety of pathoses are related to an impacted third molar. From prophylactic measures to large osteolytic lesions, there are various indications for its removal. Because of its prevalence, thus removal of third molar is one of the most frequent surgical procedures in the oral cavity.^{1,2} Removal of third molar involves manipulation of both soft and hard tissue, so it is often attended by complications which are distressing to patients. The adverse effects of the third molar surgery in the quality of life have been reported to show a three-fold increase in patients who experience pain, trismus and swelling alone or in combination compared to those who were asymptomatic.³ The common complications of lower third molar surgery are pain, trismus, dry socket, swelling, nerve damage, wound infection and delayed onset wound infection which occurs after suture removal, periodontal pocket formation, loss of connective tissue attachment or bone loss on the distal aspect of second molar. Wound dehiscence is another common complication of third molar removal. Dehiscence potentially prolongs the time of healing and may lead to a longer period of discomfort and continuous pain and could cause the development of alveolar osteitis and compromised periodontal status of the adjacent second molar.² Complication of wound

dehiscence is seen with routinely used flap design, the Ward's incision. Because incision is given at the site of bone removal, the incidence of wound dehiscence is more and thus chances of infection are increased. To mask these demerits, the buccal envelope flap is alternatively used. An even newer flap design, the pedicle flap, has come up which has the advantage of better wound closure resulting in lesser incidence of wound dehiscence and dry socket.⁴

A pedicle flap design as described by Goldsmith S, De Silva R, and Tong D, Lowe R (2012) incorporates a distal incision which allows soft tissue advancement and rotation to achieve complete closure of the surgical site over sound bone. This promotes healing by primary intention, minimizes wound dehiscence, loss of the coagulum or exposure of the alveolar bone thus decreasing the risk of dry socket.

The aim of this study was to evaluate the effects of a pedicle flap design as described by Goldsmith S, De Silva R, Tong D, Lowe R (2012)⁴ with severity of common acute postoperative sequelae associated with lower third molar tooth removal. The present study was conducted in the Department of Oral and Maxillofacial Surgery & Oral Implantology, I.T.S Centre for Dental Studies and Research, Muradnagar, Ghaziabad. The study was undertaken for a period of 1 year from September 2012 till September 2013. The sample size of the study was determined by suitable professional software, using data from a previously conducted similar study. The standard deviation was set as 1.92, and expected mean difference of variables was set as 0.84. The level of significance i.e. α - error was 5%, power was 80% and the confidence interval was 95%. On calculation we had found a minimum sample size of 7 patients. We took 10 patients in the present study. The study was approved by the ethical

Address for Correspondence:

Dr. Rupshikha Choudhury, PG Student, Dept. of Oral and Maxillofacial Surgery, I.T.S-Centre for Dental Studies & Research, Ghaziabad
E-mail: rupmds@gmail.com

committee of the institution as well as by the institutional reviewer board. A total of one hundred and eight patients within the age range of 18-40 years who reported to the Department of Oral & Maxillofacial Surgery requiring surgical removal of partially erupted mandibular third molars were evaluated. Routine blood investigations were done for all patients. Orthopantomographic radiographs and intra oral periapical radiographs were obtained to ensure the similarity of the type of impaction. The inclusion and exclusion criteria for the present study were defined as follows-

INCLUSION CRITERIA

1. All the patients in the age group between 18-40 years and in good health.
2. Patients requiring surgical removal of impacted mandibular third molars and who willingly took part in study.

EXCLUSION CRITERIA

1. Patients who were allergic to any of the local anesthetic solutions and / or allergic to medications prescribed in the study.
2. Pregnant and lactating female patients.
3. Medically compromised patients (ASA III and ASA IV). 61
4. Patients who took antibiotics / anti-inflammatory drugs 3 weeks prior to surgery.

METHOD OF STUDY

All the patients underwent a thorough medical and dental evaluation including history of allergy to any drug. Routine blood investigations were carried out prior to the surgery. Only the patients who were categorized as ASA I and ASA II were included in the study. All the patients were explained in detail about the study, its parameters and complications which may occur. A signed written informed consent was obtained from each of the included patients in presence of independent witnesses. Age and sex of the patients were noted. Based on orthopantomogram and intra-oral periapical radiographs, the type of impaction as classified by Pell GJ, Gregory BT (1933), Winter GB (1926), Pederson's difficulty index, root pattern of the third molar and proximity to inferior alveolar canal were noted.

The data recorded preoperatively for every patient included in the study were the facial dimensions measured preoperatively by means of suture material and/ or measuring tape. Four points were marked on the face: at the corner of mouth, at the tragus of ear, at the outer canthus of eye and at the angle of Mandible. The distance from the corner of the mouth to the intertragic notch was denoted as A-B following the bulge of the cheek, and the distance from the outer canthus of the eye to the angle of the mandible was denoted as C-D and measured on a millimeter scale. Pre-operative mouth opening was

evaluated by measuring the inter-incisal opening between the mesio-incisal edges of the right maxillary and mandibular central incisors. The maximum opening of the jaws were recorded by a pair of graduated Vernier calipers preoperatively. All the patients were operated under local anesthesia. Lignocaine 2% with 1:200000 adrenaline was used for inferior alveolar nerve block along with long buccal nerve block and lingual nerve block. Surgical extraction of mandibular third molar was done using a pedicle flap design as described by Goldsmith S, De Silva R, Tong D, Lowe R (2012).⁴

After nerve block was given, an incision was placed in the buccal gingival sulcus from the mesio-buccal line angle of the first molar to the most distal visible aspect of the third molar. The releasing incision then extended distally 1 cm up the external oblique ridge as in buccal envelope incision (Fig.1). A lingual flap was reflected in the subperiosteal plane irrespective of the flap design and lingual nerve protected using a Howarth's retractor. A large round 40 surgical bur (No 8) with copious irrigation was used to remove bone superior, distal and buccal to the crown of the third molar. A fissure bur was used to section the tooth if required. The tooth was then elevated and delivered and the dental follicle removed. Sterile saline irrigation of the socket was done to remove debris. After removal of the third molar, from the distal aspect of the incision that was given on the external oblique ridge was curved towards the buccal sulcus (Fig. 2). This tongue shaped flap is then pulled and rotated over the extracted socket allowing primary closure over sound bone.⁴ (Fig. 3). Interrupted sutures with 3-0 black braided silk were placed to stabilize the flap and close extraction site to desired degree. Haemostasis was achieved prior to flap closure.

Data collection and Statistical analysis

The patients were recalled on the second (48 hours after surgery) and seventh post-operative days for follow-up and the following parameters were assessed. Postoperative pain were measured on a 100mm long Pain Numeric Rating Scale (Fig.-2), which was marked by the patient himself/herself, as per the pain experienced by the patient. Three readings for pain were recorded and the mean was derived. The facial dimensions were measured postoperatively in the similar manner as taken preoperatively. A-B and C-D were measured thrice and their mean derived. The difference between each postoperative measurement and the baseline indicated the facial swelling for that day. To eliminate observer bias only one observer measured the swelling in all patients. Mouth opening was evaluated in the same way as in the preoperative period and the mean derived. The difference between each postoperative measurement and the preoperative measurement indicated the trismus for that day.

The presence of dry socket was assessed based on the following criteria:

- a. Symptoms which start between 1-3 days after extraction.
- b. Loss of blood clot from the socket.
- c. Severe pain irradiating from empty socket, normally to the ipsilateral ear and temporal lobe.
- d. Foul odor.
- e. Regional lymphadenopathy may occur.

f. Bony socket bare of granulation tissue.

Apart from these parameters the extracted sites were evaluated for inflammation, wound dehiscence, breaking of sutures and infection. On the seventh post-operative follow up day, intra oral sutures of the patients were removed and the patients questioned regarding any other related complaints.

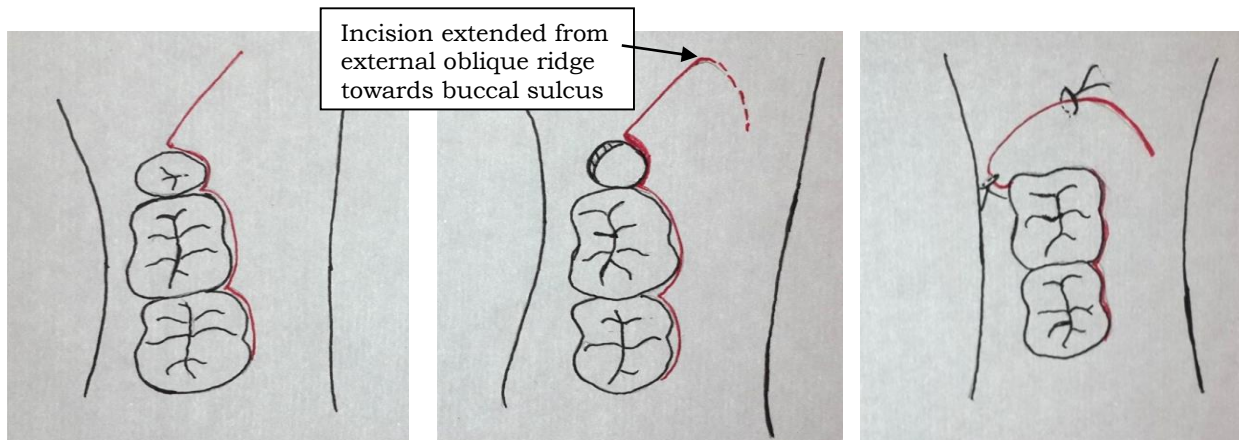


Fig.-1: Buccal envelope incision

Fig.-2: Extention towards buccal sulcus

Fig.-3: Rotational flap closed over socket

RESULTS

The mean value of pain scores (in NRS) on the second post-operative day was M=3.24, SD=1.665, SE= 0.333 and on the seventh post-operative day was M= 1.20, SD= 1.000, SE= 0.200. The measurement of post-operative facial dimension was more on the 2nd post-operative day than the 7th post-operative day. By the seventh post-operative day, the facial dimension values reduced to near the pre-operative value. Table-2 The mean value of facial dimension AB on the pre-operative day was M = 11.0184, SD = 0.62473, SE = 0.2495, on the second post-operative day was M = 11.4632, SD = 0.61252, SE = 0.12250 and on the seventh post-operative day was M = 11.0436, SD = 0.64866, SE = 0.12973. The mean value of facial dimension CD on the pre-operative day was M = 10.0016, SD = 0.68335, SE = 0.13667, on the second post-operative day was M = 10.4828, SD = 0.78136, SE = 0.15627 and on the seventh post-operative day was M = 10.0576, SD = 0.67397, SE = 0.13479.

The mean value of amount of swelling between second post-operative day and pre-

operative day at horizontal axis AB was M = -0.4448, SD = 0.31095, SE = 0.06219, between seventh post-operative day and preoperative day was M = -0.0252, SD = 0.20170, SE = 0.04034 and between second and seventh post-operative day was M = 0.4196, SD = 0.27766, SE = 0.05553.

Again the mean value of swelling at vertical axis CD between preoperative and second post-operative day was M = 0.4812, SD = 0.40417, SE = 0.08083, between seventh day and pre-operative day was M = -0.0560, SD = 0.20351, SE = 0.04070, between second and seventh post-operative day was M = 0.4252, SD = 0.33009, SE = 0.06602. The mean value of mouth opening (in centimeters) on the pre-operative day was M=4.2340, SD=0.75907, SE=0.5181, on the second day was M=2.6016, SD=0.74251, SE=0.14850 and on the seventh post-operative day was M=3.5544, SD= 0.62323, SE= 0.12465. Table-3

No occurrence of dry socket was seen and only 1 (12%) dehiscence has been noticed in one patient where pedicle flaps were used.

Table 1: Distribution of Mean ± Standard Deviation of Pain

Pain	Mean ± Standard Deviation	Sandard Error Mean
Post-operative second day	3.24 ± 1.665	0.333
Post-operative seventh day	1.20 ± 1.000	0.200

Table-2: Distribution of Mean ± Standard Deviation of Swelling

FDAB- Facial Dimension at horizontal axis AB.

FDCD- Facial Dimension at vertical axis CD

Facial Dimension	Mean ± Std. Deviation	Std. Error Mean
Preoperative FDAB	11.0184 ± .62473	0.12495
Preoperative FDCD	10.0016 ± .68335	0.13667
Postoperative Second day FDAB	11.4632 ± .61252	0.12250
Postoperative Second day FDCD	10.4828 ± .78136	0.15627
Postoperative Seventh day FDAB	11.0436 ± .64866	0.12973
Postoperative Seventh day FDCD	10.0576 ± .67397	0.13479

Table 3: Distribution Mouth Opening (inter-incisal distance)

Mouth Opening (inter-incisal distance)	Mean ±Std. Deviation	Std. Error Mean
Pre-operative	4.2340 ± 0.75907	0.15181
Post-operative 2nd day	2.6016 ± 0.74251	0.14850
Post-operative 7th day	3.5544 ± 0.62323	0.12465

DISCUSSION

Surgical removal of an impacted mandibular third molar is one of the most frequently performed minor oral surgical procedures and demands sound understanding of surgical principles to perform it as atraumatically as possible. 1-6 Incisions are placed to gain access to the surgical site for adequate accessibility to perform a clean surgical procedure and for proper visibility of the surgical field. Different designs for the raising of a mucoperiosteal flap to expose an impacted lower third molar have been advocated by various authors, the most common designs being the modified triangle flap and the envelope flap.¹⁻⁴

The presence of various important anatomical structures in the adjacent area around the surgical site has made many surgeons to design an incision, ranging from envelope (Koener's) incision, triangular (Ward's) incision, and its modification, L shaped incision, bayonet shaped incision, comma incision, and -S shaped incision,^{4,5} which would allow proper access and visibility with consideration and protection of the vital anatomical structures. Despite various flap designs in the literature, none of the designs has fulfilled the requirements of an ideal flap for the third molar surgery in order to overcome the various post-operative complications like pain, trismus, swelling, hematoma, periodontal problems distal to the second molar, nerve damage, alveolar osteitis, and wound dehiscence. We agree with Jakse, et al.⁶ that flap design influences primary wound healing after third molar surgery. These complications are the routine sequel due to inflammation as a result of surgery. A major cause of third molar surgical trauma occurs when raising a mucoperiosteal flap to adequately visualize and gain access to the tooth. We have evaluated the effects of this new technique when applied to third molar surgery on post-operative sequelae.

Wound dehiscence is another common post-operative problem related to flap designs. A dehiscence makes hygiene more difficult and requires intense follow up treatment (i.e. frequent irrigation and possible local medication). There is also a chance for longer lasting discomfort caused by the hypersensitivity in the area of the distally exposed root surface of the second molar. Alveolar osteitis and soft tissue abscess are more severe complication that is possible.⁶

To overcome possible disadvantages of flap designs, various authors advocate primary wound closure after lower third molar extraction to allow faster mucosal healing and greater promotion of bone regeneration. The pedicle flap design used in this study which was described by Goldsmith et al⁴ incorporates a distal incision which allows soft tissue advancement and rotation to achieve complete closure of the surgical site over sound bone, potentially enhancing healing by primary intention and minimizing wound dehiscence, loss of the coagulum or exposure of the alveolar bone thus decreasing the risk of developing alveolar osteitis. Like with other flap designs, the common post-operative sequelae of facial swelling, restricted mouth opening and pain was also seen with the pedicle flap design. However in terms of wound healing, this flap design was advantageous over other flap designs as only one patient developed dehiscence on the fifth day. And no patient came with the occurrence of dry socket. Therefore, this new flap design has showed better wound closure and healing in the post-operative period and thus no occurrence of dry socket was seen.

REFERENCES

1. Scherstein E, Lysell L, Rohlin M. Prevalence of impacted third molars in dental studies. Swed Dent J. 1989;18:7-13.
2. Karaca I, Simsek S, Ugar D, Bozkaya S. Review of flap design influence on the health of the

- periodontium after mandibular third molar surgery. *Oral Surg Oral Med Oral Pathol Radiol Endod.* 2007;104:18-23.
3. Obimakinde O.S. Impacted mandibular third molar surgery; an overview. *Dentoscope.* 2009; 16:1-7.
 4. Goldsmith S, De Silva R, Tong D, Love R. Influence of a pedicle flap design on acute postoperative sequelae after lower third molar removal. *Int J Oral Maxillofac Surgery.* 2012; 41:371-5.
 5. Laissle G, Molares P, Fenner F, Carvajal D. Post-operative comparison of two flap designs in lower third molar surgery. *Rev Esp Cir Orł Maxillofac.* 2009;31:185-92.
 6. Jakse N, Bankaoglu V, Wimmer G, Eskici A, Pertl C. Primary wound healing after lower third molar surgery: Evaluation of two different flap designs. *Oral Surg Oral Med Oral Pathol Oral Radiol Endod.* 2002;93:7-12.

How to cite this Article: Choudhury R, Kukreja P, Kumar K, Bhatnagar A, Anand KR, Chhabra V. Pedicle flap design- A newer technique in mandibular third molar surgery for reduction of post-operative complications. *J Dent Specialities*,2015;3(1):76-80

Source of Support: NIL

Conflict of Interest: None Declared