

Co-relation of clinical and histologic grade with soft palate morphology in oral submucous fibrosis patients: A histologic and cephalometric study

Tekchandani V¹, Thakur M², Palve D³, Mohale D⁴, Gupta R⁵

ABSTRACT

^{1,4,5}Postgraduate student, Dept. of Oral Pathology and Microbiology, Swargiya Dadasaheb Kalmegh Smruti Dental College and Hospital, Nagpur

²Professor and Head, Dept. of Oral Pathology and Microbiology, Swargiya Dadasaheb Kalmegh Smruti Dental College and Hospital, Nagpur

³Professor, Dept. of Oral Pathology and Microbiology, Swargiya Dadasaheb Kalmegh Smruti Dental College and Hospital, Nagpur

Introduction: Oral submucous fibrosis (OSMF) is a chronic progressive precancerous condition with an alarming prevalence in India. Prevention and early diagnosis of this condition can not only nip it in the bud, but also curb the menace of malignant transformation of this disease. OSMF is believed to produce fibrotic changes beginning in the soft palate and faucial pillars, progressing anteriorly in the oral cavity.

Aim: The present study was carried out to evaluate and correlate the morphology of soft palate in Oral submucous fibrosis (OSMF) patients to the clinical and histopathologic grade, using digital lateral cephalogram.

Method: A total of 80 patients (40 OSMF and 40 Control) were evaluated for soft palatal morphology. The antero-posterior and supero-inferior dimensions of soft palate were measured on digital lateral cephalogram, categorized as Type 1 to Type 6 and were then compared to clinical and histopathologic grade.

Results: In our study, Type 1 (leaf-shaped) soft palate was found to be the most common followed by Type 6 (crook-shaped) and Type 3 (butt-like) varieties.

Conclusion: The study observed that there was gradual reduction in antero-posterior length of soft palate in OSMF patients and with advancing OSMF, an increasing incidence of Type 6 soft palate was seen.

Keywords: Oral Submucous Fibrosis, Diagnosis, Pathology, Radiography, Anatomy and Histology.

Received: 02-03-2015

Accepted: 29-03-2015

INTRODUCTION

In 1952, Schwartz described five Indian women from Kenya with a condition of the oral mucosa including the palate and pillars of the fauces, which he called "atrophia idiopathica (tropica) mucosae oris", which was later termed as 'Oral Submucous fibrosis' (OSMF)¹.

Occasionally it is preceded by and/or associated with vesicle formation² and is always associated with a juxta-epithelial inflammatory reaction followed by progressive hyalinization of the lamina propria.³ The later subepithelial myofibrosis leads to stiffness of the oral mucosa and deeper tissues with progressive limitation in opening of the mouth and protrusion of the tongue, thus causing difficulty in eating, swallowing and phonation⁴.

The fibrosis of the mucosa over and around the uvula leads to certain characteristic abnormalities in the uvula, such as forward pointing uvula or a vanishing uvula⁵.

According to Joshi (1953), involvement of the soft palate and faucial pillars is perhaps the earliest feature to develop in the natural course of OSMF⁶.

Haider et al who studied the clinical and functional staging in 228 OSMF patients concluded that the bands formed initially in the fauces, followed by buccal and labial areas, with an approximate incidence as follows:⁷

Soft palate (91.4%), buccal mucosa (72.4%), retro-molar region (70.7%) and tongue (8.6%)⁸.

Thus, since the soft palate is the first tissue to be affected in OSMF, there is a need to analyze its morphology in OSMF patients.

Cephalometric analysis is one of the most commonly accepted techniques for evaluating the soft palate^{9,10,11} and is less expensive, more useful, easily achieved with reduced radiation, and correlates with other investigations such as computed tomography¹².

So the present study was carried out to evaluate and correlate the morphology of soft palate in OSMF patients to histopathologic grade using digital lateral cephalogram in order to propose a novel radiographic soft palatal classification system for OSMF, thus eliminating need for biopsy in medically compromised patients.

MATERIALS AND METHODS

A cross-sectional study was performed, comprising of 80 patients, 40 patients belonging to study group (OSMF patients) and 40 disease-free individuals in control group. As per the National Council on Radiation Protection Report, 2003, the effective radiation dose from a lateral cephalogram viz. 3-6 μ Sv, falls under the category of negligible individual dose (up to 10 μ Sv) and is far below the annual dose relative to stochastic effects (up to 5000 μ Sv)¹³. Based on the above facts, the ethical committee deemed the potential benefits of the study as outweighing the associated risks.

Patients showing symptoms and signs of OSMF were selected while patients with known history

Address for Correspondence:

Dr. Vinita Tekchandani, Department of Oral Pathology and Microbiology, Swargiya Dadasaheb Kalmegh Smruti Dental College and Hospital, Wanadongri-Waddhamna Road, Hingna, Nagpur - 441110, Maharashtra, India,
E-mail: drvinitatek@gmail.com

of surgery of palate, cleft lip and palate, scleroderma patients were excluded.

The patients were first examined clinically for mouth opening, tongue protrusion, blanching and palpable vertical fibrous bands, ulcerations, vesicles, burning sensation, difficulty in swallowing, extraoral pouching and inability to blow mouth.

After obtaining written informed consent, patient/ control group participant was positioned in the cephalostat with Frankfurt horizontal plane parallel to the floor. With upper and lower teeth in centric occlusion, with oropharyngeal musculature relaxed, digital lateral cephalogram was shot using Sirona Orthophos XG. Antero-posterior and supero-inferior dimensions as well as morphology of soft palate were analyzed from the cephalograms. The length of the soft palate

was evaluated by measuring the linear distance from the posterior nasal spine (PNS) to the tip of the uvula of the resting soft palate. Supero-inferior dimension of soft palate was measured at the thickest area of soft palate. Morphology of soft palates was classified based on their morphology according to You et al. (2008)¹⁴ as Types: 1 (leaf-shaped), 2 (rat-tail shaped), 3 (butt-like), 4 (straight line), 5 (S-shaped) and 6 (crook shaped) (Fig. 1). After written informed consent, punch biopsy was taken from either right or left buccal mucosa and the formalin fixed tissue was processed to prepare paraffin embedded sections and stained with H & E stain. The tissue was histopathologically evaluated for status of epithelium, degree of subepithelial fibrosis, muscle status and vasculature.




Fig. 1: Schematic representation of different types of soft palates in normal patients according to You et. al. classification(2008).

Khanna JN and Andrade NN (1995) classification was used in the study for clinical and histopathological grading in OSMF patients¹⁵.

classified as Stage II clinically while 5 patients belonged to Clinical stage IVA. No patient having Clinical stage I OSMF was observed in the study group. (Refer Table 1)

Results: In the OSMF group, 25 patients belonged to Clinical stage III, 10 patients were

Table 1: Distribution of OSMF Patients as Per Histopathologic and Clinical Stages

HISTOPATHOLOGIC GRADE	NO. OF OSMF PATIENTS (TOTAL = 40)
GRADE I	3
GRADE II	15
GRADE III	21
GRADE IVA	1
CLINICAL STAGE	NO. OF OSMF PATIENTS (TOTAL = 40)
STAGE I	0
STAGE II	10
STAGE III	25
STAGE IVA	5

In the OSMF group, 22 patients (55%) showed Type 1 soft palate (Fig. 2), 7 patients (17.5%)

showed Type 3 soft palate (Fig. 3), 9 patients (22.5%) showed Type 6 soft palate (Fig. 4) while 1

patient each (2.5%) showed Type 4 and 5 soft palates respectively. No patients having Type 2 soft palatal morphology were observed in the Study group.

In the Control group, 34 patients (85%) had Type 1 soft palate, 2 patients (5%) had Type 3 soft palate while 1 patient each had Type 2, 4, 5 and 6 soft palatal morphologies respectively. (Refer Table 2)

Table 2: Distribution of Soft Palatal Types in Study Group and Control Group

TYPE OF SOFT PALATE	1	2	3	4	5	6	
OSMF	22	0	7	1	1	9	TOTAL:40
CONTROL	34	1	2	1	1	1	TOTAL:40

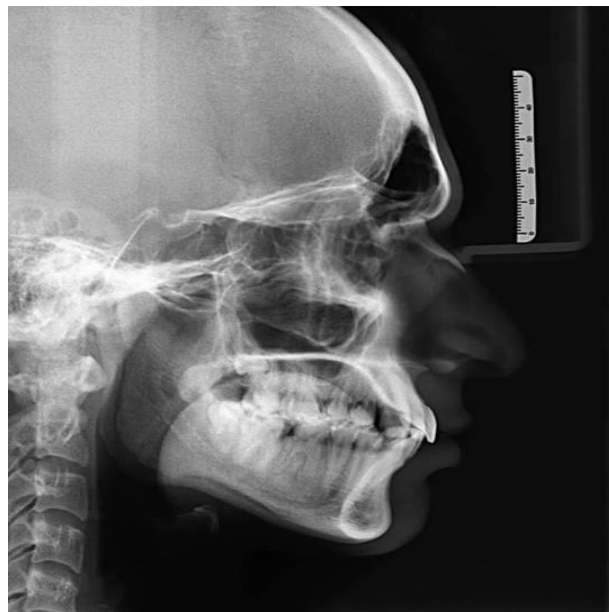

Fig. 2: Type 6 soft palate (Crook-shaped)

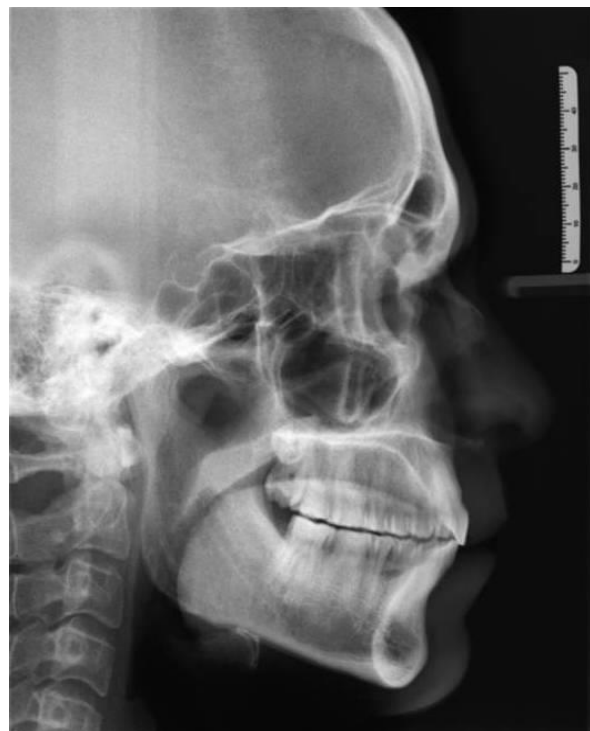

Fig. 3: Type 3 soft palate (Butt-shaped)

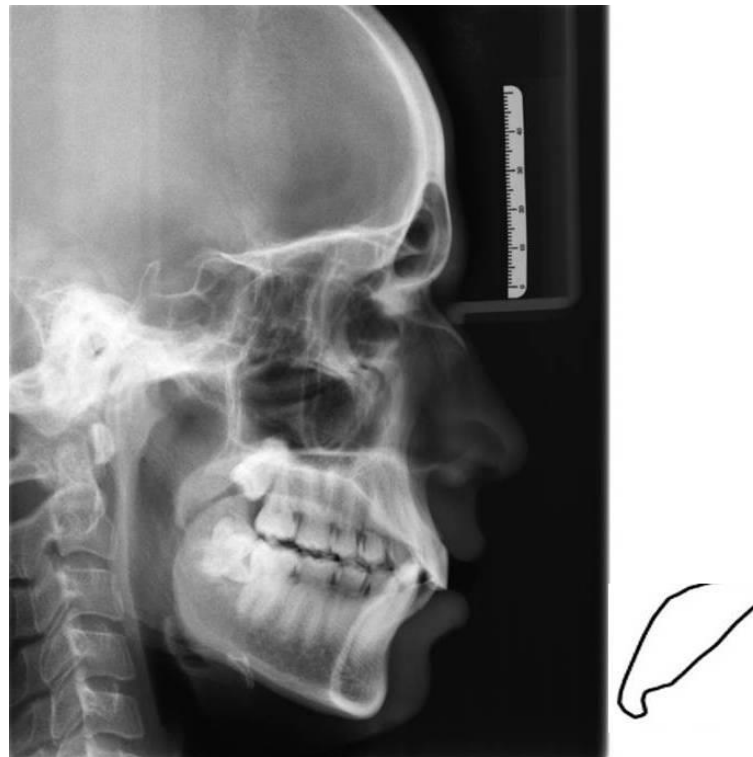


Fig. 4: Type 1 soft palate (Leaf-shaped)

The distribution of types of soft palatal morphologies in different clinical and histologic grades of OSMF was tabulated. (Refer Table 3, 4)

Table 3: Distribution of Type of Soft Palate in Different Clinical Stages of OSMF

STAGE	I	II	III	IVA	TOTAL
TYPE 1	0	10	11	1	22/40
TYPE 2	0	0	0	0	0/40
TYPE 3	0	0	7	0	7/40
TYPE 4	0	0	1	0	1/40
TYPE 5	0	0	1	0	1/40
TYPE 6	0	0	5	4	9/40

With advancing clinical stage of OSMF, an increasing incidence of Type 6 soft palate was seen.

Table 4: Distribution of Type of Soft Palate in Different Histologic Grades of OSMF

GRADE	I	II	III	IVA	TOTAL
TYPE 1	6	13	3	0	22/40
TYPE 2	0	0	0	0	0/40
TYPE 3	0	1	6	0	7/40
TYPE 4	0	0	1	0	1/40
TYPE 5	0	0	1	0	1/40
TYPE 6	0	1	7	1	9/40

With advancing histologic grade of OSMF, an increasing incidence of Type 6 soft palate was seen.

Lengths of soft palate in A-P and S-I dimensions were measured on lateral cephalograms. The mean lengths of soft palate (A-P and S-I) and respective soft palatal morphological types of

Study group Vs. Control group were tabulated (Refer Table 5, 6). The antero-posterior and supero-inferior dimensions of soft palate were compared to the clinical and histologic grade in every patient, as well as to the type of soft palate observed radiographically, thus delivering a comprehensive clinical, histologic and radiographic analysis. (Refer Table 7, 8)

Table 5: A-P and S-I Dimensions of Soft Palate in Study Group and Control Group

TYPE OF SOFT PALATE	MEAN A-P DIMENSIONS (in mm)		MEAN S-I DIMENSIONS (in mm)	
	OSMF	CONTROL	OSMF	CONTROL
TYPE 1	28.05	35.51	11.77	11.01
TYPE 2	--	36	--	8.5
TYPE 3	24.29	31.25	12.29	11.5
TYPE 4	25	35	13	7
TYPE 5	26	31	11	9.5
TYPE 6	23.33	34	10.88	10

As observed in the table, OSMF subjects show reduced antero-posterior and increased supero-inferior dimensions of soft palate on lateral cephalogram with progression of OSMF.

Table 6: Correlation of Radiographic Length and Type of Soft Palate in Study Group and Control Group

PARAMETER	STUDY	MEAN (in mm)	MEDIAN	P VALUE	STATISTICAL SIGNIFICANCE
TYPE OF SOFT PALATE (MANN-WHITNEY TEST)	OSMF	2.650	1.000	0.0118	Significant
	CONTROL	1.425	1.000		
A-P LENGTH (UNPAIRED T-TEST)	OSMF	26.375	26.000	<0.0001	Significant
	CONTROL	35.150	35.500		
S-I LENGTH (UNPAIRED T-TEST)	OSMF	11.600	11.750	0.0138	Significant
	CONTROL	10.813	11.000		

Table 7: Correlation of A-P Dimensions with Clinical/Histologic/Radiographic Parameters

PARAMETER (WILCOXON MATCHED-PAIRS SIGNED-RANKS TEST)	MEAN (in mm)	MEDIAN	P VALUE	STATISTICAL SIGNIFICANCE
A-P LENGTH	26.375	26.000	< 0.0001	Significant
CLINICAL STAGE	2.875	3.000		
A-P LENGTH	26.375	26.000	< 0.0001	Significant
HISTOLOGIC GRADE	2.500	3.000		
A-P LENGTH	26.375	26.000	< 0.0001	Significant
TYPE OF SOFT PALATE	2.650	1.000		

Table 8: Correlation of S-I Dimensions with Clinical/Histologic/Radiographic Parameters

PARAMETER (WILCOXON MATCHED-PAIRS SIGNED-RANKS TEST)	MEAN (in mm)	MEDIAN	P VALUE	STATISTICAL SIGNIFICANCE
S-I LENGTH	11.600	11.750	< 0.0001	Significant
CLINICAL STAGE	2.875	3.000		
S-I LENGTH	11.600	11.750	< 0.0001	Significant
HISTOLOGIC GRADE	2.500	3.000		
S-I LENGTH	11.600	11.750	< 0.0001	Significant
TYPE OF SOFT PALATE	2.650	1.000		

In our study, Type 1 (leaf-shaped) soft palate was found to be the most common (55%) followed by Type 6 (crook-shaped) viz. 22.5 % and Type 3 (butt-like) viz. 17.5%. (Ref. Table 2)

The mean values of all dimensions for Clinical stage, Histopathologic grade and Type of soft palate was calculated by addition of all the measurements divided by number of cases in each type.

In the OSMF group, the mean length of the soft palate antero-posteriorly was 28.05mm for Type 1, 24.29mm for Type 3, 25mm for Type 4, 26mm for Type 5 and 23.33mm for Type 6 variety with the corresponding values in Control group being 35.51mm, 31.25mm, 35mm, 31mm and 34mm, indicating shortening of length with shift in the type of soft palate corresponding to worsening of the disease state. The mean soft palatal length supero-inferiorly was 11.77mm for Type 1, 12.29mm for Type 3, 13mm for Type 4, 11mm for Type 5 and 10.88mm for Type 6 variety, with the corresponding values in Control group being 11.01mm, 11.5mm, 7mm, 9.5mm and 10mm, thus giving variable results. (Refer Table 5)

Histopathologically, 21 out of 40 OSMF patients were classified as having Grade III OSMF, 15 patients as Grade II, 3 patients as Grade I and 1 patient as Grade IVA (Refer Table 1)

The only patient showing Grade IVA OSMF histopathologically, had 14mm antero-posterior soft palatal length, 10mm supero-inferior soft palatal length and belonged to Stage IVA clinical stage as per Khanna and Andrade classification (1995).

DISCUSSION

The palatine uvula, usually referred to as simply the uvula is a conical projection from the posterior edge of the middle of the soft palate, composed of connective tissue containing a number of racemose glands, and some muscular fibers (musculus uvulae). The musculus uvulae, which lies entirely within the uvula, shortens and broadens the uvula. This changes the contour of the posterior part of the soft palate^{16, 17}. Morphometric assessment of the nasopharynx or the configuration of adjacent structures can be defined in terms of depth and height in the

median sagittal plane on lateral cephalogram¹⁸. The present study is undertaken to study the morphology of soft palate in OSMF patients using radiographs and correlating the same to clinical and histologic grade respectively.

Cephalometry is a relatively inexpensive method and permits a good assessment of the soft tissue elements that defines the soft palate and its surrounding structures¹⁸. Although histological analysis of haemotoxylin and eosin (H & E)-stained tissue sections remains the mainstay in the diagnosis of OSMF, radiographic evaluation can be considered a powerful tool for the same.

Lateral cephalograms can be used as an adjunct to conventional biopsy, and may eliminate the need for biopsy in cases of mass screening camps, medically compromised patients, cross-sectional community studies and patients with drastically reduced mouth opening.

This study can aid to observe the extent of disease progress, to devise a comprehensive treatment plan with regards to the morphological and anatomic corrections of the soft palate, post-surgical speech therapy and treatment of associated dysphagia.

A morphological classification of soft palate in normal individuals was proposed by You et al. (2008)¹⁴.

Knowledge about the varied morphological pattern of soft palate in OSMF patients can give us a clear understanding about disease progress in oropharyngeal region. Thorough understanding and knowledge of associated changes will help the maxillofacial surgeon in successful structural and functional corrections associated with this disorder⁸.

To our knowledge, ours is the first study comparing the clinical, histologic and radiographic aspects in OSMF patients.

In our study group, maximum patients demonstrated a Type 1 soft palatal morphology, even though statistically significant difference in the antero-posterior and supero-inferior dimensions was observed, when compared to control group.

After Type 1, maximum incidence of Type 6 followed by Type 3 and Type 2 soft palatal morphology was seen in the study group.

The anterior-posterior dimensions were the least for Type 6 soft palate and maximum for Types 1 and 2, shorter dimensions were seen with worsening of the disease status while the superior-inferior dimensions were least for Type 6 and maximum for Type 4 soft palate. Both A-P and S-I values showed significant correlation with Clinical stage, Histologic grade and Type of soft palate.

The difference in the antero-posterior and supero-inferior dimensions between OSMF and Control patients was statistically significant, indicating the severity of fibrotic changes involving soft palate observed in this disease.

In our sample size, 15 out of 40 (37.5%) OSMF patients did not show correlation between clinical staging and histopathologic grading. This non-correlation can be attributed to differential fibrosis, with more posterior bands causing further limitation of mouth opening. It is in cases like these, that radiographic evaluation can be used as an adjunct, for a more definitive diagnosis and an appropriate treatment plan.

We also observed in our study that OSMF patients having an A-P length of >35mm radiographically, fell in the category of Grade I OSMF histopathologically. Similarly, an A-P length in the range of 26-35mm corresponded with Grade II OSMF, 15-25mm corresponded with Grade III OSMF and <15mm A-P length corresponded with Grade IVA OSMF histopathologically. S-I length gave variable results in this regard. These observations, if validated using a larger sample size, can aid in serving as an independent diagnostic paradigm in the near future.

CONCLUSION

We observed that, as OSMF progressed to advanced stages, increased incidence of Type 3 and Type 6 variety of soft palate on lateral cephalogram was seen.

A gradual reduction in A-P length and increase in S-I length was observed, suggesting that soft palate becomes shorter and thicker with advancing stage. But, the results were more pronounced in the antero-posterior direction than in supero-inferior direction.

In our study, the mean length of the soft palate antero-posteriorly in OSMF patients was significantly less than the corresponding value in control subjects signifying the fibrotic changes occurring leading to a shrunken uvula.

To conclude, the measurements noted with regards to the A-P and S-I length radiographically were seen to correlate with the OSMF grade histopathologically, which could be utilized as a non-invasive predictor of OSMF grade and can be especially useful for patients who are deemed medically unfit to undergo biopsy. These observations have scope for validation using a larger sample size.

ACKNOWLEDGEMENTS

Dept. of Oral Medicine and Radiology, (Swargiya Dadasaheb Kalmegh Smruti Dental College and Hospital, Nagpur)

REFERENCES

1. Sirsat SM, Khanolkar VR. Submucous fibrosis of the palate and pillars of the fauces. *Indian J Med Sci.* 1962 Mar;16:189-97.
2. Pindborg JJ, Singh B. Formation of vesicles in oral submucous fibrosis. *Acta Pathol Microbiol Scand.* 1964;62:562-6.
3. Sirsat SM, Pindborg JJ. Subepithelial changes in oral submucous fibrosis. *Acta Pathol Microbiol Scand.* 1967;70(2):161-73.
4. Wahi PN, Luthra UK, Kapur VL. Submucous fibrosis of the oral cavity. *Histomorphological studies.* *Br J Cancer.* 1966 Dec;20(4):676-87.
5. Chaturvedi P. Uvular abnormalities in patients with submucous fibrosis. *Oral Dis.* 2009 Oct;15(7):516.
6. Joshi SG. Submucous fibrosis of the palate and pillars. *Indian J Otolaryngol* 1953;4:1-4.
7. Haider SM, Merchant AT, Fikree FF, Rahbar MH. Clinical and functional staging of oral submucous fibrosis. *Br J Oral Maxillofac Surg.* 2000 Feb;38(1):12-5.
8. Shankar VN, Hegde K, Ashwini NS, Praveena V, Ravi Prakash SM. Morphometric evaluation of soft palate in oral submucous fibrosis-a digital cephalometric study. *J Craniomaxillofac Surg.* 2014 Jan; 42(1):48-52.
9. Bejdoová S, Krajiček V, Peterka M, Trefný P, Velemínská J. Variability in palatal shape and size in patients with bilateral complete cleft lip and palate assessed using dense surface model construction and 3D geometric morphometrics. *J Craniomaxillofac Surg.* 2012 Apr; 40(3):201-8.
10. Shimomatsu K, Nozoe E, Ishihata K, Okawachi T, Nakamura N. Three-dimensional analyses of facial soft tissue configuration of Japanese females with jaw deformity-a trial of polygonal view of facial soft tissue deformity in orthognathic patients. *J Craniomaxillofac Surg.* 2012 Oct;40(7):559-67.
11. Heliövaara A, Rautio J. A comparison of craniofacial cephalometric morphology and the later need for orthognathic surgery in 6-year-old cleft children. *J Craniomaxillofac Surg.* 2011 Apr;39(3):173-6.
12. Samman N, Mohammadi H, Xia J. Cephalometric norms for the upper airway in a healthy Hong Kong Chinese population. *Hong Kong Med J.* 2003 Feb;9(1):25-30.
13. White S, Pharoah M. *Oral Radiology: Principles and Interpretation.* 6th ed. India: Mosby; 2009.
14. You M, Li X, Wang H, Zhang J, Wu H, Liu Y, Miao J, Zhu Z. Morphological variety of the soft palate in normal individuals: a digital cephalometric study. *Dentomaxillofac Radiol.* 2008 Sep;37(6):344-9.
15. Khanna JN, Andrade NN. Oral submucous fibrosis: a new concept in surgical management. Report of 100 cases. *Int J Oral Maxillofac Surg.* 1995 Dec;24(6):433-9.
16. Drake, Richard L, Vogl, Wayne; Tibbitts, Adam W.M. Mitchell. illustrations by Richard; Richardson, Paul. *Gray's anatomy for students.* Philadelphia: Elsevier/Churchill Livingstone; 2005.

17. Birch MJ, Srodon PD. Biomechanical properties of the human soft palate. *Cleft Palate Craniofac J*. 2009 May;46(3):268-74.
18. Bitar MA, Macari AT, Ghafari JG. Correspondence between subjective and linear measurements of the palatal airway on lateral cephalometric radiographs. *Arch Otolaryngol Head Neck Surg*. 2010 Jan;136(1):43-7.

How to cite this Article: Tekchandani V, Thakur M, Palve D, Mohale D, Gupta R. Co-relation of clinical and histologic grade with soft palate morphology in oral submucous fibrosis patients: A histologic and cephalometric study. *J Dent Specialities*,2015;3(1):68-75

Source of Support: NIL

Conflict of Interest: None Declared