

Sella turcica morphology- a diagnostic marker for skeletal class II malocclusion?

Prarthna B¹, Saurabh S², Batra P³, Dhillon M⁴

¹MDS (Orthodontics) Tutor, ESI Dental College, Rohini, New Delhi

²MDS (Orthodontics) Professor, Dept. of Orthodontics, IDST, Modinagar, U.P.

³MDS (Orthodontics) Vice Principal, Professor & Head, Dept. of Orthodontics, IDST, Modinagar, U.P.

⁴BDS, Private practitioner, New Delhi

ABSTRACT

Objective: The aim of this study is to describe shape and measure the size of the sella turcica in subjects with class I and class II skeletal types and to check whether sella can be considered as diagnostic marker for skeletal class II malocclusion.

Material and Methods: Lateral cephalometric radiographs of 44 individuals (age; 15–30 years) were taken and classified skeletally; 22 as Class I and 22 as Class II (11 males and 11 females in both groups). The linear dimensions (length, depth and diameter) of sella turcica were measured. Student's t-test was used to calculate differences in linear dimensions.

Results: Results show that the sella turcica presented with normal morphology in the majority of subjects (61 percent). No significant differences were found in linear dimensions between genders. Significant difference was found in the depth of sella between Class I and Class II subjects ($p < 0.05$) with smaller depth measurements in skeletal Class II subjects.

Conclusions: Significant difference was found in depth of sella between Class I and Class II subjects with smaller depth measurements in Class II subjects. It is concluded that size of sella turcica can be used to approximate the size of the pituitary gland in skeletal Class II malocclusion. Skeletal class II cases due to mandibular deficiency are associated with smaller depth of pituitary fossa.

Keywords: Sella turcica, Skeletal class II, Morphology, Lateral cephalograms

Received: 06-02-2015

Accepted: 26-03-2015

INTRODUCTION

In cephalometric analyses of neurocranial and dentofacial morphology, the sella point constitutes an important reference point. Many studies^{1,2} have illustrated the changes in sella turcica shape during growth (Fig. 1). Apposition at tuberculum sellae and resorption at posterior boundary of sella turcica occurs upto age of 16–18 years. Thus point sella would be displaced backwards and downwards during growth and development. There are very few cephalometric

standards available on normal growth and development of sella turcica.³

Morphology of sella turcica may vary from individual to individual, and the establishment of normal standards will aid in the process of eliminating any abnormality in such an important region.

Therefore, the aim of this study was

- to analyse the morphological shape and measure the linear dimensions of sella turcica to determine if there is any relationship between sella morphology and skeletal class i.e. skeletal class I and class II patterns
- to check whether sella morphology can be used as a marker for skeletal class II malocclusion

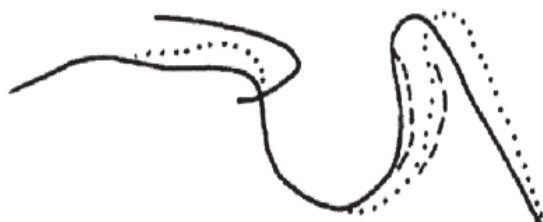


Fig. 1 contour of normal sella turcica morphology analysed from lateral cephalograms, from childhood (solid line) to adulthood (dotted line). Upper contour of anterior wall of sella turcica appears to be perpendicular and unchanged during normal course of development. The increasing size of the sella turcica under normal conditions is a result of resorption and apposition process on the dorsum sellae.

Address for Correspondence:

Dr Saurabh Sonar MDS (Orthodontics) Professor, Dept. of Orthodontics, IDST, Modinagar, U.P.
Email: saurabhsonar@hotmail.com

MATERIAL AND METHODS

The data comprised of lateral cephalometric radiographs taken from archives of Department of Orthodontics, IDST, Modinagar. The sample size was calculated maintaining the standard deviation at 5 and least permissible error at 1.5, with power of 80%. This showed that we needed a sample of at least 40 subjects (20 in both groups). Cephalometric radiographs of 44 patients (22 males and 22 females) aged 15–30 years were used in the study. Radiographs had been taken by trained radiographic technicians in a standardized manner using the same cephalostat. Only radiographs that had the clearest reproduction of the sella turcica area

were selected. All linear measurements were corrected for magnification differences prior to the statistical analyses. The radiographs were distributed according to skeletal relationship; 22 Class I & 22 Class II. Classification of skeletal type into Class I or Class II was based on the ANB angle (SNA and SNB) and was categorized as follows: angles ± 2 degrees Class I skeletal base and angles more than 4 degrees Class II. As the ANB angle is affected by the position of nasion and jaw rotations, so to overcome the limitations of the ANB angle and to further describe jaw severity/discrepancy, the Wits analysis was used: "AO-BO" = 0-4mm class I skeletal base and more than 4 mm Class II. The ANB angle and Wits analysis indicate only the magnitude of the skeletal jaw discrepancy, regardless of which jaw is at fault. So the distance of Nasion perpendicular to point A and Nasion perpendicular to Pogonion was also calculated. The subjects who were characterized by class II malocclusion due to mandibular deficiency only were selected for the study. Table 1 shows the distribution of malocclusion in the subjects according to skeletal relationship and gender.

Table 1: Subjects grouped according to gender and skeletal Class.

Skeletal Class	CLASS I	CLASS II
MALES	11	11
FEMALES	11	11
TOTAL	22	22
SNA	83.22°	83.32°
SNB	80.04°	76.86°
ANB	3.09°	6.68°
AO-BO	2.22mm	6.45mm
N perp-A	1.58mm	1.72mm
N perp-Pog	3.88mm	7.43mm

Cephalometric tracing of sella turcica: The sella turcica on each cephalometric radiograph was traced on thin acetate paper under optimal illumination. This tracing was superimposed on graph paper marked in square millimetres to calculate the sella area.³ The configuration of the sella turcica, which consisted of the tuberculum sellae, the sella turcica floor, the dorsum sellae, and both anterior and posterior clinoid processes, was drawn.

Shape of the sella turcica: To determine the variations in shapes of the sella turcica, the six different morphological appearances of sella given by Axelsson⁴ et al. was used (Fig. 2).

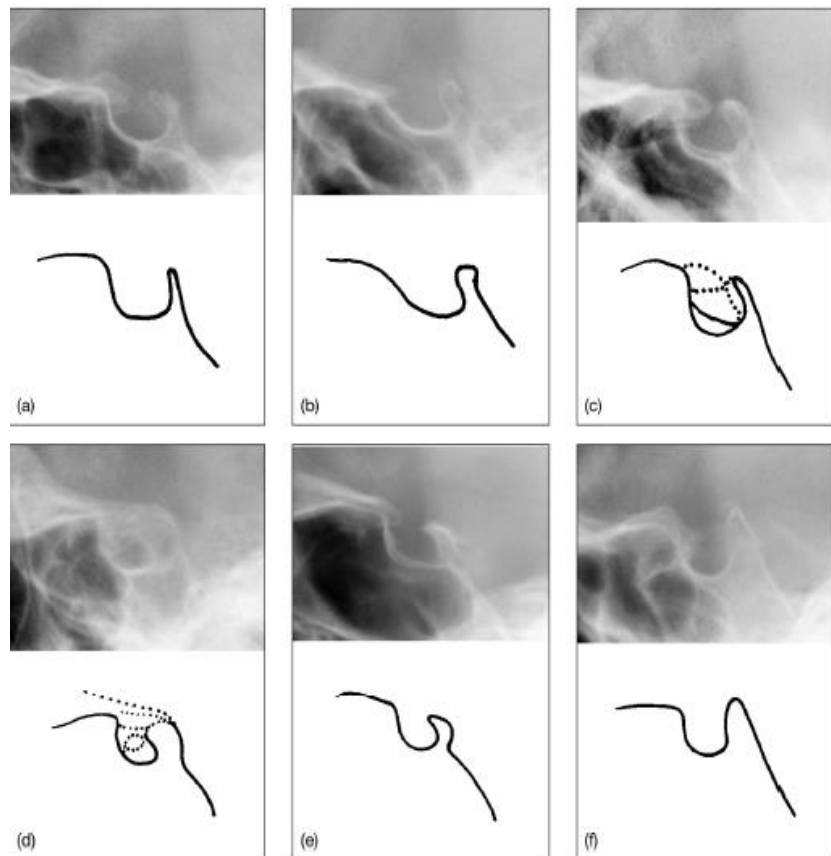


Fig. 2 Different morphological type of sella turcica: a) normal sella turcica, b) oblique anterior wall, c) double contour of floor, d) sella turcica bridge, e) irregular dorsum sella, f) pyramidal shape of dorsum sella.

Size of the sella turcica: The linear dimensions of sella turcica were measured using the methods of Silverman³ and Kisling⁵. All reference lines used in the current study were located in the midsagittal plane (Fig.3). The length of sella turcica was measured as the distance from the tuberculum sella to the tip of the dorsum sellae. The depth of the sella turcica was measured as a perpendicular from the line above to the deepest point on the floor. A line was also drawn from the tuberculum sella to the furthest point on the posterior inner wall of the fossa. This was considered as the antero-posterior diameter of sella turcica.

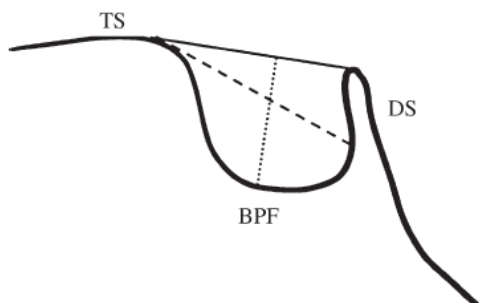


Fig. 3 reference lines used for measuring sella size: TS- tuberculum sella; DS- dorsum sella; BPF- base of pituitary fossa; black line- length of sella; dashed line- diameter of sella; dotted line- depth of sella.

Statistical analyses: To assess the error of location of the reference points and digitizing

procedure, 20 randomly selected tracings were retraced and remeasured after 2 weeks. Casual errors were assessed by using Dahlberg's formula, and systematic errors were ascertained by using paired t tests. No casual errors were found.

A Student's t -test was used to calculate the mean differences in sella turcica linear dimensions between males and females, and between the different skeletal classes (significance was calculated at the 0.05 level).

RESULTS

Shape of the sella turcica: The morphology of the sella turcica appeared to be normal in shape in the majority of subjects (61.36 per cent), regardless of gender, age, or skeletal type (Table 2). Variation in morphological appearance was present in 38.64 per cent of the individuals; an irregular dorsum sella was found in 15.91 per cent, while an oblique anterior wall, sella turcica bridge, pyramidal shape of dorsum sella and a double-contoured floor were present in 9.09, 6.82, 4.55, and 2.27 percent respectively. No significant differences were found in morphology of sella turcica when compared between class I subjects and class II subjects (Table 3). Nor any difference was found when morphology was compared in between genders (Table 3).

Table 2 Frequency distribution of sella turcica type

MORPHOLOGY	FREQUENCY	PERCENTAGE	CUMULATIVE FREQUENCY	CUMULATIVE PERCENTAGE
Normal sella turcica	27	61.36	27	61.36
Oblique anterior wall	4	9.09	31	70.45
Sella turcica bridge	3	6.82	34	77.27
Double contour of floor	1	2.27	35	79.54
Irregular dorsum sella	7	15.91	42	95.45
Pyramidal shape of dorsum sella	2	4.55	44	100
Total	44	100	44	100

Table 3 Frequency distribution of sella turcica type according to skeletal class and gender

MORPHOLOGY	CLASS I	CLASS II	p-value	Males	Females	p-value
Normal sella turcica	14	13	0.126	15	12	0.179
	63.6%	59.1%		68.2%	54.5%	
Oblique anterior wall	1	3		2	2	
	4.5%	13.6%		9.1%	9.1%	
Sella turcica bridge	0	3		0	3	
	.0%	13.6%		.0%	13.6%	
Double contour of floor	0	1		1	0	
	.0%	4.5%		4.5%	.0%	
Irregular dorsum sella	6	1		2	5	
	27.3%	4.5%		9.1%	22.7%	
Pyramidal shape of dorsum sella	1	1	2	0		
	4.5%	4.5%	9.1%	.0%		
Total	22	22	22	22		
	100.0%	100.0%	100.0%	100.0%		

Size of the sella turcica: The linear dimensions of the sella turcica located in the midsagittal plane area are presented in Table 4. The average length, depth, and diameter of the sella turcica for both females and males are shown. When

comparing linear dimensions of sella turcica between genders, no significant differences between females or males in terms of length, depth, or diameter size could be found.

Table 4 Sella turcica linear dimensions for females and males (in millimetres).

	Gender	n	Mean	Standard Deviation	t-value	p-value
Length	Female	22	9.43	2.156	.7318	>.05
	Male	22	9.20	2.213		
Diameter	Female	22	11.75	1.804	.8472	>.05
	Male	22	11.48	1.822		
Depth	Female	22	7.93	1.094	.6205	>.05
	Male	22	8	1.234		

In order to determine if subjects with different skeletal patterns presented with different linear dimensions of the sella turcica, irrespective of gender, a Student’s t -test was performed. A significant difference was found between skeletal classes in the depth of the sella turcica (p < 0.05; Table 5a & 5b). The mean depth was significantly smaller in Class II subjects as compared to class I subjects.

Table 5(a) Sella turcica linear dimensions for skeletal class I and class II (in millimetres).

	Skeletal class	n	Mean ± SD	Standard error of mean
Length	Class I	22	9.4546 ± 2.0869	.4449
	Class II	22	9.1818 ± 2.2759	.4853
Diameter	Class I	22	11.75 ± 1.8306	.3903
	Class II	22	11.4773 ± 1.7960	.3829
Depth	Class I	22	8.3863 ± .9377	.1999
	Class II	22	7.5455 ± 1.214	.2588

Table 5(b) t-test results for comparison of effects of skeletal Class on sella linear dimensions (in millimetres).

	Class I	Class II	t-value	p-value
Length	9.4546 ± 2.0869	9.1818 ± 2.2759	.6808	>.05
Diameter	11.75 ± 1.8306	11.4773 ± 1.7960	.6205	>.05
Depth	8.3863 ± .9377	7.5455 ± 1.214	.0140	*<.05

*p <.05 shows statistical significant difference between class I and Class II for sella turcica depth.

DISCUSSION

The pituitary gland originates in the embryo as a result of interaction between two ectodermal tissues; neural ectoderm gives rise to the posterior pituitary, whereas a portion of the oral ectoderm develops into the anterior pituitary gland. A number of common molecular pathways are involved during the early stages of pituitary, dental, and skull development, which include signalling mediated through bone morphogenetic proteins, fibroblast growth factors, and hedgehog proteins.^{6,7} Moreover, disruption in these signalling pathways can give rise to inherited syndromic conditions that can include aberrations of the sella turcica as part of the clinical spectrum of the disease.

This study describes the morphological appearance and linear dimensions of the sella turcica in subjects with skeletal class II malocclusion. The rationale came from previous observations demonstrating an increased prevalence of localized dental anomalies and extremes of craniofacial skeletal variation in subjects with sella abnormalities.⁸ Furthermore, it has been demonstrated that anomalies associated with sella turcica can be a feature of

human craniofacial syndromes.⁹ Shape variation in the sella turcica has long been reported by many researchers.¹⁰⁻¹⁴ Gordon and Bell¹⁰ classified the sella turcica into circular, oval, and flattened, or saucer shaped. Davidoff and Epstein¹⁵ used the term ‘J-shaped sella’, while ‘omega sella’ was introduced by Fournier and Denizet.¹⁶

In a recent study Axelsson⁴ et al., the shape of the sella turcica was categorized into six main types; normal sella turcica, oblique anterior wall, double-contoured sella, sella turcica bridge, irregularity (notching) in the posterior part of the sella, and pyramidal shape of the dorsum sellae (Fig.2). Sella turcica bridging or calcification of the ICL (interclenoid ligament) is seen in association with inherited developmental conditions that can affect the craniofacial region.¹⁷

An alteration in the shape of the sella turcica can be misleading since it may be present in ‘normal’ subjects^{11,13,14}, as well as in medically compromised subjects such as those with spina bifida¹⁸ and craniofacial deviations.¹⁹

In the current study, approximately 61 percent of the subjects appeared to have a normal shaped

sella turcica, while 39 percent presented with different aberrations. Axelsson⁴ et al. reported 68 percent as normal. The finding of an irregular notching of the dorsum sella was about 19 percent in present study and 11 percent in the previous study. A doubled contour floor was present in 2.27 percent of the subjects of the current study, which is much lower than that reported by Alkofide.²⁰ In the current study, sella bridge was found in only 6.82 percent of the subjects which is much more than that previously reported by Alkofide.²⁰ These differences can be due to different sample size and ethnic origin of subjects in current study. Moreover in present study both partial and incomplete calcifications of ICL were counted as sella turcica bridge.

When determining if any differences existed in the present study between males and females in terms of sella turcica size, length and diameter are found to be more in females while depth is more in male subjects (Fig. 4). But these differences are not statistical significant. Similar findings were reported by Israel²¹ who concluded that sella turcica size in young adult males and females were almost the same. On the other hand, Haas²² compared the mean size in square millimetres of the sella area of boys and girls aged 3 – 17 years and found some differences due to gender. He reported that the sella turcica of boys was greater than girls, but after 17 years of age, the sella of females were slightly larger than that of males.

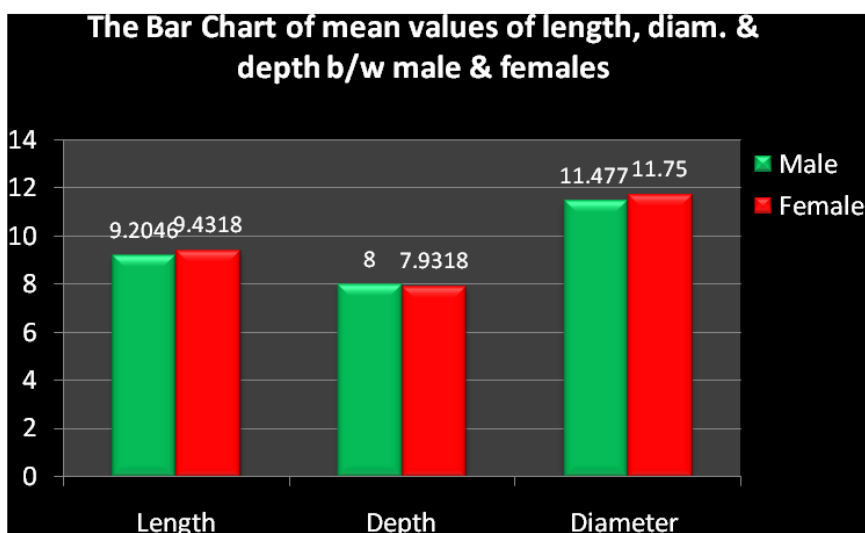


Fig. 4 The bar chart of mean values of length, diam. & depth b/w male & females

Preston²³ showed no statistically significant correlation between facial type and the mean sella area of the pituitary fossa. however, contrary to the current study in which linear dimensions were used, the mean sella area was measured by Preston.²³ Alkofide²⁰ compared linear dimensions of sella turcica in skeletal Class II and Class III subjects, and found a significant difference between the diameter of the sella turcica in both classes. An increase in diameter size was found to be more common in Class III subjects, while a reduced diameter size was more prevalent in Class II individuals. In the present study, when

skeletal type and linear dimensions of sella turcica were evaluated, differences were found in length, depth and diameter of sella in skeletal class I and class II (Fig. 5). In general class II subjects have smaller dimensions of sella turcica. But statistical significant difference is found only in depth of sella between class I and class II. (Fig.5). We feel depth is a more reliable parameter than diameter because it uses base of pituitary fossa as the reference point. In measuring diameter, furthest point on the posterior inner wall of the fossa is used which is difficult to locate.

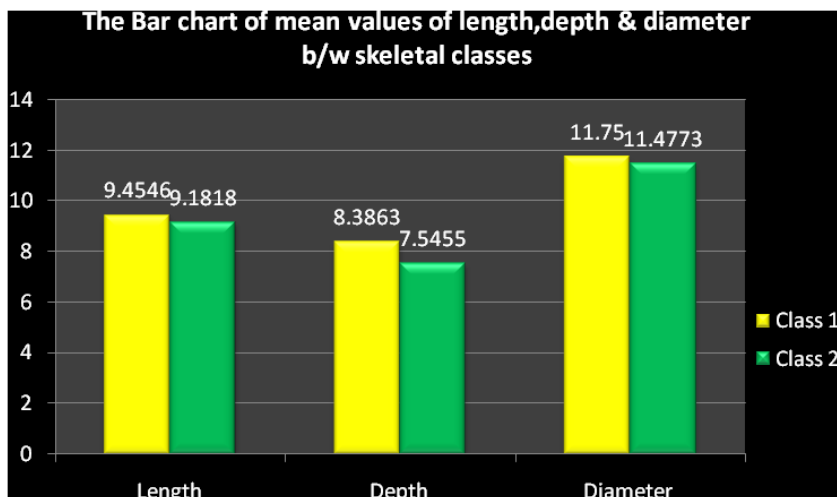


Fig. 5 The Bar chart of mean values of length, depth & diameter b/w skeletal classes

CONCLUSIONS

It is concluded from the study that the linear dimensions of sella can be used to approximate the size of the pituitary gland in different malocclusions. This may aid the clinician when confronted with an abnormally large or small sella area on lateral cephalograms. The orthodontist should also be familiar with the different shapes of the sella area, in order to help distinguish pathology from normal developmental patterns.

Following conclusions are drawn from the study:

1. Approximately 61 per cent of the investigated subjects had a normal sella shape.
2. No significant differences in size of the sella could be found between genders.
3. When sella size was compared with skeletal type, a significant difference was found in depth of sella between Class I and Class II subjects. Smaller depth measurements were apparent in Class II subjects.
4. Average depth of sella in class II skeletal malocclusions is found to be 7.55mm

REFERENCES

1. Bjork A. Cranial base development. *Am J Orthod* 1955;41:198 – 225.
2. Melsen B. The cranial base: the postnatal development of the cranial base studied historically on human autopsy material. *Acta Odontol Scand* 1974;32:57 – 71.
3. Silverman FN. Roentgen standards for size of the pituitary fossa from infancy through adolescence. *Am J Roentgenol* 1957;78:451 – 460.
4. Axelsson S, Storhaug K, Kjær I. Post-natal size and morphology of the sella turcica. Longitudinal cephalometric standards for Norwegians between 6 and 21 years of age. *Eur J Orthod* 2004;26:597–604.
5. Kislning E. Cranial morphology in Down’s syndrome. A comparative roentgencephalometric study in adult males. Master’s Thesis 1966, Munksgaard, Copenhagen
6. Kim HJ, Rice DP, Kettunen PJ, Thesleff I. FGF-, BMP- and Shh-mediated signalling pathways in the

- regulation of cranial suture morphogenesis and calvarial bone development. *Development* 1998;125:1241–1251
7. Treier M et al. Hedgehog signaling is required for pituitary gland development. *Development* 2001;128:377–386
8. Leonardi R, Barbato E, Vichi M, Caltabiano M A sella Turcica Bridge in subjects with dental anomalies. *Europ J Ortho*, 2006;28:580–585
9. Kimonis V E et al. Clinical manifestations in 105 persons with nevoid basal cell carcinoma syndrome. *Am J Med Genet*,1997;69:299–308
10. Gordon MB, Bell AL. A roentgenographic study of the sella turcica in 104 normal children. *N Y State J Med* 1922;22:54–59.
11. Camp JD. Normal and pathological anatomy of the sella turcica as revealed by roentgenograms. *Am J Roentgenol* 1924;12:143–156.
12. Teal JS. Radiology of the adult sella turcica. *Bulletin of the Los Angeles Neurological Society* 1977;42:111 –174.
13. Kantor ML, Norton LA. Normal radiographic anatomy and common anomalies seen in cephalometric films. *Am J Orthod* 1987;91:414–426.
14. Tetradis S, Kantor ML. Prevalence of skeletal and dental anomalies and normal variants seen in cephalometric and other radiographs of orthodontic patients. *Am J Orthod Dentofac Orthop* 1999;116:572 – 577.
15. Davidoff LM, Epstein BS. *The abnormal pneumoencephalogram*. Philadelphia. Lea and Fibiger. 1950.
16. Fournier AM, Denizet D. Omega shaped sella turcica. *Marseille Medical* 1965;102:503–509.
17. Leonardi R, Farella M, Cobourne MT. An association between sella turcica bridging and dental transposition. *Eur J Orthod*, 2011;33(4):461-5.
18. Kjær I , Wagner A , Madsen P , Blichfeldt S , Rasmussen K , Russell B. The sella turcica in children with lumbosacral myelomeningocele. *Eur J Orthod* 1998;20:443–448.
19. Becktor J, Einersen S, Kjær I. A sella turcica bridge in subjects with severe craniofacial deviations. *Eur J Orthod* 2000;22:69–74.
20. Alkofide EA. The shape and size of sella turcica in class I, II, and III. *Eur J Orthod* 2007;29:457–463.

21. Israel H. Continuing growth in sella turcica with age. *Am J Roentgenol* 1970;108:516-527.
22. Haas L. The size of the sella turcica by age and sex. *Am J Roentgenol* 1954;72:754 – 761.
23. Preston CB. Pituitary fossa size and facial type. *Am J Orthod* 1979;75:259 – 263.

How to cite this Article: Vaishnav PD, Philip P, Shetty S, Mogra S, Batra P, Dhillon M. Sella turcica morphology- A diagnostic marker for skeletal class II malocclusion? *J Dent Specialities*, 2015;3(1):22-28

Source of Support: NIL

Conflict of Interest: None Declared