

Orthodontic molar intrusion with palatal implant: a case report

Rahul Gupta^{1*}, Payal Sharma², Piush Kumar³, Vikas Chauhan⁴

^{1,4}PG Student, ²Professor & HOD, ³Professor, Dept. of Orthodontics & Dentofacial Orthopaedics, I.T.S Centre for Dental Studies & Research, Muradnagar, Ghaziabad, Uttar Pradesh, India.

***Corresponding Author:**

Email: bonafied16rahul@gmail.com

Abstract

Patients with missing molars usually present with supraerupted antagonist molars, hampering rehabilitation by prosthesis. In such cases orthodontic intrusion of the supraerupted molar can be considered. There are several modalities for intrusion but active intrusion can be achieved by temporary anchorage devices or TAD's. Intraorally TAD's can be placed at various sites in the maxilla such as buccal alveolus, palatal alveolus and mid palatal region. Among these, palatal alveolus provides more favorable periodontium for stability of TAD's. This case report presents molar intrusion with a palatal implant.

Keywords: Molar intrusion; Palatal implant; Supraeruption; Missing molar.

Introduction

It is not uncommon to encounter supraerupted maxillary molars in dental practice. Most of times early loss of the mandibular first molar leads to extrusion of the opposing maxillary first molar into the edentulous space.⁽¹⁾ In such cases intrusion of the extruded molar prior to rehabilitation of the space with a prosthesis is often required.

Molar intrusion has been one of the difficult tooth movement in orthodontics. There are many indications for molar intrusion such as in patients with anterior open bite, vertical maxillary excess, supra-eruption of teeth due to missing opposing teeth etc. Various methods for molar intrusion have evolved in the field of modern orthodontics such as sectional mechanics,⁽²⁾ a removable appliance,⁽³⁾ a transpalatal bar,⁽⁴⁾ anchorage from mini screws,⁽⁶⁾ or magnets.⁽⁷⁾ The choice of treatment method depends on the periodontal condition, bone quality and patient's need.

Patient compliance for molar intrusion is not of utmost importance with alternative treatment modalities like temporary anchorage devices or TADs.⁽¹⁾ The present case report documents a case of molar intrusion using a palatal implant with a trans-palatal arch.

Case Report

A 22 year old female patient presented with a chief complaint of spacing in her anterior teeth. The clinical examination revealed a Class I incisor relationship on a skeletal Class II base with upper and lower anterior spacing, a normal overjet and overbite complicated by a mutilated occlusion due to a grossly carious lower right first molar and a supraerupted maxillary right first molar as shown in (Fig. 1). The profile was convex with protrusive lips.

The objectives of treatment were to consolidate upper and lower anterior spacing and intrusion of the upper right first molar to facilitate placement of prosthesis. Treatment plan included extraction of the root stumps of the lower right first molar and pre-adjusted edgewise fixed appliance (MBT .022 prescription). Molar intrusion was planned with a transpalatal arch and a palatal implant.

A microimplant of 1.3x8 mm was placed on the palatal mucosa between the upper right first and second molars shown in (Fig. 2). A trans-palatal arch was fabricated from 0.9 mm S.S wire to prevent palatal tipping of the crown of the first molar. A force of 150 grams was applied with an elastic chain from the lingual sheath of the first molar to the palatal implant (Fig. 3). 3mm of intrusion was achieved in 6 months as shown in (Fig. 4). Pre and post treatment cephalometric parameters are shown in (Table 1). Superimposition on palatal plane shows molar intrusion (Fig. 5). After debonding, the patient was referred for composite build-up of right maxillary central incisor and maxillary lateral incisors. Patient was given a temporary removable prosthesis while waiting for dental implant placement as shown in (Fig. 6).

Table 1: Pre and Post treatment cephalometric parameters

Parameters	Pre-treatment	Post-treatment
SNA	86°	85°
SNB	81°	80°
ANB	5°	5°
SN – GoGn	22°	23°
U1 to NA	30°	20°
LI toNB	39°	34°
U6 to NF	24mm	21mm

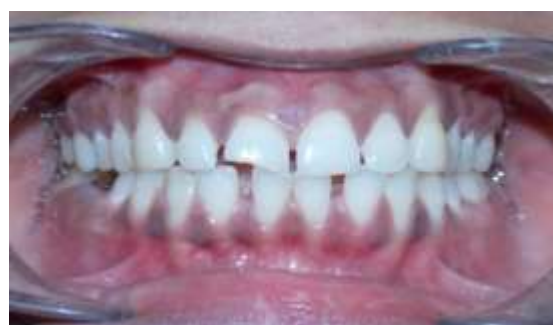

Fig. 1a: Intraoral pre-treatment photograph

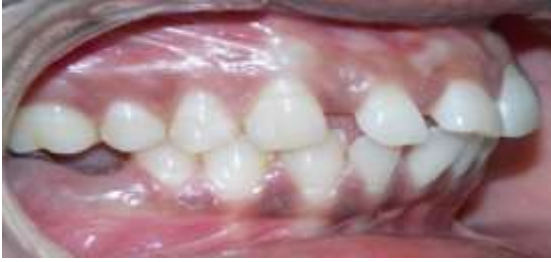

Fig. 1b: Intraoral pre-treatment photograph

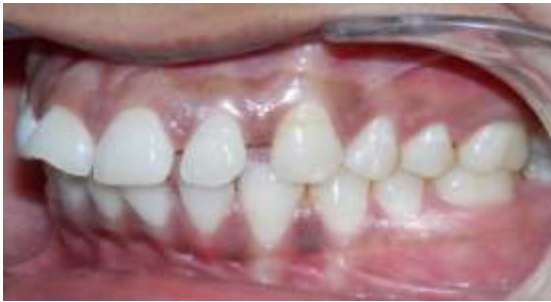

Fig. 1c: Intraoral pre-treatment Photograph

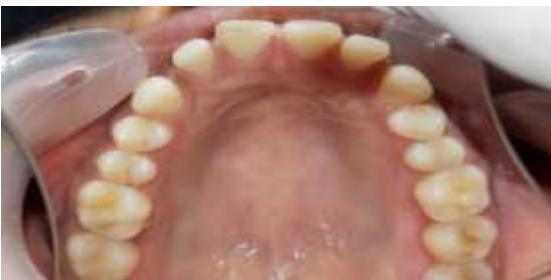

Fig. 1d: Intraoral pre-treatment photograph

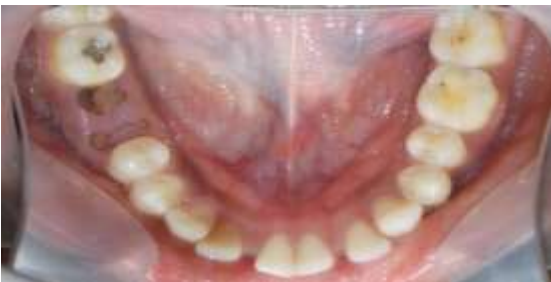

Fig. 1e: Intraoral pre-treatment photograph



Fig. 1f: Extraoral pre-treatment photograph



Fig. 1g: Extraoral pre-treatment photograph

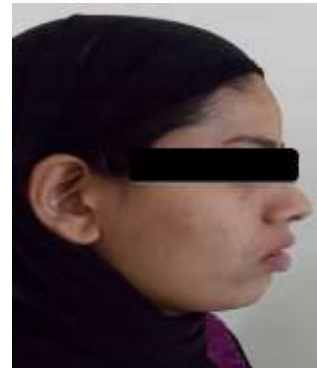

Fig. 1h: Extraoral pre-treatment photograph

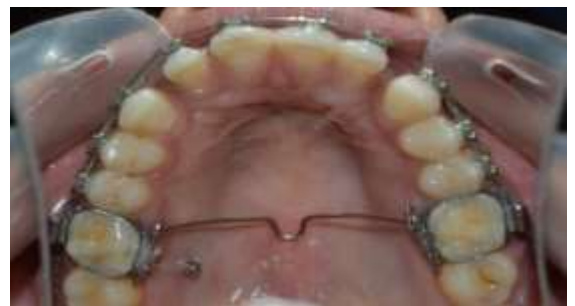

Fig. 2: TPA & palatal implant for molar intrusion

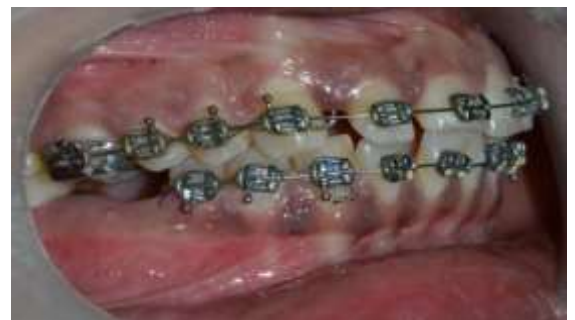

Fig. 3a: Treatment progress

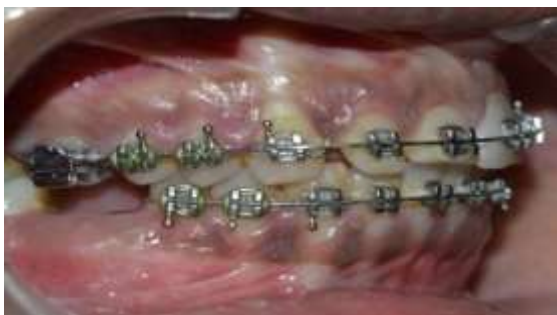

Fig. 3b: Treatment progress

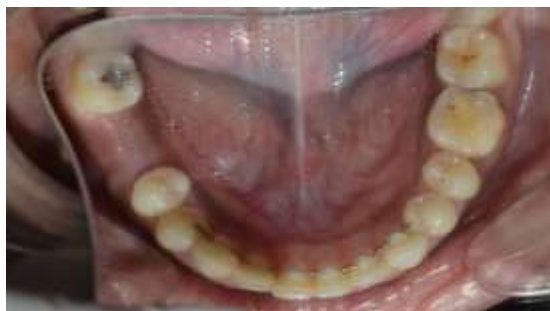

Fig. 4e: Intraoral post-treatment photograph

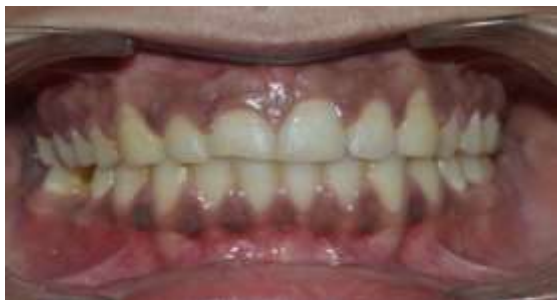

Fig. 4a: Intraoral post-treatment photograph

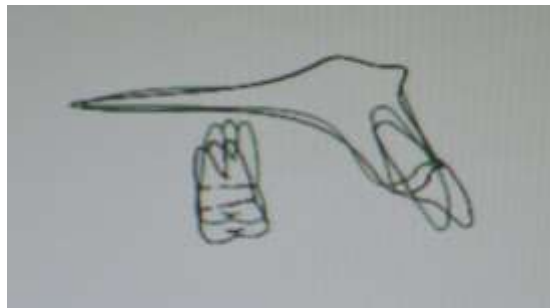


Fig. 5: Superimposition on palatal plane

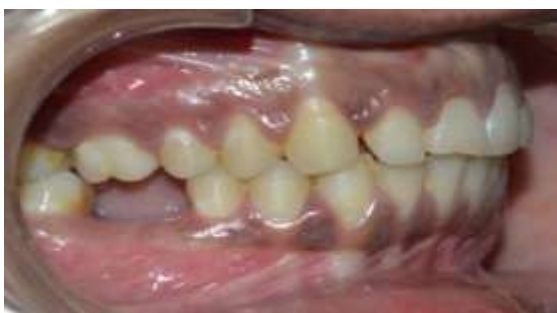

Fig. 4b: Intraoral post-treatment photograph

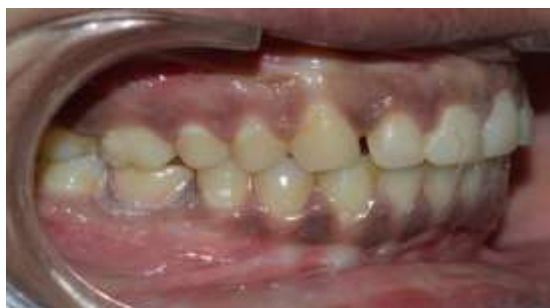

Fig. 6: Removable retainer with prosthesis

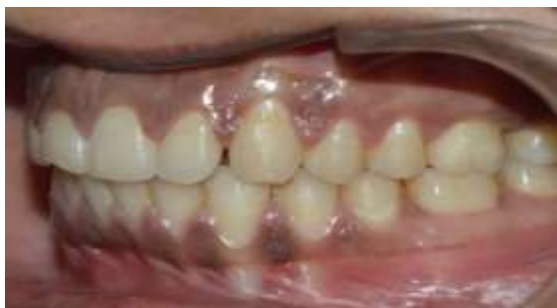

Fig. 4c: Intraoral post-treatment photograph

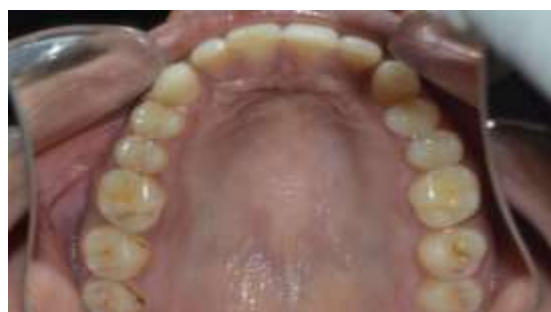

Fig. 4d: Intraoral post-treatment photograph

Discussion

Area with high bone density and thin keratinized tissue are good for mini-screw insertion. Patient's safety and biomechanical tooth movement are the two important criteria for determining the location of mini-screw. Bone density and soft tissue health are the key determinants that affect stationary anchorage and miniscrew success.⁽⁸⁾ Palatal alveolus was chosen for the placement of implant because the cortex is thicker on the palatal alveolus than the corresponding buccal side, and there is more interproximal space between the palatal roots. Thus, palatal alveolus has been recommended as insertion sites to be used for molar intrusion.⁽⁹⁾

We applied 150 g of force because intrusive force should be light and continuous to produce the appropriate pressure within the periodontal ligament and minimize the risk of root resorption.⁽¹⁰⁾ Melsen and Fiorelli used 50 g of force to intrude maxillary molars in adults.⁽²⁾ Park et al used 200 g of force for miniscrew-supported maxillary molar intrusion.⁽¹¹⁾

3mm of molar intrusion was achieved in 6 months. Yao et al reported a mean intrusion of 3 to 4 mm (range

3.68-8.67 mm) for the first molar and a mean intrusion of 1 to 2 mm for the second molar in 7.5 months.⁽¹²⁾

Conclusion

With miniscrews, orthodontist can overcome anchorage limitations and perform difficult tooth movements predictably and with minimal patient compliance. In adult patients, a multidisciplinary treatment may present a more conservative approach to rehabilitate the patient's occlusion. Restorative dentists, periodontists and surgeons should have some understanding of the many applications of orthodontics when presenting patients with options for correcting occlusal problems.

References

1. Kravitz ND, Kusnoto B, Tsay TP, Hohlt WF. The use of temporary anchorage devices for molar intrusion. *J Am Dent Assoc.* 2007;138(1):56-64.
2. Melsen, B, Fiorelli, G. Upper molar intrusion, *J Clin Orthod.* 1996;30:91-6.
3. Armbruster P, Sheridan JJ, Nguyen P. An Essix intrusion appliance. *J Clin Orthod.* 2003;37:412-16.
4. Enacar A, Pehlivanoglu M, Akcan CA. Molar intrusion with a palatal arch. *J Clin Orthod.* 2003;37:557-59.
5. Chung KR, Kim YS, Linton JL, Lee YJ. The miniplate with tube for skeletal anchorage. *J Clin Orthod.* 2002;36:407-12.
6. Kiliaridis S, Egermark I, Thilander B. Anterior open bite treatment with magnets. *Eur J Orthod.* 1990;12:447-57.
7. Miyawaki S, Koyama I, Inoue M, Mishima K, Sugahara T, Takano-Yamamoto T. Factors associated with the stability of titanium screws placed in the posterior region for orthodontic anchorage. *Am J Orthod Dentofacial Orthop.* 2003;124(4):373-78.
8. Cousley RR. A clinical strategy for maxillary molar intrusion using orthodontic mini-implants and a customised palatal arch. *J Orthod.* 2010;37:197-203.
9. Cousley RR. Intrusion and anterior open bite treatments. In *The Orthodontic Mini-implant Clinical Handbook*. Chichester: Wiley-Blackwell, 2013. pp.99-122.
10. Proffit WR. *Contemporary orthodontics*. 3rd ed. St. Louis: Mosby; 2000.
11. Park YC, Lee SY, Kim DH, Jee SH. Intrusion of posterior teeth using mini-screw implants. *Am J Orthod Dentofacial Orthop.* 2003;123(6):690-94.
12. Yao CC, Lee JJ, Chen HY, Chang ZC, Chang HF, Chen YJ. Maxillary molar intrusion with fixed appliances and mini-implant anchorage studied in three dimensions. *Angle Orthod.* 2005;75(5):754-60.