

Retreatment of mandibular canine with two roots: a case report

Mohit Kumar¹, Manju Kumari², Sonali Taneja³

^{1,2}Professor, ³Professor & HOD, Dept. of Conservative Dentistry & Endodontics, ITS Centre for Dental Studies & Research, Muradnagar, Ghaziabad, Uttar Pradesh, India

***Corresponding Author:**

Email: mohit_cusp@yahoo.co.in

Abstract

The successful outcome of the endodontic therapy requires an adequate knowledge in context to anatomy of the root canal system. In most cases, the mandibular canines are thought to have just one root canal. Those presenting with an extra root and canal are usually rare, ranging from 1% to 5%. Thus, in spite of this low prevalence, variations in the anatomy and number of root canals in mandibular canines should always be taken into account. This paper presents a case of a mandibular canine with two distinct and separate root canals.

Keywords: Endodontics, Mandibular Canine, Root Canal Anatomy

Access this article online
Website: www.innovativepublication.com
DOI: 10.18231/2393-9834.2016.0020

Introduction

The main objective of an endodontic therapy is to eliminate infective microflora from the root canal system.^{1,2} However, factors such as lack of adequate knowledge of root morphology and incomplete removal of infection from the root canal may lead to failure of endodontic treatment. The main causative factor in the failure of endodontic therapy is the failure to locate and fill a canal appropriately.³ A canal can be left untreated if its presence is not recognized. There is always a perception in the mind of the clinicians that a particular tooth will have a specific number of roots and /or canals. The variations in the root canal configuration of mandibular canines have been reported by many investigators.⁴⁻¹⁹ This paper reports a clinical case of mandibular canine with two roots.

Case Report

A 52-year-old female patient was referred to the post graduate clinic of the Department of Conservative Dentistry and Endodontics, I.T.S centre for Dental Studies and Research, Ghaziabad with severe pain in the left mandibular canine. The patient had undergone root canal treatment from a general dentist for the same tooth. At the time of examination, tooth was symptomatic. Intraoral examination revealed a normal crown anatomy with a temporary restoration on occlusal surface. The tooth was sensitive to percussion. Radiographic evaluation of the affected tooth revealed an over-extended root canal filling (Fig. 1). From the radiographic findings, it was diagnosed to be a case of

over-extended root canal filling and retreatment was planned for the pretreated canine. As the patient was traumatized and apprehensive because of her past experience, rubber dam application could not be accomplished.

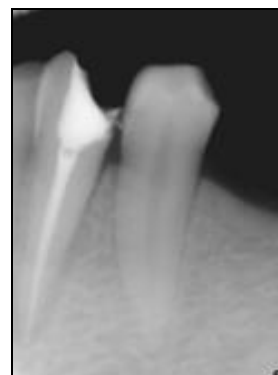

Fig. 1: Pre-operative radiograph showing overextended root canal filling

Endodontic retreatment of mandibular canine: The tooth was anaesthetized and temporary restoration was removed. The previous root canal filling was removed with the help of H-files (Dentsply/Maillefer, Ballaigues, Switzerland). A radiograph was obtained at this stage to confirm the complete removal of root canal filling. On careful examination of this radiograph, it was suspected that the mandibular canine had two separate roots and canals (Fig. 2). The access cavity was modified and the missed buccal canal was located. Working length was established using electronic apex locator (Root ZX; JMorita Co, Kyoto, Japan) and confirmed radiographically (Fig. 3). The canals were instrumented by rotary protaper system (Dentsply Maillefer) using crown-down technique. A 3% sodium hypochlorite (Prime dental products) along with 17% EDTA (Prime dental products) was used as irrigant at every change of instrument. The canals were dried and obturated with

Protaper guttapercha (Dentsply Maillefer) using AH plus sealer (Dentsply Maillefer). A post-operative radiograph was taken which showed dense root canal filling (Fig. 4).

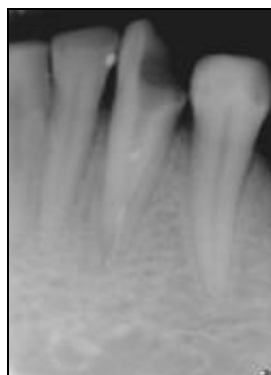

Fig. 2: Radiograph showing presence of two roots

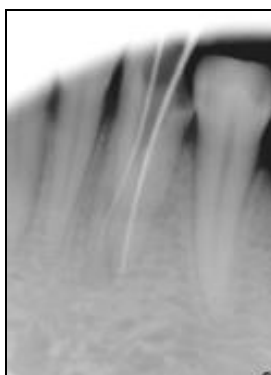


Fig. 3: Working length radiograph showing two separate roots and canals

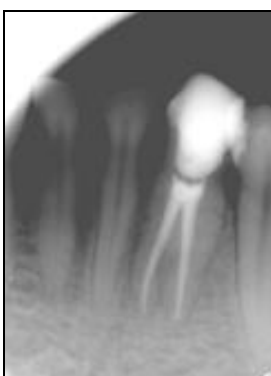

Fig. 4: Post-operative radiograph

Discussion

The morphological features of the root canal may adversely affect the outcome of endodontic procedure. A thorough knowledge of the root canal anatomy is an important aspect of root canal treatment and is extremely important for the highest possible chance of success. Inability to find and treat an additional root canal is the most widely recognized reason for the failure of root canal treatment. In the teeth especially with extra root canal or anatomical varieties, root canals

are regularly left untreated because the clinicians are unable to distinguish their presence. The presence of the additional canals can be found if the clinician is aware of the clues that suggest their presence. An exhaustive and cautious radiographic assessment and endodontic investigation may prompt recognizable proof or suspicion of extra canals. Radiographs taken from different angles and some with a file in place may be very useful in finding and locating extra canals. In the present case, an extra root canal was identified on marginally angulated radiograph. Therefore, the diagnostic radiograph should be carefully examined as it might indicate bifurcation or trifurcations. Despite the fact that the prevalence of the extra root canals inconsistencies is low, they should be distinguished via watchful examination. Detailed knowledge of the anatomical varieties in the endodontic system and attention to their arrangement is the key to success.

Conclusion

Endodontic success depends on the adequate debridement of the root canal system, as well as, on the knowledge of variations in the root canal anatomy. Mostly, mandibular canines are reported to have one root and root canal, but 15% of them are reported to have two canals, and a fewer number may have two distinct roots, both of which should be identified and managed.

References

1. Ng YL, Mann V, Rahbaran S, Lewsey J, Gulabivala K. Outcome of primary root canal treatment: systematic review of literature-part 2. Influence of clinical factors. *Int Endod J* 2008;41: 6-31.
2. Sjogren U, Hagglund B, Sundqvist G, Wing K. Factors affecting long term result of endodontic treatment. *J Endod* 1990;16(10):498-504.
3. Stewart GG. Evaluation of endodontic results. *Dent Clin North Am* 1967;11:711-22.
4. Pineda F, Kuttler Y. Mesiodistal and buccolingual roentgenographic investigation of 7275 root canals. *Oral Surg, Oral Med and Oral Pathol* 1972;33(1):101-10.
5. Green D. Double canals in single roots. *Oral Surg, Oral Med and Oral Pathol* 1973;35(5):689-96.
6. Vertucci FJ. Root canal anatomy of the human permanent teeth. *Oral Surg, Oral Med and Oral Pathol* 1984;58(5):589-99.
7. Heling I, Gottlieb-Dadon I, Chandler NP. Mandibular canine with two roots and three root canals. *Endod Dent Traumatol* 1995;11(6):301-2.
8. Holtzman L. Root canal treatment of a mandibular canine with three root canals. Case report. *Int Endod J* 1997;30:291-3.
9. Orgunseser A, Kartal N. Three canals and two foramina in a mandibular canine. *J Endod* 1998;24(6):444-5.
10. D' Arcangelo C, Varvara G, De Fazio P. Root canal treatment in mandibular canines with two roots: a report of two cases. *Int Endod J* 2001;34(4):331-4.
11. Nandwani S, Nandwani A. Endodontic treatment of mandibular canine with type II canal morphology: A case report. *J Conserv Dent* 2002;59:83-5.

12. Sikri V, Kumar V. Permanent human canines: Configuration and deviations of root canals: An *in-vitro* study. *J Conserv Dent* 2003;6:151-2.
13. Nandini S, Velmurugan N, Kandaswamy D. Bilateral mandibular canines with type two canals. *Indian J Dent Res* 2005;16:68-70.
14. Wang L, Zhang R, Peng B. Clinical features and treatment of mandibular canines with two root canals: Two case reports. *Chin J Dent Res* 2009;12:61-2.
15. Tyagi S, Tyagi P, Singh SK, Dwivedi V, Jaiswal H, Mishra P. Bilateral mandibular canine with two canals in one root. *Int J Dent Clin* 2013;5:29-30.
16. Arora V, Nikhil V, Gupta J. Mandibular canine with two root canals – An unusual case report. *Int J Stomatol Res* 2013;2:1-4.
17. Shrivastava N, Nikhil V, Arora V, Bhandari M. Endodontic management of mandibular canine with two canals. *J Int Clin Dent Res Organ* 2013;5:24-6.
18. Chou YH, Chang CW, Hung WC, Lin LH. The morphology variation of mandibular canine: Two cases report. *JES* 2013;4:31-6.
19. He LB, Shao MY, Xu X, Li JY. Bilateral mandibular canines with single root and multiple canals. *J Dent Sci* 2014;9:199-201.
20. Rijal S, Yadav A, Shetty K. Endodontic management of bilateral mandibular canines with an unusual root canal anatomy. *Saudi Endod J* 2015;5:46-50.