

## Christ siemen touraine syndrome - a case report

Shweta Singh<sup>1\*</sup>, Amit Kumar Singh<sup>2</sup>, Anmol Agarwal<sup>3</sup>, Payal Agarwal<sup>4</sup>

<sup>1</sup>Associate Professor, Dept. of Pedodontics & Preventive Dentistry, <sup>2</sup>Associate Professor, Azamgarh Dental College, Azamgarh, Uttar Pradesh, India, <sup>3</sup>Associate Professor, Dept. of Oral & Maxillofacial Surgery, Institute of Dental Studies & Technologies, Modinagar, Uttar Pradesh, India, <sup>4</sup>Consultant, Dept. of Dental & Craniofacial Care, Yashoda Super Specialty Hospital, Ghaziabad, Uttar Pradesh, India

**\*Corresponding Author:**

Email: singh.paedo@gmail.com

### Abstract

Christ Siemen Touraine (C.S.T) syndrome is characterised by classical triad of hypohidrosis, hypotrichosis and hypodontia. The oral manifestations are characteristic for this particular syndrome. It is necessary to identify this disease at its early stage in order to render prompt treatment. This article, presents a case report of a one year six month old boy, with C.S.T syndrome with various investigations like radiographic, dermatoglyphics, sweat pore count and treatment plan.

**Keywords:** Christ Siemen Touraine Syndrome, X-linked hypohidrotic ectodermal dysplasia, Dermatoglyphic.

### Access this article online

**Website:**

[www.innovativepublication.com](http://www.innovativepublication.com)

**DOI:**

10.18231/2393-9834.2016.0017

### Introduction

The National Foundation for Ectodermal Dysplasia (NFED) defines ectodermal dysplasia (ED) as a genetic disorder in which there are congenital birth defects (abnormalities) of 2 or more ectodermal structures. These structures may include skin, hair, nails, teeth, nerve cells, sweat glands, parts of the eye, ear and other organs<sup>1</sup>. Freire –Maia and Pinheiro described 117 possible varieties of ectodermal dysplasia involving all possible Mendelian modes of inheritance<sup>2</sup>. From the clinical point of view two main forms have been distinguished:

1. Hypohidrotic form/Christ -Siemens-Touraine Syndrome
2. Hidrotic type /Clouston syndrome

**Christ-Siemen-Touraine (CST) syndrome**, also referred to as hypohidrotic ectodermal dysplasia, belongs to a group of genodermatosis known as ectodermal dysplasia. The disorder hypohidrotic ectodermal dysplasia affects 1-7 per 100,000 live births<sup>3,4</sup>. This disorder is inherited as an X-linked trait. The hypohidrotic form is characterized by a triad of signs comprising sparse hair (hypotrichosis), abnormal or missing teeth (hypodontia or anodontia), and an inability to sweat because of the lack of sweat glands

(anhidrosis or hypohidrosis). In the oral cavity, the most striking feature is oligodontia. The teeth that are present have abnormal crown form. Teeth in anterior region of maxilla and mandible are conical in shape<sup>2</sup>. The inability to sweat may result in permanent brain damage or even death<sup>5</sup>, thus, early diagnosis and counselling of families are essential, including instructions for lowering the body temperature during hot weather or fever.

### Case Report

A one year, six months, old boy reported to the Department of Pedodontics and Preventive Dentistry, with a complaint of lack of eruption of teeth and two conical teeth in upper anterior region of jaw. On general physical examination, child was moderately built but poorly nourished. He had dry skin with scanty hair distribution on body. Extra oral examination revealed characteristic features such as sparse hair on the scalp and eyebrows, prominent frontal bossing and supraorbital ridges, a depressed nasal bridge (saddle nose), cup ear deformity and protuberant lips. He was also intolerant to heat and gives history of recurrent fever in summers. Intra oral examination revealed only two malformed incisors in maxillary arch and rest all teeth were missing in both the arches. The parents gave history of consanguineous marriage and they were first cousins. Family history regarding similar features was positive. The patient's maternal grandfather had similar features (Table 1). Various investigations like radiographic, dermatoglyphic investigation and sweat pore count were performed.

**Table 1: Clinical features of hypohidrotic ectodermal dysplasia<sup>6</sup>**

System involved	Clinical features
Skin	Hypohidrosis, anhidrosis, heat intolerance, fever, dry, cracked skin eczema, dermatitis
Hair	Hypotrichosis, dry, brittle, light coloured hair
Nail	Deformed, brittle, thin, ridged nails
Teeth	Hypodontia, anodontia, delayed dentition, wide spaced, pointed, discoloured teeth
Facial features	Frontal bossing, saddle nose, malar hypoplasia, mandibular hypoplasia
Otolaryngologic features	Hypoplastic alae nasi, atrophic rhinitis, ozena, Pharyngitis, laryngitis, laryngeal mucous hyposecretion, vocal cord palsy, voice changes
Ophthalmic features	Dry eyes, corneal dryness, pannus, vascularisation and scarring, ankyloblepharon, blepharitis, trichiasis, loss of eyelashes and eyebrows, malformed meibmian glands
Respiratory features	Asthma, recurrent infections
Gastrointestinal features	Feeding difficulties, recurrent vomiting, and chronic diarrhoea
Immune dysfunction	Depressed lymphocyte function, cellular immune hypofunction, increased susceptibility to recurrent nasal and respiratory infections Allergic conditions as asthma, eczema, pruritus

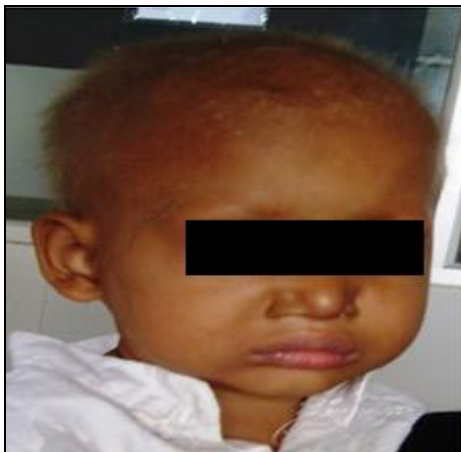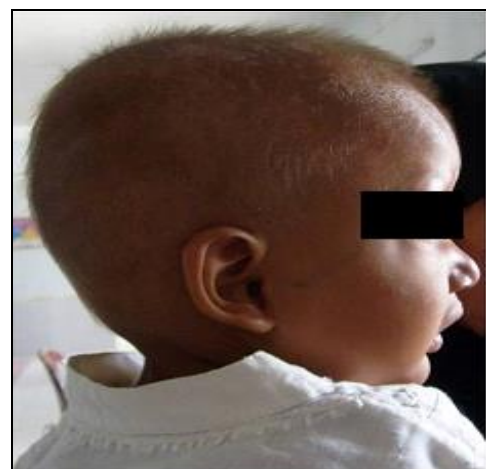**Radiographic findings:** An Orthopantomogram was attempted, but due to lack of patient's cooperation could not be made. Full mouth intraoral periapical radiograph revealed oligodontia.

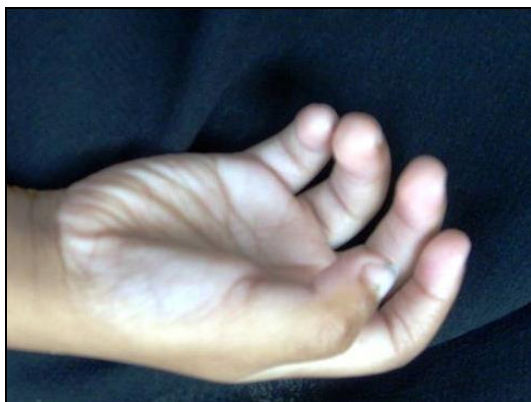
**Dermatoglyphic analysis by Cumin and Midlo's method<sup>7</sup> revealed (Table 2):** Three arches on the finger tips of the patient. The finger ridge pattern was dissociated in the mother, which is characteristic. The axial triradius angle in the father left palm was 50 degrees, which is a major variant from normal cases.

**Table 2: Dermatoglyphic Record & sweat pore count**

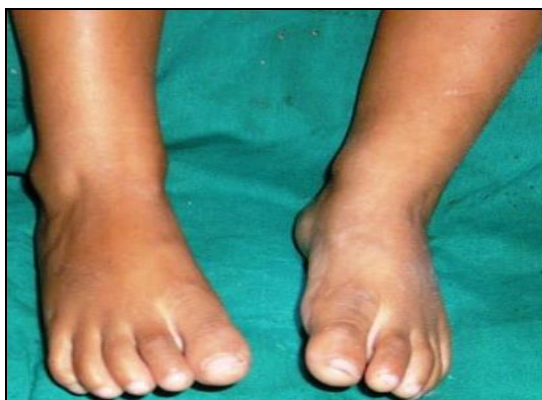	Finger print pattern	Finger ridge pattern	Atd angle	Fluctuating asymmetry in atd angle	Sweat pore count Number/cm <sup>2</sup>
Patient	LT-ALLLL RT-LAALL	Continuous	40° 42°	2°	10
Patient mother	LT-LLLLL RT-WLALL	Dissociated	34° 35°	1°	11
Patient Father	LT-LLLLL RT-LLLLL	Continuous	50° 44°	6°	12

**Sweat pore count revealed (Table 2):** The sweat pore count in 1 cm<sup>2</sup> of the palm of the patient, his mother and father were 9, 11 and 12 respectively, which was on the lower side of normal count.

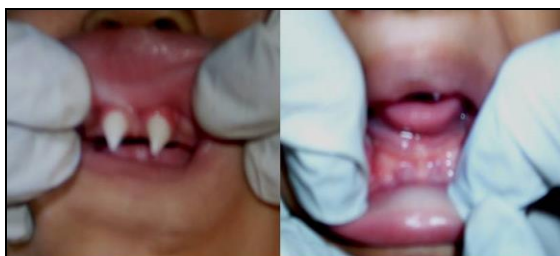
**Fig. 1: Facial view of the patient****Fig. 2: Profile view of the patient**



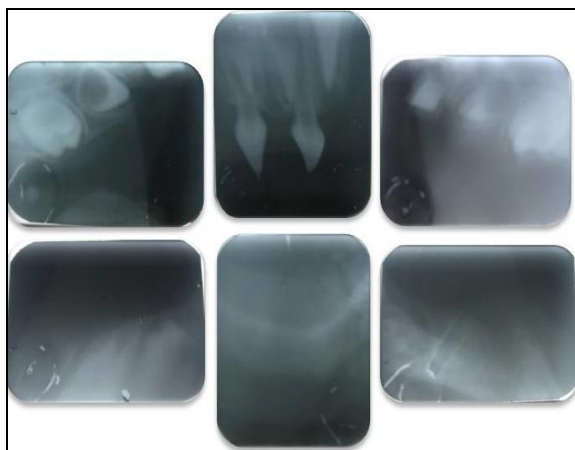
**Fig. 3: Scaly skin**



**Fig. 4: Dry skin**



**Fig. 5 & 6: Intra oral view of the patient**



**Fig. 7: Full month IOPA radiographs of patient**

## Discussion

Diagnosis was not just based on clinical triad, but also on family history, radiographic findings, dermatoglyphic findings, sweat pore counts which all were suggestive of C.S.T syndrome. Often in hereditary disease like Turner disease and Down syndrome, palmar and plantar ridges may be abnormal, which is also true for diseases involving skin appendages<sup>8</sup>. Another basis for considering dermatoglyphics as a genetic marker for ectodermal dysplasia is that both primary palate and finger bud develop around the same time i.e., during 6<sup>th</sup>-13<sup>th</sup> week of intrauterine life. Both are ectodermal in origin and develop from the same site<sup>9</sup>. Genetic message contained in the genome normal or abnormal is deciphered during this period and is reflected by dermatoglyphic.

The word Dermatoglyphic was coined by Cummins and Midlo in 1926, meaning dermi-skin and glyphe -carving<sup>7</sup>. The method of recording dermatoglyphics in the present study was ink stamp method and for palm record, duplicating ink was used. Dermatoglyphic pattern are broadly classified into three major types: whorl, loop and arches. These patterns are present on finger buds/tips, whereas whole of human palm show certain other features such as axial triradius (ATD) angle, H loop, IV Loop, and t-triradius. In the present case finger print pattern, finger ridge pattern and ATD angle were compared with the normal values.

On a genetic level, in ectodysplasia, defect in signal transduction pathways are the basis of the syndrome. Epithelial cells in hair follicles, endocrine sweat glands and developing teeth use this pathway during morphogenesis. Therefore, genetic defects result in aplasia, hypoplasia or dysplasia of these structures. They also lead to disturbances in the enamel matrix and tooth buds and subsequent hypodontia and hypoplasia of teeth<sup>11</sup>. Kargul B et al. also reported striking dermatoglyphic finding in patients of ectodermal dysplasia<sup>11</sup>.

The reduced sweat pore count from the normal individuals explains heat intolerance in these patients. Frias and Smith<sup>5</sup> found a total absence of sweat pores in affected males in their study which is supporting the findings in our case.

Treatment of a child with ectodermal dysplasia requires a multidisciplinary approach. An individual affected by Hereditary Ectodermal Dysplasia, is prone to hyperthermia, hence, advised to maintain cool surrounding temperature with air conditioning, light clothing, plenty of fluids and avoiding direct sunlight. Topical emollients are required for dry eczematous skin and dermatological consultation for infective and allergic skin conditions. Alopecia can be managed by using wigs for cosmetics. The feeding difficulties due to maldevelopment of teeth and malabsorption due to mucosal inflammation may affect the growth of the child. This would require prompt evaluation by gastroenterologist and a dietician for nutritional advice.

Speech and language therapist, otolaryngologist and respiratory physician play a major role in vocal development and treatment of chronic respiratory conditions. Genetic counseling may be helpful to the entire family and helps in preventing further consanguineous marriages. Dental treatment depends on the severity of the disorder; therefore, treatment varies according to age, growth and development of the stomatognathic system of the patient<sup>12</sup>. In the present case, considering the child age and expected cooperation level, no dental treatment was done. Successful management of these children can be achieved by following means<sup>13</sup>

1. Making the child accustomed to the dental operatory.
2. Establishing a friendly relationship with the child.
3. The dentist should have complete knowledge for handling the special problems associated with the treatment.
4. Providing interdisciplinary approach.
5. A “tell show do” approach
6. By using materials and techniques which require minimum intraoral working time and which do not produce any unpleasant reaction in the mouth.
7. By educating the patient and parents about continuous follow up appointments needed for prosthesis adjustment and replacement.

Till and Marques<sup>14</sup>, recommend initial prosthesis be delivered before the child begins school, so that the child has the time to adapt to it. According to Gukes *et al*<sup>15</sup> child’s consciousness for self-image fairly completes by 4-5 yrs. Early intervention provides the child the opportunity to develop normal forms of speech, chewing, swallowing, improved temporomandibular joint function and most importantly improved self-esteem. As the child grows, the denture should be relined and rebased to accommodate for the growth. Once the growth is complete, the acrylic dentures may be replaced by fixed type of prosthesis using osseointegrated implants.<sup>16</sup>

## Conclusion

Dentists are often the first, who diagnose the patients. Therefore, they should be aware of the clinical manifestations of this syndrome. This will be helpful in proper diagnosis, early interventions and appropriate therapies for these patients.

## References

1. Hickey AJ, Vergo TJ. Prosthetic treatments for patient with ectodermal dysplasia. *J Prosthet Dent* 2001; 86(4):364-8.
2. Suprabha BS. Hereditary ectodermal dysplasia: Case report. *J Ind Soc Pedod Prev Dent* 2002; 20(1):37-40.
3. Mc Kusick VA. Mendelian Inheritance in Man. 12<sup>th</sup> ed. Baltimore: Johns Hopkins University Press; 1998. p. 3307-3309.
4. Buyse ML. Birth defects encyclopedia. St Louis: Blackwell Scientific Publications; 1990. p. 597-8.

5. Frias JL, Smith DW. Diminished sweat pores in hypohidrotic ectodermal dysplasia: a new method for assessment. *J Pediatr* 1968; 72(5):606-10.
6. Tyagi P, Tyagi V, Hashim AA. Ocular and non-ocular manifestations of hypohidrotic ectodermal dysplasia. *BMJ Case Rep* 2011.
7. Cummins H. Study of error in interpretation and formulation of palmar dermatoglyphics. *Am J Phy Anthr* 1928; 11:501-21.
8. Sidhu M, Kale AD, Kotrashetti VS. Karyotyping, dermatoglyphic, and sweat pore analysis of five families affected with ectodermal dysplasia. *J Oral Maxillofac Pathol* 2012; 16(3):380-7.
9. Mathew L, Hegde AM, Rai K. Dermatoglyphic peculiarities in children with oral clefts. *J Ind Soc Pedod Prev Dent* 2005; 23(4):179-82.
10. Balci G, Baskan SZ, Akdenizi S. Ectodermal dysplasia: Report of four cases and Review of Literature. *International Dental and Medical Disorders* 2008; 1:56-9.
11. Kargül B, Alcan T, Kabalay U, Atasu M. Hypohidrotic ectodermal dysplasia: Dental, clinical, genetic and dermatoglyphic findings of three cases. *J Clin Pediatr Dent*. 2001; 26(1):5-12.
12. Guilford SH. Dental Anomaly. *Dental Cosmos* 1883; 25:113.
13. Jain V, Prakash H. Prosthodontic rehabilitation for ectodermal dysplasia patients. *J Ind Soc Pedod Prev Dent* 2000; 18(2):54-8.
14. Till MJ, Marques AP. Ectodermal dysplasia: treatment considerations and case reports. *Northwest Dent* 1992;71(3):25-8.
15. Guckes AD, Brahim JS, McCarthy GR, Rudy SF, Cooper LF. Using endosseous dental implants for patients with ectodermal dysplasia. *J Am Dent Assoc* 1991; 122(10):59-62.
16. Paschos E, Huth KC, Hickel R. Clinical management of hypohidrotic ectodermal dysplasia with anodontia: case report. *J Clin Pediatr Dent* 2002; 27(1):5-8.