

Assessment of Langerhans cells using modified ATPase histochemistry technique: a pilot study

Arushi Pandey^{1,*}, Nirmala N Rao², Gurkiran Kaur³

¹Professor & Head, College of Dental Sciences & Hospital, Indore, Madhya Pradesh, India, ²Dean & Professor, Manipal College of Dental Sciences, Manipal, Karnataka, India, ³Reader, Dept. of Oral Pathology, PDM Dental College & Research Institute, Bahadurgarh, Haryana, India

***Corresponding Author:**

Email: roshipandey@yahoo.co.in

Abstract

Introduction: Langerhans cells are dendritic bone marrow derived cells situated suprabasally in most stratified squamous epithelia and behave as very potent antigen presenting cells. Routine Hematoxylin and Eosin staining cannot localize them in the epithelium, thus immunofluorescence or immunohistochemical techniques are employed.

Aim and Objectives: To develop a technique for staining Langerhans cells in tissues which is equally specific and sensitive while being relatively inexpensive in comparison to the contemporary techniques.

Materials and Method: The study was carried out in the oral pathology laboratory with post graduate teaching requirements. It mainly included a cryostat other than the routine set up equipment. The study included twenty histopathologically confirmed cases of Oral Lichen Planus (OLP). Four serial sections of each tissue were stained with Hematoxylin & Eosin (H&E) stain, ATP-lead substrate, control (absence of Adenosine triphosphate salt) and Masson's Fontana stain and observed under the microscope for presence of Langerhans cells. A modified method for staining, to observe Langerhans cells, given by Juhlin L and Shelly WB was used.

Results: All twenty cases showed positive staining using the modified technique. The cells which were typified as Langerhans cells, were those with round/ovoid brown stained cells showing the presence of minimum of 2-3 dendritic processes from the cell surface. ATPase activity was found more localized in the cell membrane and dendrites.

Conclusion: The modified histochemistry technique for identifying Langerhans cells was found to be highly sensitive and specific, as well as, very cost effective.

Keywords: ATPase; Histochemistry; Langerhans cells; Special stains.

Access this article online

Website:

www.innovativepublication.com

DOI:

10.18231/2393-9834.2016.0011

Materials and Method

The biopsy specimens were obtained from patients after an informed consent and institution ethical committee approval. Twenty punch biopsies were obtained from patients with confirmed Oral Lichen Planus (OLP), after taking a written informed consent. All biopsies were obtained from the right buccal mucosa region.

The soft tissue specimens washed in phosphate buffered saline and transferred to Michel's transport media were sent to the laboratory. No specimens were retained for more than two weeks before processing.

The basic method for staining was same as that given by Juhlin L and Shelly WB, 1977. This method has been used by several workers to identify Langerhans cell in normal mucosa⁸⁻¹³ and diseased conditions.¹⁴ The steps had to be modified because of two reasons:

1. The reagent mentioned is not available in pure form in India, thus their strength and their time of action has been modified keeping in mind the shelf life of the chemical.
2. Climatic conditions vary here as compared to that in the west, thus, the incubation time and temperature had to be modified.

It was ensured that all the modifications resulted in highly specific and sensitive staining of the Langerhans

Introduction

Langerhans cells are dendritic bone marrow derived cells situated suprabasally in most stratified squamous epithelia that behave as very potent antigen presenting cells that activate mainly the helper T lymphocytes.¹

Several techniques, like immunohistochemistry and immunofluorescence, have been employed to identify the various surface markers present on Langerhans cells.²⁻⁶ Based on the histochemical observation that they possess on their surface, high levels of enzyme(s) like nucleotide triphosphatase, a number of studies have been performed utilizing this specific enzyme marker. As the usual substrate for this enzyme is adenosine triphosphate (ATP), it is commonly identified as ATPase.⁷ The technique used in this study utilizes this enzyme for the identification of Langerhans cells.

cells. Some controversy exists regarding the specificity of the cell surface ATPase marker for identification of Langerhans cells, as well as its expression by melanocytes. Therefore, in the present study, serial sections of the mucosal specimens were stained using Masson's Fontana stain, to serve as controls. This helped to differentiate melanocytes and melanin incontinence from the basally placed Langerhans cells, thus avoiding the over counting of cells.

Solutions used in the study

1. Phosphate Buffer Solution (PBS)

(i)	Potassium dihydrogen phosphate solution	6.8 gm/l
(ii)	Disodium hydrogen phosphate solution	7.1 gm/l

Working solution

1.	Potassium dihydrogen phosphate	100 ml
2.	Disodium hydrogen phosphate	300 ml
3.	Distilled water	1600 ml
4.	Sodium chloride	17.4 gm

Adjust pH to 7.2

2. Transport Media – Michel's media

Solution A

1.	1M Citrate buffer	2.5 ml
2.	0.1M Magnesium sulphate	0.06 gm
3.	0.1M Ethylmelemide	0.06 gm
4.	Distilled water	97.5 ml

Working solution:

1.	Solution A	100 ml
2.	Ammonium sulphate	55gm

Adjust the pH to 7.2

3. Fixative solution – 4% Paraformaldehyde in 0.1M Cacodylate Buffer Stock solution

Solution A

1.	Dissolve 8 gm paraformaldehyde in 100 ml distilled water by heating to 60°C with continuous stirring. This should be done in a fume cabinet and the beaker should be covered to avoid evaporation.
2.	Add 1M sodium hydroxide dropwise with stirring until the solution clears; 5-8 drops should be sufficient.
3.	Cool under running cold water.

Solution B

1.	Mix 50 ml of 0.2M sodium cacodylate and 2.7 ml of 0.2 M hydrochloric acid. Check the pH and adjust to 7.4, if necessary.
2.	Add 1.0 ml of 0.5M calcium chloride dropwise with agitation (optional).
3.	Add 1.5 g sucrose.

Final solution: The fixative is prepared by mixing solution A with solution B in the ratio of 1:1.

Note: Although this fixative does not deteriorate quickly, it is preferable to use it when fresh.

4. Stains – Adenosine tri phosphatase - Lead Method [Juhlin L and Shelly WB, 1977]

ATP-lead substrate

1.	Adenosine triphosphate disodium salt	5'	50 mg
2.	Glucose		5 gm
3.	Distilled water		50 ml
4.	Trisml buffer		40 ml (see below)
5.	Magnesium sulphate		10 ml 0.1M (i.e. 1.2%)

Trisml Buffer

1.	Tris buffer salt	1gm
2.	Maleic acid	6 gm
3.	Sodium hydroxide	4.0 gm
4.	Distilled water	400 ml

Final ATP-lead substrate solution

- 2.7 ml stock ATP solution
- 0.3 ml 2% lead nitrate in distilled water

Note: Final solution to be always prepared fresh for each case.

5. Developer – 1% Ammonium sulphide solution

1.	Ammonium sulphide solution	0.5 ml
2.	Distilled water	4.5ml

Note: Developer should be prepared fresh for every use as ammonium sulphide degrades very fast.

6. Counterstain – Methyl Green-Pyronin [Jordon and Bakers Method]

1.	0.5% Aqueous Pyronin Y	37 ml
2.	0.5% Aqueous methyl green	13 ml
3.	Acetate buffer (pH 4.8)	50 ml

7. Mountant

Glycerol + PBS

A mixture of glycerol and PBS was taken in ratio of 1:1.

8. Distilled water for washes.

9. Routine Hematoxylin & Eosin Stain

10. Masson's Fontana Special stain

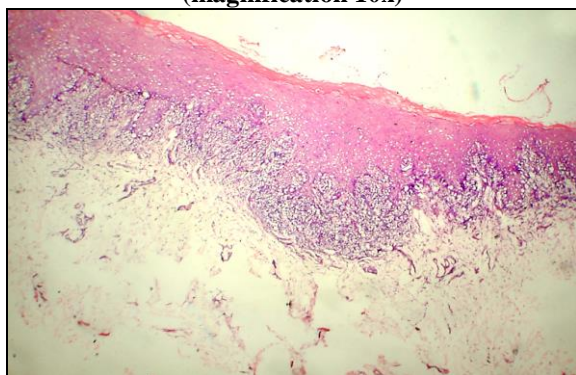
i.	Silver solution: To 25ml of 10% aqueous silver nitrate add strong ammonia drop by drop until the precipitate which forms has almost disappeared, then add 25ml of distilled water. This solution should be left for 24 hours, stored in a dark bottle and filtered before use. It is better to renew this solution after 14 days, but it may be used for a month.
ii.	3% Sodium thiosulphate solution
iii.	Neutral Red

Methodology

1. The biopsy specimens collected in the Michel's media were washed in Phosphate buffered saline for 30 minutes.
2. The specimen before sectioning were properly oriented in Optimum Cutting Temperature (OCT) compound, and frozen upon a pre-cooled chuck at -25°C in the cryostat.
3. $8\mu\text{m}$ thickness frozen sections were cut on a LEITZ cryostat at -25°C and 4 serial sections were picked up onto a set of four Poly-L-lysine coated slides (A,B,C,D) respectively.

Slide A – Routine hematoxylin-eosin stain

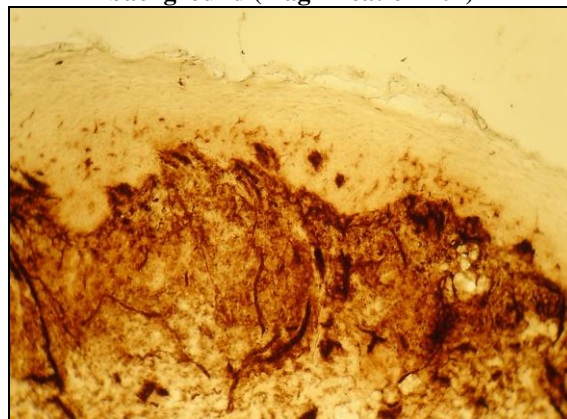
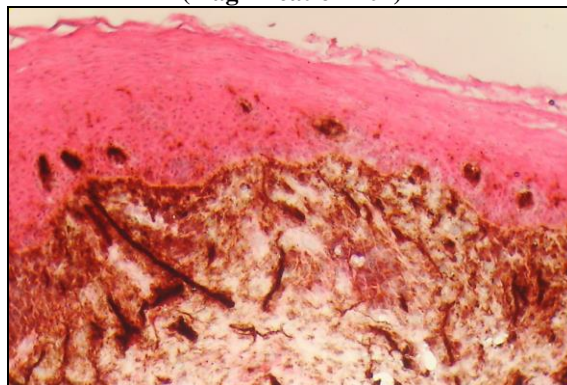
1. Sections were air dried.
2. Then they were brought to water and stained with the routine Hematoxylin and Eosin stain.
3. Mounted the sections in DPX / Canada balsam.
4. Photomicrographs taken (Photomicrograph 1)

Photomicrograph 1: Hematoxylin and Eosin stained section showing classical features of lichen planus (magnification 10x)**Slide B – ATP-Lead stain**

1. Sections were air dried for 15 minutes.
2. Sections were fixed for 20 minutes at 4°C in 4% paraformaldehyde-cacodylate buffer.
3. Rinsed in distilled water for 1 minute.
4. Sections were then incubated in ATP-Lead substrate for 1 hour in a humid chamber at 37°C .
5. Wash the sections thoroughly in cold distilled water for 2 minutes.

6. Sections were then treated with 1% ammonium sulphide solution for 5 minutes.
7. Wash thoroughly in distilled water for 2 minutes.
8. Counterstained with methyl green pyronin for 2-5 minutes.
9. Counterstain was washed with chilled distilled water.
10. Sections were then air dried.
11. Mounted in Glycerol + PBS and observed.
12. Counting of Langerhans cells was done
13. Photomicrographs taken.


Note: ATPase stained sections cannot be kept for long as the black deposits of lead sulphide formed as the end product within the cells degrades rapidly losing its color. Langerhans cells were observed as brown stained ovoid cells with dendritic extensions against a golden yellow background (Photomicrograph 2). Keratinocytes were stained pink after the counter stain (Photomicrograph 3).

Photomicrograph 2: ATP-Lead stained section showing dark brown stained dendritic Langerhans cell's towards the basal layer in a golden yellow background (magnification 10x)**Photomicrograph 3: ATP-Lead stained section with Pyronine counterstain showing brown dendritic Langerhans cells in a pink background (magnification 10x)**

Slide C – Control slide

1. The sections were treated in the same way as for slide B, except that the ATP-lead substrate used for the incubation was without the Adenosine triphosphate salt. This slide was used as a negative control to compare with the test slides.
2. Photomicrographs taken (Photomicrograph 4).

Photomicrograph 4: Control section (without Adenosine triphosphate salt) showing absence of staining (magnification 10x)

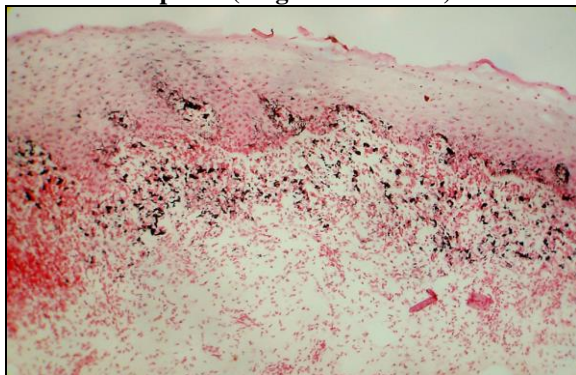


Note: Sections remain unstained.

Slide D – Masson's – Fontana stain

1. Bring the frozen sections to water.
 2. Transfer to silver solution in a covered container and leave it in the dark for 18- 48 hours at room temperature.
 3. Rinse in several changes of distilled water.
 4. Fix in 3% sodium thiosulphate for 2 minutes.
 5. Wash in running tap water for 2 minutes.
 6. Counter stain with neutral red for 3 minutes.
 7. Wash in tap water for half a minute.
 8. Dehydrate, clear and mount in DPX / Canada balsam.
 9. Photomicrographs taken (Photomicrograph 5).
- Thus, over counting of the Langerhans cells was avoided.

Photomicrograph 5: Masson's Fontana stained section (to differentiate between melanocytes and Langerhans cells) showing melanocytes and melanin incontinence as brown – black dendritic cells and deposits (magnification 10x)

**Results**

In all 20 study cases, the Langerhans cells stained positively with the modified ATPase staining technique. Langerhans cells were identified as dendritic brownish cells seen clearly lying dispersed among the keratinocytes. These cells can be clearly differentiated from melanocytes and melanin incontinence by comparing with the sections stained with Masson's Fontana stain. The counting of the Langerhans cells was done based on the following criteria: round/ovoid brown stained cells showing the presence of a minimum of 2 -3 dendritic processes from the cell surface, having an average size of 5.5–7 microns, the cytoplasm of these cells was relatively less intensely stained, ATPase activity was found more localized in the cell membrane and dendrites, which appeared brownish to brownish black in color and anastomoses between the dendrites of adjacent Langerhans cells were not seen.

The slides stained with Masson's Fontana stain were viewed in a similar manner as the ATPase stained slides to avoid melanocytes and melanin deposits from being counted as basally placed Langerhans cells, thus, preventing over counting.

Discussion

The aim of preparing this staining methodology was to find a sensitive, specific and cost effective staining technique which could be used routinely in place of immunohistochemistry. In the present study, the activity of the specific enzyme marker, adenosine triphosphatase (ATPase) on the surface of Langerhans cell has been demonstrated using enzyme histochemistry. The presence of ATPase enzyme is suggestive of transmembrane transfer mechanism that indicate the intercellular interactions between Langerhans cell, altered keratinocytes and lymphocytes.^{7,15} Another role of this enzyme proposed, was that at sites of inflammation, nucleotides such as ATPs, released by dying cell, function as signaling molecules through P2 receptors present on the Langerhans cells. The formation of ATP gradients at the site of inflammation might transiently delay the migration of these local dendritic cells, thereby, prolonging the time of antigen encounter.¹⁶

Some controversy exists regarding the specificity of the cell surface ATPase marker for identification of Langerhans cells, as well as its expression by melanocytes. Therefore, in the present study, serial sections of the mucosal specimens were stained using Masson's Fontana, to serve as controls. This helped to differentiate melanocytes and melanin incontinence from the Langerhans cells, thus avoiding the over counting of cells.

The storing of all the reagents are at room temperature, except that of prepared Michel's media and of Cacodylate Crystals which are at 8 degree centigrade (refrigerator below ice chamber).The shelf life of all the reagents is long, the only exception being

that of ammonium sulphate solution (precaution is to tightly close the lid of reagent bottle after use and use one bottle within 30 days once the reagent is opened.

Conclusion

Enzyme histochemistry provides a useful adjunct to immunofluorescence and immunohistochemical methods for the identification of Langerhans cells. The modified histochemistry technique to detect ATPase positive Langerhans cells used in the present study was found to be highly sensitive and specific as well as cost effective which can be easily carried out in routine oral pathology laboratory.

Reference

1. Ahlfors EE, Larsson PA, Bergstresser PR. Langerhans cell surface densities in rat oral mucosa and human buccal mucosa. *J Oral Pathol* 1985;14:390-7.
2. Chen H, Yuan J, Wang Y, Silvers WK. Distribution of ATPase-positive Langerhans cells in normal adult human skin. *Br J Dermatol* 1985;113:707-11.
3. Cruchley AT, William DM, Farthing PM, Lesch CA, Squire CA. Regional variation in Langerhans cell distribution and density in normal oral mucosa determined using monoclonal antibodies against CD1, HLADR, HLADQ and HLADP. *J Oral Pathol Med* 1989;18:510-6.
4. Daniels TE. Human mucosal Langerhans cells: Postmortem identification of regional variations in Oral Mucosa. *J Invest Dermatol* 1984;82:21-4.
5. Waterhouse JP, Squier CA. The Langerhans cells in human gingival epithelium. *Arch Oral Biol* 1967;12:341-8.
6. Chou MJ, Daniels TE. Langerhans cells expressing HLA-DQ, HLA-DR and T6 antigens in normal oral mucosa and lichen planus. *J Oral Pathol Med* 1989; 18:573-6.
7. Farthing PM, Matear P, Cuchley AT. The activation of Langerhans cells in oral lichen planus. *J Oral Pathol Med* 1990;19:81-5.
8. Hedberg NM, Hunter N. The expression of HLA-DR on keratinocytes in oral lichen planus. *J Oral Pathol* 1987;16:31-5.
9. Ishii T. Immunohistochemical demonstration of T cell subsets and accessory cells in oral lichen planus. *J Oral Pathol* 1987;16:356-61.
10. Sloberg K, Jonsson R, Jontell M. Assessment of Langerhans cells in oral lichen planus using monoclonal antibodies. *J Oral Pathol* 1984;13:516-24.
11. Lombardi T, Hauser C, Budtz JE. Langerhans cells: structure, function and role in oral pathological conditions. *J Oral Pathol Med* 1993;22:193-202.
12. Walsh LJ, Seymour GJ, Powell RN. The regulation of Langerhans cell T6, DR and DQ antigen expression: a hypothesis. *J Oral Pathol* 1988;17:43-6.
13. Wolff K, Winkelmann RK. Quantitative studies on the Langerhans cell population of Guinea pig epidermis. *J Invest Dermatol* 1967;48(6):504-13.
14. Shelly WB, Juhlin L. Selective uptake of contact allergens by Langerhans cells. *Arch Dermatol* 1977;113:187-92.
15. Wolff K, Winkelmann RK. Ultrastructural localization of nucleoside triphosphate in Langerhans cells. *J Invest Dermatol* 1967;48(1):50-4.
16. Schnurr M, Toy T, Stoitzner P, Cameron P, Shin A, Beecroft T, et al. ATP gradient inhibit the migratory capacity of specific human dendritic cell types: implication of P2Y11 receptor signaling. *Blood*. 2003;102(2):613-20.