



Case Series

Nonsurgical endodontic retreatment: A series of four case reports

Mohit Zarekar^{1*}, Apurva Satpute², Mohini Zarekar³¹Dept. of Paedodontics & Preventive Dentistry, Private Practice, Maharashtra, India²Dept. of Conservative Dentistry & Endodontics, Govt. Dental College & Hospital, Chhatrapati Sambhajinagar, Maharashtra, India³Institute of Tropical Medicine, Charité Universitätsmedizin Berlin, Germany

ARTICLE INFO

Article history:

Received 02-10-2023

Accepted 13-12-2023

Available online 20-09-2024

Keywords:

Endodontic retreatment

Periapical lesion

Nonsurgical

Inadequate obturation

ABSTRACT

The primary objective of endodontic treatments or any pulp therapy is to maintain the integrity and health of oral tissues. Endodontic treatments aim to disinfect and shape the root canal system completely and obturate it in 3D to prevent reinfection. Although initial root canal therapy has high success rates, failures can occur. The term 'retreatment' denotes a new intervention to retain the tooth in the oral cavity. Nonsurgical endodontic retreatment can preserve previously treated teeth with persistent periapical lesion(s), if the tooth is restorable and periodontally sound, and patient wants to keep it. The clinician and patient should select the treatment with the best long-term outcome. This case series describes endodontically treated teeth that required nonsurgical endodontic retreatment due to inadequate obturation, persistent periradicular lesion and loss of coronal seal.

This is an Open Access (OA) journal, and articles are distributed under the terms of the [Creative Commons Attribution-NonCommercial-ShareAlike 4.0 License](#), which allows others to remix, tweak, and build upon the work non-commercially, as long as appropriate credit is given and the new creations are licensed under the identical terms.

For reprints contact: reprint@ipinnovative.com

1. Introduction

Endodontic treatment is a prevalent procedure within the field of dentistry. Nevertheless, the existing literature provides limited discussion on the topic of retreatment. There are multiple factors that contribute to endodontic failure, with leakage being identified as a prevalent contributor.¹ Clinicians and patients may experience perplexity, worry, and frustration as a result of endodontic failures. Several questions arise when considering retreatment, such as whether to damage the previous restoration to access root canals. Whether retreatment is necessary because of radiographic unsatisfactoriness, and whether fillings can improve after retreatment.^{1,2} These questions might affect case selection in endodontics.³ Various causes have been identified through clinical observation as contributing to the failure of endodontic

procedures. The etiological factors encompass coronal leakage, fractures, errors in diameter, length, and direction during post-placement, missing canals, inadequate filling lengths, excessive filling lengths with insufficient internal filling, blockages, ledges, perforations, root canal transportation, and fractured endodontic files; also, periodontally involved teeth. All causes result in leakage and endodontic failure.^{3,4}

Several studies assessed the technical quality of root fillings radiographically, assuming it might affect the treatment outcome. However, it is necessary to identify the features and patterns that could impact the technical quality, especially in nonsurgical retreatments. Most of the teeth indicated for re-root canal therapy have their roots canals obturated and restored, which makes retreatment different from primary treatment.⁴ The effect of study characteristics and clinical factors on retreatment outcome has not been systematically investigated. Such

* Corresponding author.

E-mail address: zarekarmohit@gmail.com (M. Zarekar).

information would help clinical decision making on re-treatment options.⁵

The main objective of endodontic retreatment is to cleanse root canals from irritants, mostly microorganisms that survived or infiltrated the canals after previous treatment. Since retreatments involve repeating the steps of root canal therapy with biological rationale, they are advocated whenever possible.⁶ This series of case reports shows the need for retreatments due to coronal leakage and improper obturation.

2. Case Report

2.1. Case 1

A male patient, aged 27, without any underlying systemic conditions, came with mild discomfort during mastication specifically on the right mandibular first molar. The tooth underwent endodontic therapy around eight months ago. The clinical examination revealed the presence of a satisfactory composite repair, the patient experienced severe soreness upon percussion, and no response was observed during the cold test. The tooth movement and presence of periodontal pockets were not readily apparent. The tooth exhibited a draining sinus on its buccal surface. The initial radiograph displayed radiolucency at the apical region of both the mesial and distal roots, as well as in the furcation area. Additionally, three root fillings were observed to have inadequate radiopacity, specifically two in the mesial roots and one in the distal root (Figure 1A). Based on these findings, the patient was diagnosed with chronic apical periodontitis. Following a comprehensive assessment of symptoms, clinical observations, and radiographic analysis, it was determined that instead of opting for an apicoectomy, the choice was made to retreat the root canals after obtaining patient's informed consent.

Following the administration of 1 ml of local anaesthesia (Septanest, Septodont) and the subsequent isolation of the area with a rubber dam, the occlusal filling was removed. A total of four canal orifices were identified and verified using operating microscope (OPMI pico Dental Microscope, Zeiss). The removal of gutta-percha was accomplished through the utilisation of retreatment rotary files, specifically the HyFlex™ REMOVER (COLTENE) (Figure 1B). The determination of working length was conducted using an apex locator (Root ZX, J. Morita Inc, USA) and afterwards verified through radiographic examination (Figure 1C). The canals were prepared using manual hand k-files (Dentsply, Maillefer, USA) and RaCe NiTi rotary files in a crown-down technique, with a size of #0.06/25 for the distal canals and #0.06/20 for the mesial canals. The canals were irrigated using a solution consisting of 2.5% sodium hypochlorite (NaOCl) and 17% Ethylenediaminetetraacetic acid (EDTA). The application of intracanal medicine, specifically calcium hydroxide (CH)

paste was applied. Access cavity was closed with a cotton pellet and a temporary cement Cavit (3M ESPE). Patient was scheduled for next visit after 1 week.

After 1 week, the tooth was asymptomatic and the temporary filling was intact. Following the administration of local anaesthesia and the placement of a rubber dam for isolation, the temporary cement and cotton pellet were extracted from the access cavity. The use of 2.5% NaOCl in combination with ultrasound activation and negative apical pressure, facilitated by the EndoVac system, effectively eliminated the CH paste present in the root canal. The experimental procedure concluded with a final rinse utilizing a solution of 17% EDTA for a duration of 1 minute. Canal was dried with a paper point and obturated with Gutta-percha mastercones and DIA-ROOT BIO (DiaDent) bioceramic sealer using the lateral compaction method (Figure 1D). Patient was recalled after one week for complete coverage restoration.

2.2. Case 2

A 23-year-old male reported dull pain in lower right mandibular first molar and discomfort when chewing for 8 months after endodontic treatment. The occurrence of episodic swelling was first observed around four months ago, followed by subsequent deflation. The coronal restoration of the patient was lost four months prior, resulting in the exposure of the root filling to the oral environment. The biting test and percussion test yielded positive results upon objective inspection. The intraoral periapical radiograph revealed evidence of an incompletely filled root canal and the presence of periapical radiolucency (Figure 2A). Under patient's informed consent, endodontic retreatment started with anesthesia and rubber dam placement followed by redefining access cavity. Gutta percha removal was accomplished through the utilisation of GP Cleanse (Deor) solvent and retreatment rotary files (Figure 2B), working length determination and biomechanical preparation followed the same protocol as previous case by using hand k-files (Dentsply, Maillefer, USA) and RaCe NiTi rotary files in a crown-down technique. The canals were irrigated using a solution consisting of 2.5% NaOCl, 2%, Chlorhexidine (CHX), and 17% EDTA, with the liquids being subjected to ultrasonic activation. The process of disinfection using calcium hydroxide was conducted, followed by the application of a coronal seal using Cavit. (3M ESPE). One week later, the canals were re-entered and CH paste was removed by using 2.5% NaOCl, 2% CHX, and 17% EDTA and obturated with gutta-percha mastercones and bioceramic sealer by using the lateral compaction method of obturation (Figure 2C). The patient was recalled after 1 week for permanent restoration. Follow up of 6 months showed considerable reduction in periapical lesion (Figure 2D).

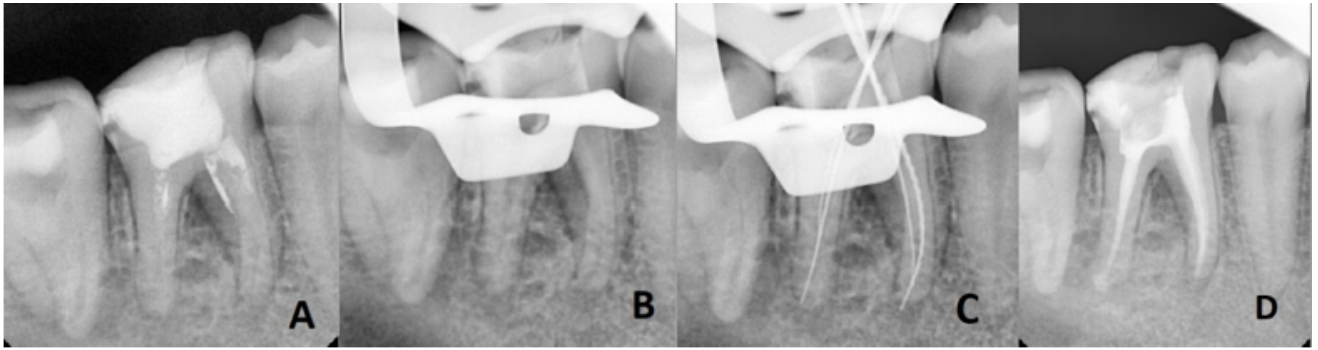


Figure 1: Case 1: **A):** Preoperative intraoral periapical radiograph; **B):** Removal of gutta percha from the canals; **C):** Estimation of working length; **D):** Immediate postoperative radiograph

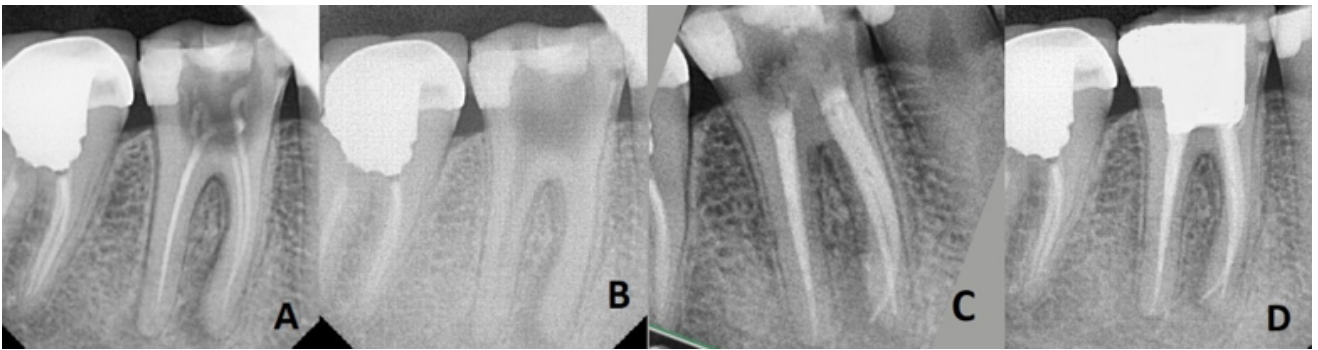

Figure 2: Case 2: **A):** Preoperative radiographic image; **B):** Removal of gutta percha from canals; **C):** Postoperative radiograph; **D):** 6 months follow up radiograph

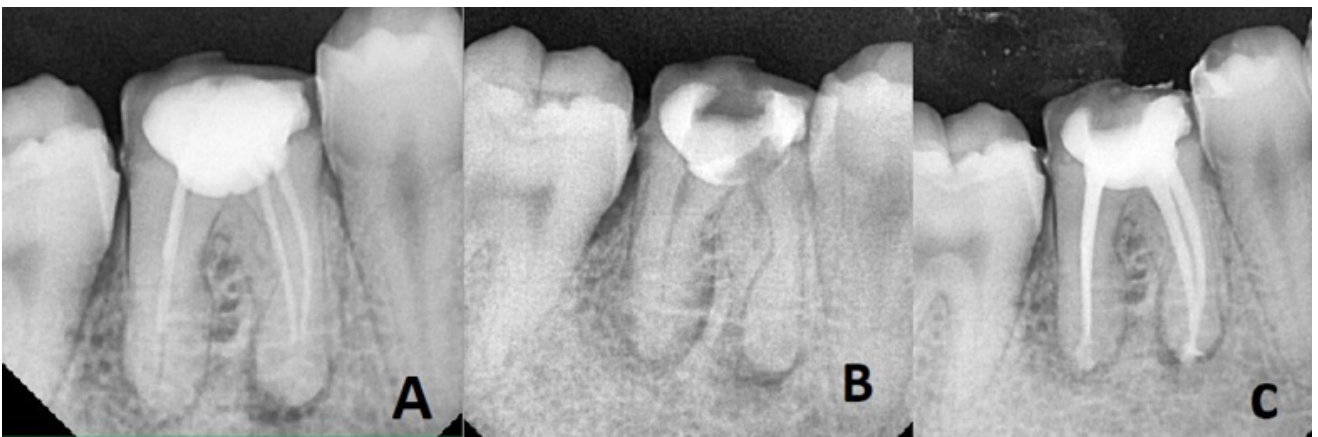

Figure 3: Case 3: **A):** Preoperative Radiograph; **B):** After gutta percha removal; **C):** Post obturation image

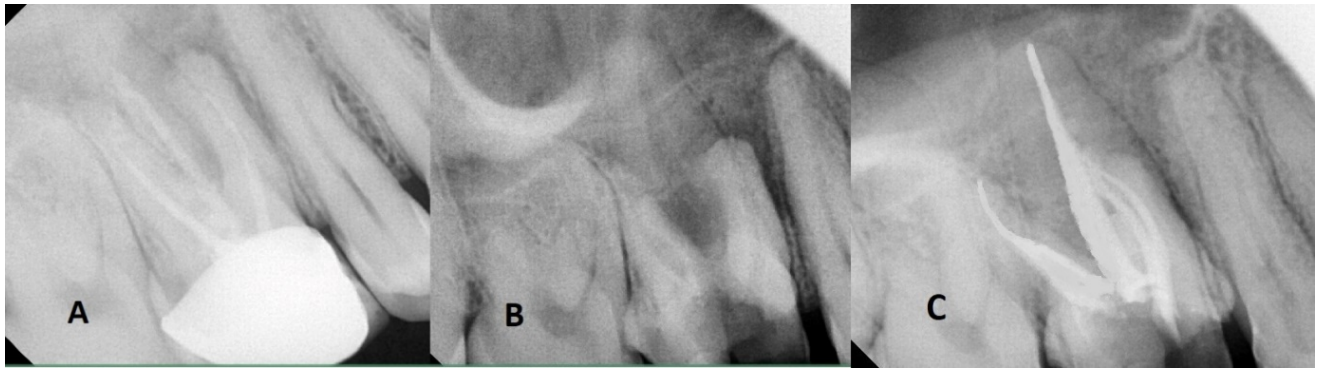


Figure 4: Case 4: **A):** Preoperative radiographic image; **B):** Gutta percha removal from canals; **C):** Post obturation

2.3. Case 3

A 36-year-old female patient complained of persistent extra-oral fistula and episodic intra-oral swelling in the area of her right mandibular first molar. The patient was healthy and had no chronic diseases. The clinical examination revealed significant coronary restoration, swelling at the apex, and positive findings on percussion and palpation. The results of the pulp vitality tests yielded unfavorable outcomes. The periapical radiographic examination revealed the presence of incompletely sealed canals containing gutta-percha with the observation of a uniform drumstick-like thickening of the middle and apical third of the roots suggestive of hypercementosis along with periapical radiolucency (Figure 3A). The findings were discussed with patient with all possible risk, discomfort, prognosis and cost. The decision was made to perform nonsurgical endodontic retreatment after obtaining the informed consent. After anesthesia and rubber dam placement, coronal restoration was removed and access cavity was redefined. Gutta percha removal accomplished by the utilisation of GP Cleanse (Deor) solvent and retreatment rotary files (Figure 3B), working length determination and biomechanical preparation followed the same protocol as previous cases with K-type files and RaCe NiTi rotary files in a crown-down technique. Canals were irrigated with 2.5% NaOCl, 2% CHX, and 17% EDTA during biomechanical preparation. Calcium hydroxide intracanal dressing was maintained for 15 days.

During the follow-up appointment, the patient indicated the absence of any symptoms. The obturation procedure employed the utilization of gutta-percha cones and bioceramic sealer, utilizing the vertical compaction approach (Figure 3C). The patient was provided with comprehensive information and subsequently scheduled for prosthetic rehabilitation.

2.4. Case 4

A 32-year male reported severe pain and swelling in the right maxillary posterior region. An intra-oral examination showed a porcelain fused to metal (PFM) crown with tooth no. #16 and mucosal edema corresponding to the apex. The tooth had been treated endodontically 2 years ago. Preoperative radiograph of tooth #16 showed incomplete obturation of the canals with well-defined lesion associated with mesial root and loss of lamina dura (Figure 4A). Careful radiographic examination revealed missed Mesiobuccal-2 canal in previous endodontic treatment. Based on clinical signs and radiographic examination, patient was convinced for nonsurgical endodontic retreatment after explaining the protocol. Other interdisciplinary treatment options were ruled out. With informed consent from the patient, retreatment procedure was started.

After anesthesia and rubber dam isolation, PFM crown was removed using automated crown remover (GDC Fine Crafted Dental Pvt. Ltd.), occlusal filling was removed and access was regained. GP Cleanse (Deor) solvent was used to soften the gutta-percha before using retreatment files. Gutta percha removal was accomplished using retreatment rotary files (Figure 4B), working length determination followed the same protocol as case 1. The canals were prepared with K-type files and RaCe NiTi rotary files in a crown-down technique. Canals were irrigated with 2.5% NaOCl, 2% CHX, and 17% EDTA. Intracanal calcium hydroxide dressing was given and coronal seal was performed with Cavit (3M ESPE) for 2 weeks. In the next visit, the tooth was asymptomatic and temporary filling was intact. After assessment of master cones, canals were obturated by lateral condensation technique with gutta-percha and bioceramic sealer (Figure 4C).

3. Discussion

Endodontic retreatment requires addressing a series of challenges that may be morphological or iatrogenic,

such as underextended access cavity, filling materials or foreign objects.^{1,7} Root canal morphology should be evaluated further during treatment by radiographs at different angulations to detect variations in maxillary and mandibular molars. An unusually large coronal morphology should alert the dentist during clinical and radiographic examination. Magnifying loops, fiber optic illumination, sodium hypochlorite bubbling and dyes can help in detecting extra canals. Cone beam computed tomography and operating microscopes can also assist in assessing the internal or external morphology and visualization.^{8,9} Periapical radiolucencies can endure as a result of various factors, including intraradicular infection stemming from coronal or apical leakage, inadequate root fillings, incomplete biomechanical preparation, or substandard root canal treatment. Other potential causes include extraradicular infections, foreign body reactions, contamination of gutta percha and paper points, the presence of true cysts, or the formation of fibrous scar tissue. Torabinojad et al. (2009) conducted a comparison between surgical and nonsurgical retreatment approaches. The results indicated that endodontic surgery exhibited a greater success rate (77.8%) after a 2-4-year period, as compared to non-surgical endodontics (71.9%). However, the success rate of endodontic surgery decreased to 71.8% after 4-6 years, whilst non-surgical endodontics demonstrated a higher success rate of 83% within the same time frame. Kvist T et al (2014) conducted an epidemiological investigation to assess and compare the efficacy of non-surgical and surgical retreatment strategies. There was no statistically significant disparity observed in the success rates between surgical and non-surgical retreatment procedures. Nevertheless, it is recommended to choose for non-surgical retreatment in cases where previous endodontic treatments have failed, as surgical retreatment has been associated with higher levels of postoperative discomfort, trauma, and complications.¹⁰

The process of endodontic retreatment is characterized by its laborious nature and significant time investment, which consequently increases the likelihood of encountering procedural errors. The process of selecting cases for endodontic retreatment necessitates a meticulous assessment of the prognosis of the tooth. The period of time also holds significant importance in the process of selecting cases. Various approaches have been implemented for the purpose of eliminating filling materials from root canals. These include endodontic hand files, Nickel Titanium rotary instruments, Gates Glidden burs, heated instruments, ultrasonic instruments, lasers, and solvents. Apical extrusion of debris during retreatment procedure might cause postoperative pain and discomfort. The current study employed a Rotary retreatment instrument, which demonstrated a reduced extrusion of apical debris compared to hand files. This outcome may be attributed to the triangular cross section of the

retreatment files, which effectively decreases the surface area of contact between the instrument and the dentin walls.^{10,11}

Chronic abscesses might cause no pain or minimal pain, which sometimes makes the patient unaware of the condition or symptoms.¹² Nonsurgical retreatment is needed to overcome failure and achieve favorable outcomes.¹³ Prior to commencing an endodontic retreatment, it is imperative to gather comprehensive data regarding the initial root canal treatment and the radiography records of the specific tooth in question. This is essential in order to identify any potential anomalies within the root structure.¹⁴ Since nonsurgical retreatment is the first line of treatment in previously done endodontic treatment, this option was chosen for the above case reports, which can be maintained for long duration or even for lifetime.

4. Conclusion

The utilization of training, practice, and technology can enhance the proficiency of physicians in conducting nonsurgical retreatments, hence offering a viable therapy approach to address the inadequacies of prior endodontic procedures. Nevertheless, it is imperative to conduct meticulously planned prospective studies in order to evaluate the outcomes of the initial and subsequent root canal therapy at a more comprehensive and sophisticated level. By adhering to a methodical approach, the dentist can effectively arrive at a well-informed conclusion regarding the most suitable treatment for such cases. This will help prevent instances of incorrect case selection, which can lead to ineffective treatment and avoidable failures.

5. Source of Funding

None.

6. Conflict of Interest

None.

References

1. Ruddle CJ. Nonsurgical endodontic retreatment. *J California Dent Assoc.* 1997;25(11):769–96.
2. Friedman S, Stabholz A. Endodontic retreatment-case selection and technique. Part 1: criteria for case selection. *J Endod.* 1986;12(1):28–33.
3. Signor B, Blomberg LC, Kopper PM, Augustin PA, Rauber MV, Rodrigues GS, et al. Root canal retreatment: a retrospective investigation using regression and data mining methods for the prediction of technical quality and periapical healing. *J Appl Oral Sci.* 2021;29:e20200799. doi:10.1590/1678-7757-2020-0799.
4. Stabholz A, Friedman S. Endodontic retreatment-case selection and technique. Part 2: treatment planning for retreatment. *J Endod.* 1988;14(12):607–14.
5. Ng YL, Mann V, Gulabivala K. Outcome of secondary root canal treatment: a systematic review of the literature. *Int Endod J.* 2008;41(12):1026–46.

6. Allen RK, Newton CW, Brown CE. A statistical analysis of surgical and nonsurgical endodontic retreatment cases. *J Endod.* 1989;15(6):261–6.
7. Mandel E, Friedman S. Endodontic retreatment: a rational approach to root canal reinstrumentation. *J Endod.* 1992;18(11):565–9.
8. Torre F, Cisneros-Cabello R, Aranguren JL, Estévez R, Velasco-Ortega E, Segura-Egea JJ, et al. Single-rooted maxillary first molar with a single canal: endodontic retreatment. *Oral Surg Oral Med Oral Pathol, Oral Radiol Endodontology.* 2008;106(6):66–8.
9. Eskandarinezhad M, Ghasemi N. Nonsurgical endodontic retreatment of maxillary second molar with two palatal root canals: a case report. *J Dent Res Dent Clin Dent Prospects.* 2012;6(2):75–8.
10. Kapoor V, Paul S. Non-surgical endodontics in retreatment of periapical lesions-two representative case reports. *J Clin Exp Dent.* 2012;4(3):189–93.
11. Kasam S, Mariswamy AB. Efficacy of different methods for removing root canal filling material in retreatment-an in-vitro study. *J Clin Diagn Res.* 2016;10(6):6–10.
12. Mãia LM, Toubes KM, Júnior GM, Tonelli SQ, Machado VDC, Silveira FF, et al. Guided endodontics in nonsurgical retreatment of a mandibular first molar: a new approach and case report. *Iran Endod J.* 2020;15(2):111–6.
13. Kahler B. Microsurgical endodontic retreatment of post restored posterior teeth: A case series. *Aust Endod J.* 2010;36(3):114–21.
14. Magnucki G. Endodontic Retreatment of Maxillary Second Molar with Four Roots. *Case Rep Dent.* 2019;doi:10.1155/2019/5348048.

Author biography

Mohit Zarekar, Private Practice  <https://orcid.org/0000-0002-5101-896X>

Apurva Satpute, Junior Resident  <https://orcid.org/0009-0000-7011-5581>

Mohini Zarekar, Student  <https://orcid.org/0009-0001-3425-8240>

Cite this article: Zarekar M, Satpute A, Zarekar M. Nonsurgical endodontic retreatment: A series of four case reports. *J Dent Spec* 2024;12(2):167-172.