

# Use of Temporalis Fascia as an Interpositional Arthroplasty in Temporomandibular Joint Ankylosis – A Case Report

Kumar RA<sup>1</sup>, Kumar S<sup>2</sup>, Rastogi S<sup>3</sup>, Kukreja P<sup>3</sup>

## Abstract

Temporo-mandibular joint (TMJ) ankylosis is an extremely disabling affliction that causes problems in mastication, digestion, speech, appearance and hygiene. Surgery of TMJ ankylosis needs careful evaluation and planning to yield predictable results. Ankylosis may be corrected surgically by an array of procedures like gap arthroplasty, joint reconstruction and interpositional arthroplasty. Though many types of autogenous grafts and alloplastic materials are available for the interpositioning, the temporalis muscle graft offers significant advantages like ease of harvesting, minimal donor site morbidity and effective coverage of the arthroplasty site.

**Key Words:** Temporo-mandibular Joint Ankylosis, Interpositional Arthroplasty, TMJ Surgery, Temporalis Muscle, Temporal Fascia.

## Introduction

Ankylosis of the temporomandibular joint (TMJ) involves fusion of the mandibular condyle to the base of the skull. When it occurs in a child, it can have devastating effects on the future growth and development of the jaws and teeth.<sup>1</sup> Furthermore, in many cases it has a profoundly negative influence on the psychosocial development of the patient, because of the obvious facial deformity, which worsens with growth.<sup>2</sup> Trauma and infection are the leading causes of ankylosis. However, in a young patient, a joint injury may not be noticed immediately. The first sign of a significant problem may be increasing limitation of jaw opening, usually noticed by the dentist. Pain is uncommon. Early diagnosis and treatment are crucial if the

worst sequelae of this condition are to be avoided. Optimal results can be achieved only after a complete assessment and development of a long-term treatment plan.<sup>3</sup> We present a case report of TMJ ankylosis diagnosed and successfully treated in the early teen years.

## Case Report

The male patient aged 12 years reported to the Department of Oral and Maxillofacial Surgery with chief complaint of limited mouth opening and difficulty in chewing since 7 years. On examination he had roundness and fullness, absence of condylar movement on left side. The preoperative interincisal mouth opening ranged between 5 mm with deviation of mandible towards left side (Fig. 1). CBCT showed enlargement of

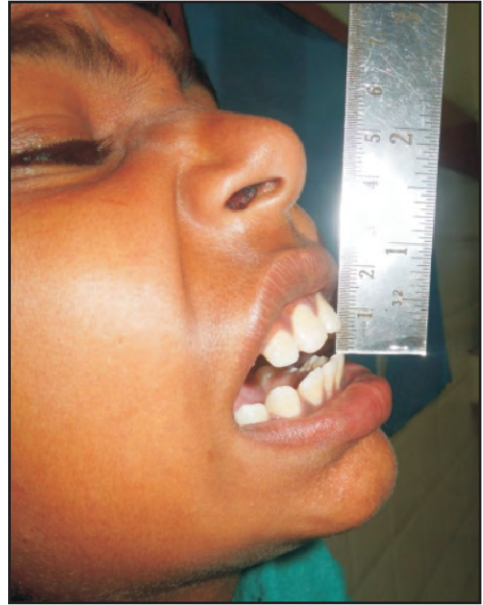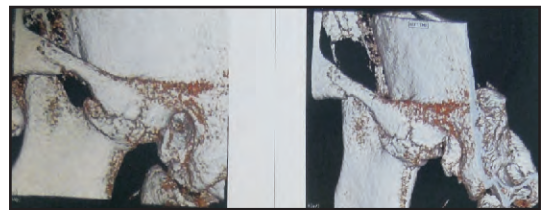
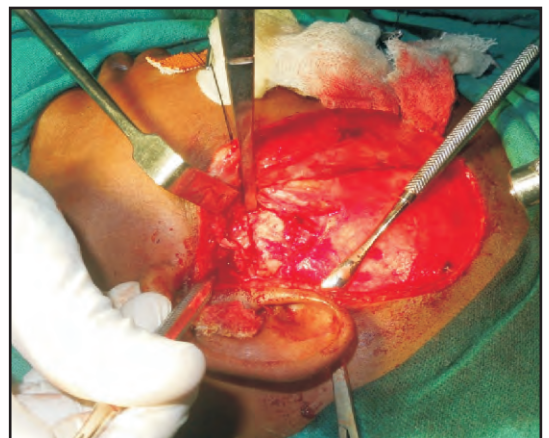
**Corresponding Author :** Dr. Kumar Rakshak Anand, Senior Lecturer, Dept of Oral & Maxillofacial Surgery, ITS CDSR, Muradnagar, Ghaziabad. (M)9711410024 E-mail : gr8doctor41@gmail.com

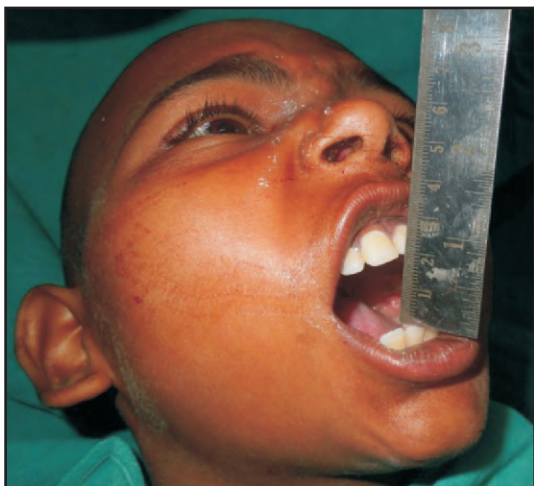1. Senior Lecturer, Dept of Oral & Maxillofacial Surgery, ITS CDSR, Muradnagar, Ghaziabad.

2. Professor & Head, Dept of Oral & Maxillofacial Surgery, ITS CDSR, Muradnagar, Ghaziabad.

3. Readers, Dept of Oral & Maxillofacial Surgery, ITS CDSR, Muradnagar, Ghaziabad.

temporal and condylar components of left TMJ with an anterior exophytic condylar bone mass causing partial obliteration of left sigmoid notch (Fig. 2). Patient was operated using interpositional arthroplasty with temporalis fascia through Al-Kayat Bramley approach. The procedure was carried out under general anesthesia by fiberoptic nasotracheal intubation. Temporal head shave was done prior to surgery, after skin preparation. Al-Kayat and Bramley modified preauricular incision with temporal extension was placed and dissection was carried out in the subcutaneous plane to reach the superficial temporal fascia. After dissection of superficial temporal fascia with careful attention to superficial temporal artery, the dissection was carried in the loose areolar tissue, with care to the facial nerve. After reaching the zygomatic arch, the ankylotic mass was explored, after placement of a T-shaped incision, a minimum gap of 1.5 cm was created. The cut end of the ramus and glenoid area was smoothed using burs. The maximal interincisal opening was more than 34 mm, hence coronoidectomy was not required. The TMJ was lined using a combined temporalis muscle and fascia flap. We chose 6-7 cm as length and 2-3 cm as the width of the flap, however, the length of the flap was based on the requirement of the joint space (Fig. 3). The flap was rotated over the zygomatic arch and the flap was sutured medially, anteriorly and posteriorly with vicryl sutures. The wound was closed in layers. Physiotherapy was started from day 1, with active mouth opening exercises. (Fig. 4).

**Fig. 1 : Pre Operative****Fig. 2 : CBCT****Fig. 3 : Intra- Operative**



**Fig. 4 :** Post operative mouth opening

### Discussion

Early ankylosis of TMJ in children can be a deterrent to normal mandibular growth. Therefore, early diagnosis of TMJ ankylosis and early surgical intervention is important.<sup>3</sup> Management of TMJ ankylosis is mainly performed through surgical intervention. Various techniques for the management of TMJ ankylosis have been described. However, no single technique has proved entirely satisfactory. The characteristic pathology of ankylosis is the formation of a bony mass, which replaces the articulation, resulting in restriction of mandibular movements. For this reason, treatment of TMJ ankylosis requires removal of a sufficient amount of bone to allow for free movement of the mandibular stump and interposition of some material between the remaining ramus and skull base.<sup>4</sup> It is necessary to use an interpositional material to prevent TMJ re-ankylosis after arthroplasty (or condylectomy). This particular aspect of the treatment has been the subject of numerous

discussions. The use of various allogenic interpositional materials has led to serious complications, including foreign body reaction and migration.<sup>5</sup> Homografts, such as skin, temporalis muscle, or fascia lata, are considered as the material of choice for interposition.<sup>6</sup> In recent years, a pedicled temporalis myofascial or temporal fascia flap has been advocated in TMJ surgery to treat the TMJ ankylosis.<sup>7</sup> Advantages of these flaps in TMJ reconstruction include close proximity to the TMJ without involving an additional surgical site, adequate blood supply, autogenous origin, and maintenance of attachment to the coronoid process which provides movement of the flap during function, simulating physiologic action of the disc. Its proximity to the joint allows for a pedicled transfer of vascularized tissue into the joint area.<sup>8</sup> In this case a composite (fascia, muscle, and periosteum) axial flap was harvested, as described by Herbosa & Rotskoff (1990). The axial flaps were easily rotated inferiorly into the joint space. Rotation under the zygomatic arch prevents bulkiness and avoids the need for surgically reducing the thickness of the zygomatic arch, as suggested by Pogrel & Kaban (1990), when rotating the muscle over the arch.<sup>9</sup>

### Conclusion

Interpositional arthroplasty using locally available temporalis muscle and fascia proves to be a valuable tool to fill the surgical defect and also to prevent recurrence. It also obviates the disadvantages of alloplastic materials as well as nonvascularized autogenous tissues.

## References

1. Holme AD, Marshall KA. Uses of the temporalis muscle flap in blanking out orbits. *Plast Reconstr Surg* 1979; 63: 336.
2. Habel G, Hensher R. The versatility of the temporalis muscle flap in reconstructive surgery. *Br J Oral Maxillofac Surg* 1986; 24(2): 96-101.
3. Mehrotra D, Pradhan R, Mohammad S, Jaiswana. Random control trial of dermis-fat graft and interposition of temporalis fascia in the management of temporomandibular ankylosis in children. *Br J Oral Maxillofac Surg* 2008; 46(7): 521-6.
4. Chossegros C, Guyot L, Cheynet F, Blanc JL, Gola R, Bourezak Z, et al. Comparison of different materials for interposition arthroplasty in treatment of temporomandibular joint ankylosis surgery: long-term follow-up in 25 cases. *Br J Oral Maxillofac Surg* 1997; 35(3): 157-60.
5. Omura S, Fujita K. Modification of the temporalis muscle and fascia flap for the management of ankylosis of the temporomandibular joint. *J Oral Maxillofac Surg* 1996; 54(6): 794-5.
6. Feinberg SE, Larsen PE. The use of pedicled temporalis muscle-pericranial flap for replacement of the TMJ disc: preliminary report. *J Oral Maxillofac Surg* 1989; 47(2): 142-6.
7. Su-Gwan K. Treatment of temporomandibular ankylosis with temporalis muscle and fascia flap. *Int J Oral Maxillofac Surg* 2001; 30(3): 189-3.
8. Pogrel MA, Kaban LB. The role of a temporalis fascia and muscle flap in temporomandibular joint surgery. *J Oral Maxillofac Surg* 1990; 48(1): 14-9.
9. Mani V, Panda AK. Versatility of temporalis myofascial flap in maxillofacial reconstruction - analysis of 30 cases. *Int J Oral Maxillofac Surg* 2003; 32(4): 368-72.