

Osteosarcoma: A Challenge in Diagnosis & Management

Rastogi P¹, Kumar K², Dhanpal R¹

Abstract

Osteosarcomas are highly malignant neoplasms of bone that are challenging to diagnose. These neoplasms often show atypical behavior. In the initial phase they may present as nondescript bony swellings with an indolent growth rate, only to become overtly aggressive and malignant towards the later phase of the disease. Similarly, the histological growth pattern of this neoplasm can be quite diverse, presenting with areas that mimic benign myofibroblastic tumors, giant cell granulomatous conditions and also may show partial encapsulation. The final diagnosis of an osteosarcoma is often reached after thorough sampling and examination of multiple biopsy specimens. This article reports a case of an advanced osteosarcoma of the maxilla in a 41 year old woman who came for the evaluation of a swelling.

Key Words: Osteosarcoma, Fibroblastic, Bone Neoplasm, Maxilla.

Introduction

Osteosarcoma is a common malignant tumor of bone, characterized by production of tumor osteoid tissue, with a reported incidence of 1:100,000 per year.¹ Though osteosarcomas of head and neck is relatively rare tumor and accounts for only 10% of all osteosarcomas.² In the head and neck, jaw is the most common site. The mean age of occurrence is in the fourth decade. The incidence of tumors in the maxilla favours the alveolar ridge and sinus, whereas mandibular lesions are most common in the body of the mandible. Previous radiation therapy and Paget's disease of bone are known predisposing factors, especially in patients who are older than 40. Radiographic evaluation is important in diagnosis, because clinical symptoms. Such as pain, paresthesia, swelling and loose teeth, are not specific.

Diagnosis by conventional radiography is difficult. It has to be supplemented by computed tomography (CT) to know the extent of involvement. The most common histopathologic variant in the jaw is osteoblastic osteosarcoma. Osteosarcoma of the jaw (JOS) differs from osteosarcoma of the long bones in its biological behavior, though the histological features are identical. It presents a lower incidence of metastasis and a better prognosis. Osteosarcomas should always be considered in the differential diagnosis of expansile lesions of jaw. Early diagnosis and adequate surgical resection are the keys to high survival rates.^{3,4}

Case report

A 41 year old female patient presented with a solitary swelling in the left middle-third of the face. The swelling was present for a month.

Corresponding Author : Dr. Priyanka Rastogi, Reader, Department of Oral and Maxillofacial Pathology and Microbiology I.T.S. Center for Dental Studies and Research Muradnagar, Ghaziabad (U.P) - 201206, India

1 Readers, Department of Oral and Maxillofacial Pathology and Microbiology I.T.S. Center for Dental Studies and Research Muradnagar, Ghaziabad (U.P) - 201206, India

2 Associate Professor, Department of Oral and Maxillofacial Pathology and Microbiology I.T.S. Center for Dental Studies and Research Muradnagar, Ghaziabad (U.P) - 201206, India

Extraorally, the swelling measured around 2x2cms . It was firm in consistency, tender on palpation and the overlying skin appeared stretched and shiny. There was associated lymphadenopathy. Intraorally, the swelling extended anterioposteriorly from distal aspect of 23 to distal aspect of 27 (Fig. 1). Lateral extension revealed the obliteration of the buccal vestibule, medially up to the midpalatal area. A root stump was present in relation to upper left first premolar.

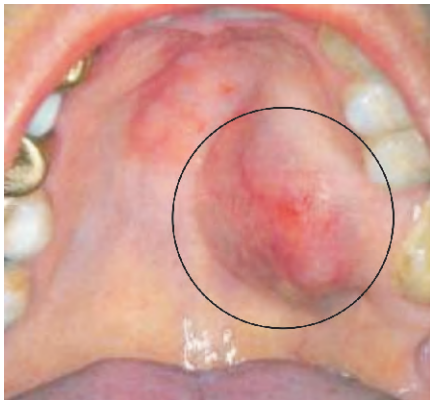

Figure 1 : Showing swelling from 23-27 region.

Orthopantomograph revealed a root stump in relation to 24 and increase width of periodontal ligament membrane with loss of lamina dura in relation to 26 (Fig. 2). Considering the findings, a provisional diagnosis of infected periapical pathology in relation to 26 was given. Patient was advised extraction of the root stump and endodontic therapy for 26. Following treatment, patient reported back to the hospital within two weeks with significant increase in the size of the swelling from 2x2 cms at the first visit to 6x5 cms. On intraoral examination, a foul smelling, reddish black mass measuring 6x5x6 cms, pedunculated swelling was seen arising from the extracted socket of 24. Palpatory findings revealed the swelling to be firm in consistency, tender on palpation and slight bleeding on probing. These features

suggested a provisional diagnosis of central giant cell granuloma.

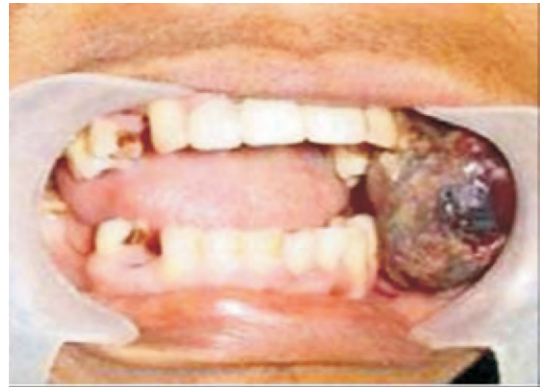

Figure 2: Showing a pedunculated reddish black mass arising from the extracted socket of 24.

Additional investigations were done that included hematological investigation which revealed increase in blood glucose and ESR levels. Radiographic investigations of paranasal sinus showed haziness of the left maxillary sinus, with erosion of infra orbital, medial and lateral walls. Computed tomography revealed a large expansile lesion arising from the lateral wall of the superior alveolus of the maxilla of the left side, extending into the left maxillary sinus and eroding all the walls of the maxillary sinus (Fig. 3). CT morphology suggested the possibility of a giant cell tumor.

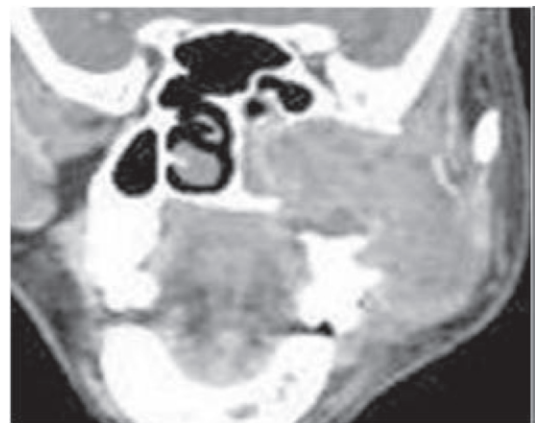

Figure 3: showing large expansile lesion arising from the lateral wall of the superior alveolus of the maxilla of the left side, extending into the left maxillary sinus and eroding all the walls of the maxillary sinus

An incisional biopsy was performed and histopathological findings showed a nonspecific inflammation suggesting an inaccurate biopsy site. A repeat biopsy was requested in relation to deeper areas. However, patient reported back within two days of incisional biopsy with a further increase in the size of the swelling with the lesion protruding out of the oral cavity causing inability to close the mouth.

Histopathology showed the lesion to be composed of proliferating fibroblasts along with bundles of collagen fibers. A markedly cellular lesion comprising of mature proliferating fibroblasts with infrequent mitosis and occasional atypia was seen (Fig. 4). Areas of tumor osteoid seen. There was a presence of abundant inflammatory cells along with few reactionary giant cells, interspersed with a myxoid background (Fig. 5). Storiform pattern of arrangement of fibroblasts was also seen, with the fibroblasts showing atypia in relation to size and shape. Invasion into the adjacent adipose tissue was also noted. Few areas suggested histiocytic type cells admixed with atypical fibroblasts and mitotic figures were also seen on the basis of clinical and histopathological features the final diagnosis of fibroblastic variant of osteosarcoma was made.

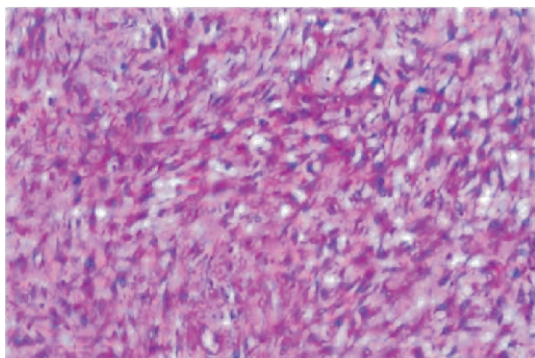


Figure 4: showing mature proliferating fibroblasts with infrequent mitosis and occasional atypia

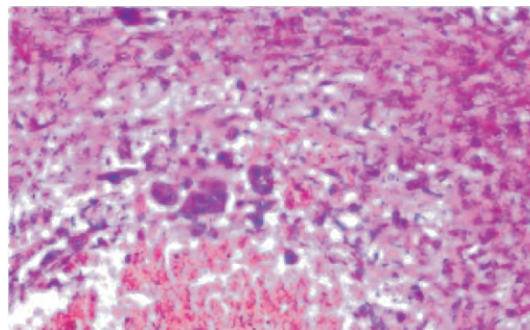


Figure 5: showing abundant inflammatory cells along with few reactionary giant cells, interspersed with a myxoid background.

Discussion

OS are primarily bone producing malignant tumours arising most frequently in the long bones. Jaw OS usually occur one to two decades later than that of OS of other regions. Patients with OS usually have nonspecific clinical symptoms, the most common of which is pain associated with the swelling presenting from weeks or months. It has a bimodal age distribution, with a major peak in the second decade and a somewhat smaller peak after the age of 50.⁵ However, bimodal distribution of jaw lesions differ from those in the appendicular skeleton, with the first peak occurring somewhat later, in the third decade. The present case, with a critical clinical appearance of pain and swelling, is in accordance with the literature related to jaw OS, where patient presents with clinical symptoms in 3rd and 4th decade of life.^{6,7}

These neoplasms often show typical behavior in the initial phase presenting as a nondescript swelling, only to become overly aggressive in the later phase of the disease. Histologically, although OS of jaws are almost similar to that of long bones, they are always better differentiated than the latter.⁸ It has been reported that production of osteoid by malignant cells, even in small amounts, is

diagnostic of OS. Depending on the relative amounts of osteoid, cartilage, or collagen fibres present in the extracellular matrix, OS are categorized histopathologically into osteoblastic, chondroblastic, or fibroblastic subtypes. In reality, most OS exhibit varying amounts of these three cell types and matrix. Therefore, division into any one of these types is arbitrary and is generally meant to signify greater than 50% prevalence of any of these histologic types. Recent studies have focused on new markers for early detection of OS.⁹ Park et al. in their recent study showed by immunohistochemistry that high-grade OS of the jaws had a higher expression rate of proteins involved in regulation of growth and metastasis of cancer cells (ezrin and Metastatic tumour antigen) suggesting that their positivity can be used as additional prognostic markers in OS of the jaw^{10,11}.

Another study analyzed the clinicopathological features and immunohistochemical expression of p53, MDM2, CDK4, PCNA and Ki67 proteins in 25 head and neck OS and found 52% positivity for p53, 24% for MDM2, 84% for CDK4, 92% for PCNA and 88% for Ki-67 suggesting PCNA as one of most favourable prognostic marker.^{9,12} Another study suggested the role of 12q13-15 genes in OS of the jaws with amplification and over expression of these genes might help in detecting high-grade tumours¹³. Response to chemotherapy (CT) is best seen in fibroblastic subtypes and poorest in chondroblastic subtype. Multimodality therapy using chemotherapy and radiation treatment (RT) has shown improvement in survival rates in the OS of the extremity, from 20% to 70%, which is better than the 40% survival rate reported for jaw OS.^{14,15}

Conclusion

Osteosarcoma should always be considered in the differential diagnosis of expansile lesions of the jaws. Pain may not always be an associated feature. Pain associated can be misinterpreted as odontogenic in origin, resulting in delay in obtaining the final diagnosis. Movement of teeth in the area of a lesion suggests a neoplastic process. Radiographic findings are not always pathognomonic; the 'sunburst' pattern may not always be seen. All exophytic rapidly growing lesions should receive clinical and radiographic follow-up until remission. Sufficient sample of biopsy is a must for final diagnosis. For proper management, emphasis should be laid on the aggressiveness of this lesion which warrants an early identification and diagnosis followed by prompt treatment.

References

1. Klein MJ, Siegal GP. Osteosarcoma: anatomic and histologic variants. *Am J Clin Pathol* 2006; 125: 555-81.
2. Chen WL, Feng HJ, Li JS, Li HG. Expression and pathological relevance of inducible nitric oxide synthase in osteosarcoma of the jaws. *Int J Oral Maxillofac Surg* 2007; 36: 541-4.
3. Amaral MB, Buchholz I, Freire-Maia B, et al. Advanced osteosarcoma of the maxilla: a case report. *Med Oral Patol Oral Cir Bucal* 2008; 13: E492-5.
4. Garrington GE, Scofield HH, Cornyn J, Hooker SP. Osteosarcoma of the jaws. Analysis of 56 cases. *Cancer* 1967; 20: 377-91.
5. Regezi JA, Zarbo RJ, McClatchey KD, Courtney RM, Crissman JD. Osteosarcomas and chondrosarcomas of the jaws: immunohistochemical correlations. *Oral Surg Oral Med Oral Pathol* 1987; 64: 302-7.
6. Neville BW, Damm DD, Allen CM, Bouquot JE. *Oral and Maxillofac Pathol*. 2nd ed. Philadelphia: WB Saunders; 2002.
7. Iavarone A, Matthey KK, Steinkirchner TM,

- Israel MA. Germ-line and somatic p53 gene mutations in multifocal osteogenic sarcoma. *Proc Natl Acad Sci USA* 1992; 89: 4207-9.
8. Junior AT, de Abreu Alves F, Pinto CA, Carvalho AL, Kowalski LP, Lopes MA. Clinicopathological and immunohistochemical analysis of twenty-five head and neck osteosarcomas. *Oral Oncol* 2003; 39: 521-30.
 9. Hansen MF. Genetic and molecular aspects of osteosarcoma. *J Musculoskelet Neuronal Interact* 2002; 2: 554-60.
 10. Bennett JH, Thomas G, Evans AW, Speight PM. Osteosarcoma of the jaws: a 30-year retrospective review. *Oral Surg Oral Med Oral Pathol Oral Radiol Endod* 2000; 90: 323-32.
 11. Hayden JB, Hoang BH. Osteosarcoma: basic science and clinical implications. *Orthop Clin North Am* 2006; 37: 1-7.
 12. Clark JL, Unni KK, Dahlin DC, Devine KD. Osteosarcoma of the jaw. *Cancer* 1983; 51: 2311-6.
 13. Schajowicz F. Histological typing of tumours of bone; WHO international histological typing of tumours. Berlin: Springer-Verlag 1993.
 14. Dixit AG, Parikh NJ. Osteosarcoma of jaw bone. *J Indian Acad Oral Med Radiol* 2008; 20: 41-4.
 15. Del Vecchio A, Della Rocca C, Agrestini C, Criscuolo F, Manicone AM. [Histological and immunohistochemical studies in cases of malignant mesenchymal neoplasms of the oromaxillofacial area]. *Minerva Stomatol* 1994; 43: 199-206.