

Epiplating Systems for Retaining Facial Prostheses: A Case Report

Sethi T¹, Kheur S², Kheur M³, Jambhekar S⁴

Abstract

Rehabilitation of patients using extraoral prosthesis with bone fixtures is gaining popularity. Its advantages over conventional adhesive retained prostheses make it a better option for the patient. Various factors need to be taken into account for ensuring the success of implants and therefore treatment planning is of utmost importance.

This case report demonstrates the procedure for rehabilitating a patient with epiplating system fixtures using magnets as attachments for the silicone prosthesis.

Keywords: Epiplating, Auricular Prosthesis, Maxillofacial Prosthesis

Introduction

Maxillofacial prosthetics deals with a wide range of rehabilitations ranging from simple adhesive retained body parts to those involving extensive reconstructive surgeries and implants. Loss of these body parts can be congenital or due to trauma, or as an outcome of surgery for carcinomas.¹

Adhesive retained prostheses have disadvantages like inadequate retention and stability, wear of prosthesis due to constant removing and placing the prosthesis, skin reactions to the adhesive and general lack of acceptance amongst patients.^{2,3,4} The use of implants to retain facial prostheses is on the increase.

There are various factors influencing the position of an implant for an auricular prosthesis:

a) Thickness of underlying bone: The thickness of underlying bone of the skull (mastoid region⁵) should be measured and

must be at least 3-4mm to provide a stable implant.^{6,7}

b) Position of anti helix of prosthesis: The anti helix is the bulkiest or thicker part of the ear prosthesis and the implants should be placed below it and approximately 20mm from the external ear canal.^{6,7} For the right ear, they should be placed at 8 and 11 o'clock positions and for the left at 1 and 4 o'clock¹. (Fig 1)

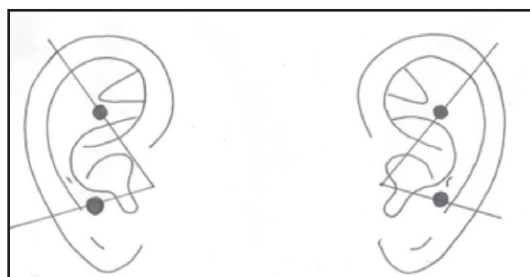


Figure 1: Position of implants on the left and right ear

c) Position of the contra lateral ear: The protrusion, inclination, anterior- posterior position, superior -inferior position, shape and size of the contra lateral ear must be taken

Corresponding Author : Dr. Tania Sethi, 808, Sindh Colony, Aundh, Pune 411007.
Phone Number: +918793377303, +919823004331 Email address: drtaniasethi@gmail.com

1. Post Graduate Student, Dept. of Prosthodontics, M.A.Rangoonwala Dental College, Pune.
2. Professor, Dept. of Oral Pathology, D.Y.Patil Dental College, Pimpri.
3. Professor, Dept. of Prosthodontics, M.A.Rangoonwala Dental College, Pune.
4. Lecturer, Terna Dental College, Navi Mumbai.

into consideration^{6,8-11}(Fig 2).In a symmetric face, positions of the nasion, gnathion and sub-nasale can be considered to locate the superior and inferior border of the prosthetic ear.⁶ The Frankfort's plane and upper and lower insertion points can also be used as a guideline.⁶

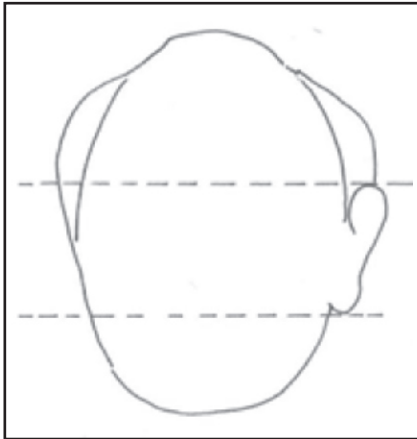


Figure 2: Position of contra lateral ear for planning the prosthesis

d) Presence of ear remnants and soft tissue cartilage: (Fig 3) These may be congenital as in case of microtia or present due to previous surgeries.^{6-10,12,13} Some patients refuse to remove them and they need to be considered while making a prosthesis.

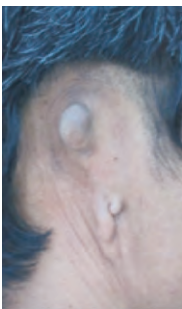

Figure 3: Presence of ear remnants

e) Position of BAHA implant/hearing aids: Boneanchoring hearing aids are placed with the support of implants in the mastoid region. An adequate distance has to be maintained between the BAHA and prosthesis for it to

function effective⁶(Fig 4).These can be camouflaged by positioning the prosthesis correctly and hearing aids can also be incorporated in the prostheses.^{6,7}

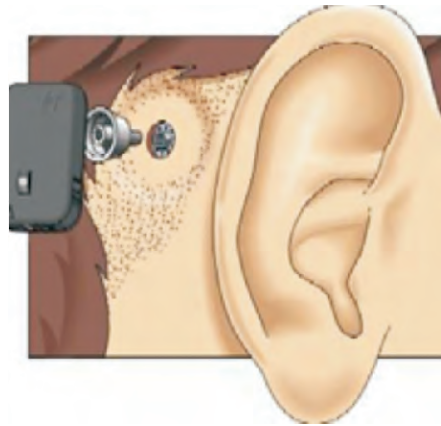

Figure 4: Position of a BAHA in relation to a prosthetic ear

CT scan data can be used and manipulated to form 3D models and using interactive software, implant positioning can be planned^{6,11}. Softwares such as Mimics (Materialise, Belgium) can be used to mirror the contra lateral ear positioning onto the defect side in a virtual environment. This can be used for further procedures like Rapid Prototyping to form 3D models and templates used for surgical procedures.

For auricular cases, implants with bar and magnetic attachments are a good option providing adequate retention and patient compliance. Bone attachments can be of 2 types primarily- Root form implants and epiplates.

The epiplate system involves the placement of a titanium framework subperiostally on the surface of the bone and is held in place with the help of bone fixation screws. Titanium being biocompatible is well accepted for these restorations. This case report provides an overview of treating an auricular case with an epiplate, magnetic attachments and its final

restoration in silicone elastomer.

Case report:

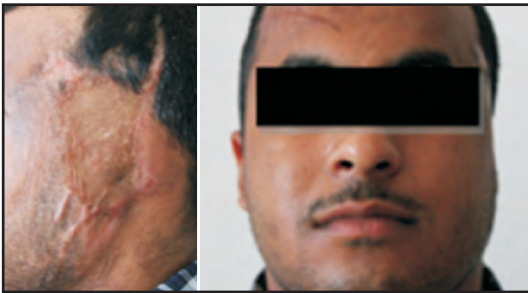

Figure 5 : Pre treatment presentation

A 28 year old male patient with a history of chemical injury presented to the hospital for replacement of his missing left external ear (Fig 5). Different options for replacement of the ear including reconstructive surgery, adhesive retained prosthesis, and implant retained prosthesis were discussed by the maxillofacial prosthetic rehabilitation team.

A fixed prosthesis was chosen by the patient. Using the epiplating system for bone support, a magnet retained prosthesis was planned.

1. Impressions

Impression of the defect site was made using irreversible hydrocolloid (Vignette, Dentsply, U.S.A). Care was taken to keep the tissue as relaxed as possible to improve accuracy of impression. Anatomical landmarks were marked out on the patient and transferred onto the cast through the impression.(Fig 6)

A cast of the same was obtained in dental stone (Kalabhai Karson Pvt. Ltd., India).

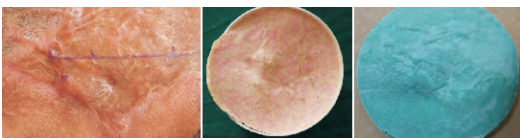


Figure 6: Impression and cast

2. Surgical Stent

The position of the implants were planned as per the prosthetic planning and marked out on the cast. A surgical stent was fabricated (Fig 7)

by duplicating the wax trial ear, using clear self cure acrylic resin (Acryln `R`, Asian Acrylates, India).

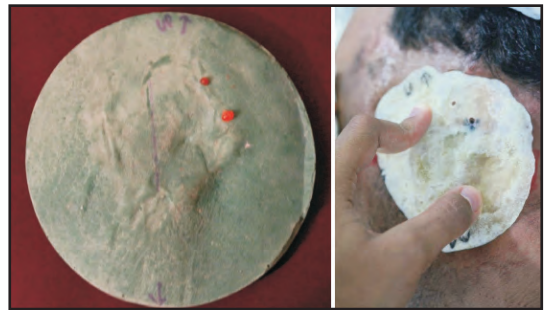


Figure 7 : Fabrication of Stent and Trial

3. Surgical Phase

The stent was used to mark the implant sites onto the skin. These were transferred onto the underlying bone with the help of surgical ink. A full thickness flap was raised (Fig 8). The implant sites were marked again.

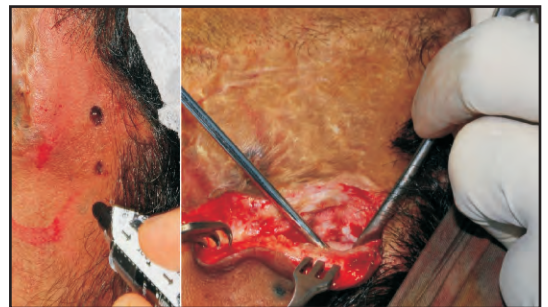


Figure 8: Marking of site and reflection of flap

The epiplate was bent to conform to the contours of the bone and adapted well before finally being fixed on. The epiplate was screwed on with the help of fixation screws (Fig 9).Magnetic abutments (Medicon instruments , Germany) were placed on it (Fig 10). The flap was closed and sutured, the skin was released above the magna-abutments to allow them to protrude above the surface of the skin.

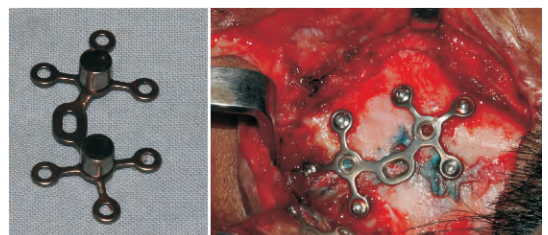


Figure 9 : Epiplate placed on the bone

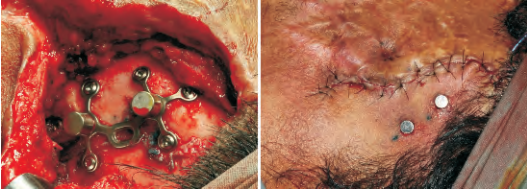

Fig 10: Magnetic abutments placed on epiplate and closure of flap

4. Prosthetic Phase

After 3 months, pick up magnets were placed on the magnets present on the epiplate. These were splinted together using heavy body silicone elastomer (Aquasil, Dentsply de tray, U.S.A) to avoid mobility during impression making. The final impression was made using light body silicone (3M ESPE Express, U.S.A) surrounding the magnets and was picked up using alginate. A cast was obtained onto which the magnets (Technovent, Ltd, Wales, U.K)were attached.

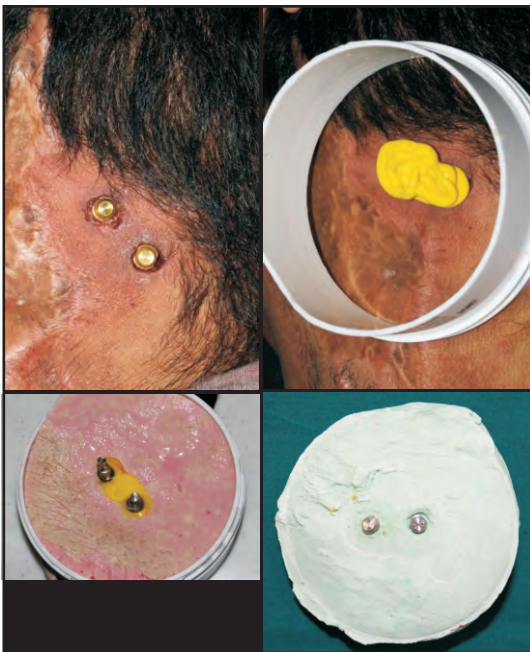

Figure 11: Final impression and cast

An acrylic substructure (Acryln `R`, Asian Acrylates, India) incorporating the magnets was made. A wax up of the ear was made in modeling wax incorporating this substructure.

The wax up was tried onto the patient and adjustments were made. The contralateral ear was used as a reference for the general contouring of the ear.

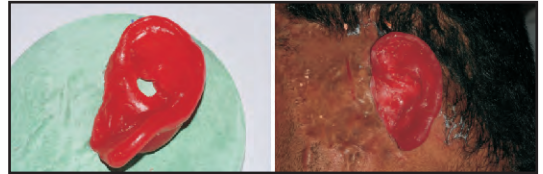


Figure 12: Wax trial

The wax ear was flaked as per conventional protocol using a three part mold. Silicone (Z 004, Technovent, U.K) in a 1:1 ratio was manipulated. Intrinsic pigments (Cosmesil, Technovent Pvt. Ltd., U.K) were added to it to match the shade of different areas of the prosthesis. Flocking Cosmesil, Technovent Pvt. Ltd, U.K)was added to give the prosthesis a life like appearance. The mold was (packed and cured for 1 hour at 80 degrees Celsius. Finishing with extrinsic staining (Cosmesil, Technovent Pvt. Ltd., U.K) giving the prosthesis its final touches was artistically carried out and a sealant was applied (Single component silicone, Technovent Pvt. Ltd., U.K).

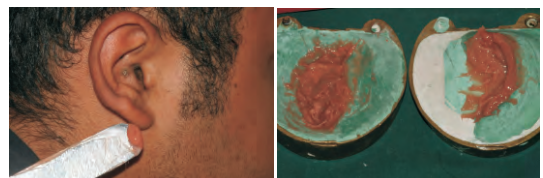


Figure 13: Shade matching

5) Final Prosthesis :

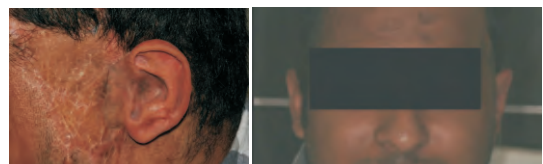

Figure 14: Final prosthesis

Discussion

Epliplating systems have numerous advantages over the use of root form implants

for facial prosthetics. One of the most important advantages is force distribution over a wider surface area. Multiple screws also share the load distribution. Failure of one screw may not lead to failure of the prosthesis in whole. This system is well accepted in cases especially where the bone quality is compromised and any added form of retention will aid in a better prognosis for the prosthesis.

References

1. Sethi T, Kheur M. Silicone elastomers-Their role in maxillofacial prosthetic rehabilitation. *International Journal of Basic and Applied Medical Sciences (online)* May-August 2012,2(2):263-6.
2. Gacto-Sanchez P, Infante-Cossio P, Gomez-Cia T, Lagares A, Belmonte-caro R. The Ti-Epiplating System as an Alternative for Ear Prostheses in Burned Patients. *J Burn Care Res.* 2011 May-Jun; 32(3): 101-7.
3. Chen MS, Udagama A, Drane J. Evaluation of facial prostheses for head and neck cancer patients. *J Prosthet Dent* 1981; 46:538-44.
4. Jani RM, Schaaf NG. An evaluation of facial prostheses. *J Prosthet Dent* 1978; 39:546-50.
5. Aydin C, Karakoca S, Yilmaz H, Yilmaz C. Implant-retained auricular prostheses: An assessment of implant success and prosthetic complications. *Int J Prosthodont.* 2008 May-Jun; 21(3):241-4.
6. Watson RM, Coward TJ, Forman GH, Moss JP. Consideration for Treatment Planning for Implant-Supported Auricular Prostheses. *Int J Oral Maxillofac Implants* 1993; 8(6):688-94.
7. Watson RM, Coward TJ, Forman GH. Results of Treatment of 20 Patients with Implant-Retained Auricular Prostheses. *Int J Oral Maxillofac Implants* 1995 Jul-Aug; 10(4):445-9.
8. Prabhu N, Kumar S, Gupta S. Fabrication of an auricular prosthesis: a Case Report. *Dent Update.* 2011 Jul-Aug; 38(6):414-6, 418.
9. Roberts AC. *Facial Prosthesis. The Restoration of Facial Defects by Prosthetic Means.* London: Kimpton, 1971.
10. Coward TJ. *Production of Artificial Ears – Aspects of the Technical Problem.* London: University of London, 1996.
11. Reitemeier B, Schöne C, S, Stockmann F, Ullmann K, Ekelt U. Planning implant positions for a auricular prosthesis with digital data. *J Prosthet Dent* 2012; 107(2):128-31.
12. Pekkan G, Tuna SH, Oghan F. Extraoral prostheses using extra oral implants. *Int J Oral Maxillofac Surg* 2011; 40: 378-83.
13. Beumer JB, Curtis TA, Marunick MT. *Maxillofacial Rehabilitation: Prosthodontic and Surgical Considerations.* 2nd ed. St. Louis: Ishiyaku Euromerica 1996; 377-449.