

Management of Open Apex in Anterior Teeth using MTA- Report of Three Cases

Sonali Taneja¹, Manju Kumari², Komal Malhotra³, Anshul Arora³, Surabhi Anand³

Abstract

Trauma or deep caries in the immature tooth can result in pulp necrosis with open apex which can pose a significant endodontic and restorative challenge. Aim of endodontic treatment in such cases is to form an apical barrier or a stop against which obturating material can be condensed. This technique is termed as Apexification. For a long time, calcium hydroxide was the only material used in the apexification procedure. Despite its popularity for the apexification procedure, Ca(OH)₂ therapy has some inherent disadvantages, including variability of treatment time, unpredictability of apical closure, difficulty in patient follow-up, and delayed treatment. In recent times, interest has centered on the use of mineral trioxide aggregate (MTA) for apexification. MTA allows for an immediate apical barrier to be formed and thus immediate obturation of the root canal system. This case report presents cases showing single step apexification with the use of MTA as an apical closure material.

Keywords: Apexification, Mineral Trioxide Aggregate, Single visit Apexification

INTRODUCTION

Impact injuries or pulpal diseases involving immature permanent tooth always present an endodontic challenge. Both these insults render the dental pulp nonvital. If this occurs prior to the complete root formation and apical closure, it may affect the development of the immature roots of involved teeth, cause apical resorption or open root apices.

Endodontic management of nonvital young permanent tooth with a wide open blunder buss apex has long presented a challenge. In the past, techniques for management of the open apex in nonvital teeth were confined to custom fitting the filling material, paste fills

and apical surgery.¹ However, the limited success enjoyed by these procedures resulted in significant interest in the phenomenon of continued apical development, or establishment of an apical barrier referred to as "Apexification".²

Numerous materials and procedures have been recommended to induce root-end closure in teeth with immature apices. Antibacterial pastes like metronidazole, ciprofloxacin, and cefactor have effectively encouraged apexification³. Deliberate over-instrumentation of the periapical area to produce a blood clot that will induce apical closure has also been described⁴. The

Corresponding Author : Dr. Sonali Taneja, Professor & Head, Department of Conservative Dentistry and Endodontics, I.T.S - C.D.S.R., Muradnagar, Ghaziabad. **E-mail :** drsonali_taneja@yahoo.com **(M)** 9891688100

¹ Professor & Head, Department of Conservative Dentistry and Endodontics I.T.S - C.D.S.R., Muradnagar, Ghaziabad.

² Associate Professor, Department of Conservative Dentistry and Endodontics, I.T.S - C.D.S.R., Muradnagar, Ghaziabad.

³ Post Graduate Student, Department of Conservative Dentistry and Endodontics, I.T.S - C.D.S.R., Muradnagar, Ghaziabad.

materials that have been proposed for this purpose include tricalcium phosphate⁵, calcium hydroxide⁶, freeze dried bone⁷, freeze-dried dentin⁸, collagen calcium phosphate⁹, proplast (a polytetrafluor-ethylene and carbon felt-like porous material).¹⁰

For a long time, calcium hydroxide was the only material used in the apexification procedure. However, there are certain difficulties associated with it, such as the very long treatment time required, the possibility of tooth fracture, and incomplete calcification of the bridge.

Recently, synthetic apical barriers with a variety of materials have been proposed as alternatives to the traditional apexification treatment method with calcium hydroxide. Mineral trioxide aggregate (MTA) is the most popular material for this aim. MTA has been suggested to create an apical plug at the root-end and helps to prevent the extrusion of the filling materials.


The following three clinical cases describe the use of MTA as an apical plug in the treatment of three nonvital immature permanent anterior teeth.

CASE REPORTS

Case-I

A 19-year-old female patient presented with a mild swelling at the apical region of her maxillary left central incisor. Radiographic examination revealed an immature tooth with a wide open apex and a radiolucent area in proximity of the apex of the tooth (Figure. 1. a). Local anesthesia was obtained by labial infiltration using lidocaine with 1:100,000 epinephrine. After preparing an endodontic access opening under the rubber dam isolation, radiograph was taken to determine the working length. The root canal was lightly

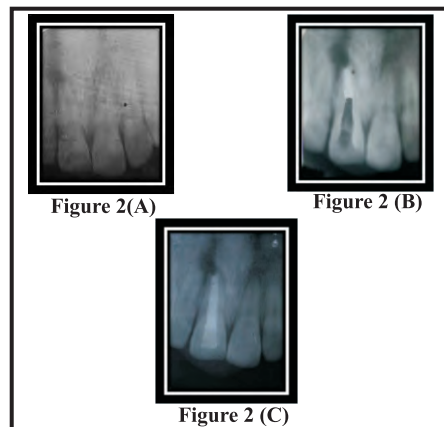
cleaned with a hand file till no.80 under irrigation with 2.5% NaOCl. The root canal was then dried with sterile paper points. Next, calcium hydroxide was placed in the root canal. And the access opening was temporized. After 2 weeks, the calcium hydroxide dressing was removed by hand instrumentation, and final irrigation was done with 17% EDTA followed by 2.5% NaOCl. The root canal was then dried with sterilized paper points. Before the application of MTA, a small piece of resorbable collagen matrix (Colla Cote) was positioned at the apical end of the canal. A thick mixture of MTA was then prepared and placed in the apical portion of the canal using MTA carrier (Figure. 1. b). The correct position of the MTA mixture was verified with a radiograph. A cotton pellet moistened with sterile water was placed in the pulp chamber and the access cavity was closed with Cavit G. The temporary filling was removed after a week, and the setting of the MTA was confirmed. Finally, the root canal was obturated using AH Plus sealer and thermoplasticized gutta-percha using Obtura II device. Finally, coronal restoration was completed with a composite resin (Figure. 1. c).



*Figure 1 (A): Preoperative radiograph showing an immature tooth with a wide open apex and a radiolucent area in proximity of the apex.
Figure 1(B): Apical plug with MTA formed
Figure 1(C): Post Operative radiograph.*

Case-II

A 18 year old male patient, reported with a chief complaint of discoloured right maxillary central incisor with the history of trauma at the age of 9. The concerned tooth did not respond to both electric and heat test. Detailed radiographic examination revealed open apex with associated periapical lesion in relation to maxillary right central incisor (Figure 2 a). Access opening was prepared under rubber dam isolation and working length was determined. Biomechanical preparation was done using no 80 K-file using circumferential filing motion. Root canal irrigation was done using with 2.5% NaOCl. Calcium hydroxide was placed in the root canal and patient recalled after one week. At subsequent appointment, once the root canal was found completely dry, the canal was debrided with 17% EDTA followed by 2.5% NaOCl.



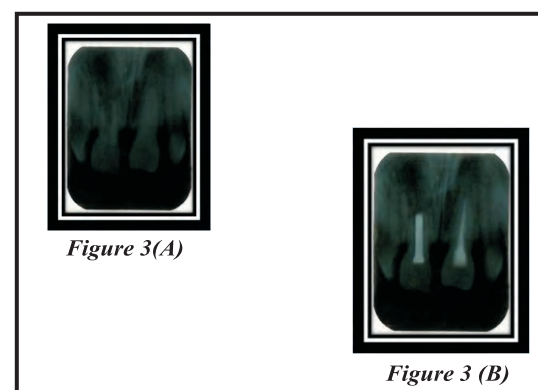
*Figure 2(A): Pre operative radiograph
Figure 2 (B):Apical plug with MTA formed
Figure 2 (C): Post operative radiograph*

The canal was dried with paper points. A small piece of resorbable collagen matrix (Colla Cote) was positioned at the apical end of the canal. This created an apical barrier for the MTA placement. A thick mixture of MTA was then prepared and applied to the apical portion of the canal using MTA carrier. The position of the MTA plug was verified with a radiograph

(Figure 2 b). A cotton pellet moistened with sterile water was placed in the pulp chamber and the access cavity was closed with a temporary filling material. The temporary filling was removed after a week, and the setting of MTA was confirmed. The root canal was filled with thermoplasticized gutta-percha using Obtura II device along with root canal sealer. Access cavity was sealed with composite resin (Figure 2 c).

Case - III

A 17 year old female patient, reported with a chief complaint of mobility in both the maxillary central incisors with the history of trauma at the age of 8. Detailed radiographic examination revealed a large canal with open apex associated with periapical lesion in relation to maxillary right central incisor and a slight radiolucency in the left maxillary central incisor (Figure 3a). The concerned teeth did not respond to both electric and heat test. Access opening was prepared under rubber dam isolation and working length was determined for both the teeth. Biomechanical preparation was done using no 80 K-file in the right incisor and no 50 K-file in the left incisor using circumferential filing motion.



*Figure 3(A): Pre operative radiograph
Figure 3 (B): Post operative radiograph*

Root canal irrigation was done using 2.5% NaOCl. Calcium hydroxide in a paste like

consistency was placed in the root canals with a help of lentulo spiral and the patient recalled after one week. At subsequent appointment after removal of dressing, root canal was found completely dry and canal was debrided with 17% EDTA followed by 2.5% NaOCl. The canal of maxillary right central incisor was dried with paper points and Mineral trioxide aggregate was placed in subsequent increments with the help of a Micro Apical Placement system and a hand plugger in the whole canal (due to the short root length) against a resorbable collagen matrix placed apically. The correct position of the MTA mixture was verified with a radiograph. A cotton pellet moistened with sterile saline was placed and access cavity was sealed with Cavit G. The left central incisor was also obturated using Gutta percha and zinc oxide eugenol sealer. The temporary filling was removed after a week, and the setting of MTA was confirmed. This was followed by post endo restoration with composite resin

DISCUSSION

Traditionally calcium hydroxide has been a popular material for apexification of necrotic immature permanent teeth. Whilst the advantages of calcium hydroxide lie in the fact that it has been widely studied and has shown success, the disadvantages are its prolonged treatment time and increased risk of root fracture due to dressing the root canal for an extended time.¹¹ Moreover, reopening the root canal and recleaning during these visits may disturb the process of apexification. During a long apexification treatment, there is a possibility of a root canal reinfection due to leaking temporary material. Coviello and Brilliant¹² introduced tricalcium phosphate in 1979 to create an artificial barrier and considered that the degree of success was

similar to the conventional long term calcium hydroxide therapy. Nevins et al reported favourable outcomes using collagen calcium phosphate gel.¹³

In 1999, Torabinejad and Chivian¹⁴ introduced the use of MTA as an apical plug. Mineral trioxide aggregate has a variety of potential uses, which includes its use as a canal obturating material. It has superior biocompatibility with periodontal tissues and appropriate mechanical properties as an apical sealing material.^{15,16} After the placement of MTA in root canals, an initial mechanical seal is formed as a result of its gradual dissolution along with the nucleation and growth of hydroxyapatite crystals, filling the microscopic space between MTA and the dentinal wall. With time, it was seen that a diffusion-controlled reaction between apatite layer and dentine leads to their chemical bonding. This results in the creation of a seal at the MTA-dentine interface.

Studies have demonstrated that MTA can induce regeneration in the periapical tissues, such as periodontal ligament, bone, and cementum. It has been suggested that MTA permitted cementoblast attachment and growth, while the production of mineralized matrix gene and protein expression indicated that MTA could be considered cemento-conductive.¹⁷

MTA stimulates the formation of calcific barrier across the root apex. Shababhang et al.¹⁸ observed a greater consistency of the apical hard tissue formed by MTA on comparison with calcium hydroxide. Moisture contamination at the apex of tooth before barrier formation is often a problem with calcium hydroxide. However as MTA is hydrophilic in nature, the presence of moisture does not affect its sealing ability. This is very

important in necrotized teeth with periradicular lesion, as the exudate from the lesion goes continuously into the canal after cleaning. However before using MTA to treat a necrotized tooth with apical lesion, calcium hydroxide therapy needs to be done in order to disinfect the canal¹⁹. Thus, in the presented cases, before placement of MTA for apexification, the root canals were medicated with calcium hydroxide for 2 weeks.

Before the application of MTA, a small piece of resorbable collagen matrix was positioned at the apical end of the canal in order to prevent the extrusion of MTA material periapically. According to Matt G.D. et al,¹⁹ a 5mm apical barrier is significantly stronger and shows less leakage than a 2mm barrier. Therefore, in the present cases, a 5 mm apical plug was fabricated. This was followed by obturation with thermoplasticized gutta-percha. However, in case III, the entire canal was sealed with MTA as the root length of the root was short. After this, a cotton pellet moistened with sterile water was placed in the pulp chamber for a period of one week to facilitate proper setting of MTA.

As observed in the radiographs of our cases, all the teeth treated with MTA seemed to show effective filling and sealing of the root canals. Clinically the patients were free of clinical symptoms. Torabinejad and Chivin¹⁴, in their study reported absence of clinical symptoms & formation of new hard tissue in the apical area. MTA appeared to be a varied option for apexification and offers the added advantage as a complete root canal filling material.

CONCLUSION

Based on our observations, it was concluded that the use of MTA as an apical plug in necrotized teeth with open apices is a valuable option and may replace multivisit

apexification procedure, thus reducing the treatment time.

REFERENCES

1. Rafter M. Apexification: A Review. *Dent Traumatol* 2005;21:1-8.
2. Frank AL. Therapy for the divergent pulpless tooth by continued apical formation. *J Am Dent Assoc* 1966;72:87-93.
3. Thibodeau B, Trope M. Pulp revascularization of a necrotic infected immature permanent tooth: Case report and review of the literature. *Paediatr Dent* 2007;29:47-50.
4. Ham JW, Patterson SS, Michell DF. Induced apical closure of immature pulpless teeth in monkeys. *Oral Surg Oral Med Oral Pathol Oral Radiol Endod* 1972;33:438-49
5. Coveillo J, Brilliant JD. A preliminary clinical study on the use of calcium phosphate as an apical barrier. *J Endod* 1979;5:6-13.
6. Schumacher JW, Rutledge RE. An alternative to apexification. *J Endod* 1993;19:529-31
7. Rossmeisl R, Reader A, Melfi R, Marquard J. A study of freeze-dried (lyophilized) cortical bone used as an apical barrier in adult monkey teeth. *J Endod* 1982;8:219-26.
8. Rossmeisl R, Reader A, Melfi R, Marquard J. A study of freeze-dried dentin used as an apical barrier in adult monkey teeth. *Oral Surg* 1982;53:303-10.

9. Nevins A, Finkelstein F, Laporta R, Borden BG. Induction of hard tissue into pulpless open-apex teeth using collagen-calcium phosphate gel. *J Endod* 1978;4:76-81.
10. Eleazer PD, McDonald TW, Sinai IH, Fantasia JE, Michelich RJ, Yagiela JA. Proplast as an apical barrier in root canal therapy. *J Endod* 1984;10:487-90.
11. Andreasen JO, Farik B, Munksgaard EC. Long-term calcium hydroxide as a root canal dressing may increase risk of root fracture. *Dent Traumatol* 2002;18:134-7
12. Coviello J, Brilliant JD. A preliminary clinical study on the use of tricalcium phosphate as an apical barrier. *J Endod* 1979;5:6-13.
13. Nevins A, Finkelstein F, Laporta R, Borden BG. Induction of hard tissue into pulpless open-apex teeth using collagen-calcium phosphate gel. *J Endod* 1978;4:76-81.
14. Torabinejad M, Chivian N. Clinical applications of mineral trioxide aggregate. *J Endod* 1999 Mar;25:197-205.
15. Torabinejad M, Pitt Ford TR, McKendry DJ, et al. Histologic assessment of mineral trioxide aggregate as a root-end filling in monkeys. *J Endod* 1997;23:225-228
16. Torabinejad M, Hong CU, Lee SJ, et al. Investigation of mineral trioxide aggregate for root-end filling in dogs. *J Endod* 1995;21:603-608.
17. Chong BS, Pittford TR. Root end filling materials: rationale and tissue response. *Endodontic topics* 2005;11:114-30
18. Shabahang S, Torabinejad M, Boyne PP, Abedi H, McMillan P.A comparative study of root-end induction using osteogenic protein-1, calcium hydroxide, and mineral trioxide aggregate in dogs. *J Endod* 1999;25:1-5.
19. Matt GD, Thorpe JR, Strother JM, McClanahan SB. Comparative study of white and gray mineral trioxide aggregate (MTA) simulating a one- or two-step apical barrier technique. *J Endod* 2004; 30:876-879.