

Autologous Platelet-Rich Fibrin: A Boon to Periodontal Regeneration - Report of Two Cases

Shetty S¹, Yadav N², Mehta M², Vaish S³, Dodwad V⁴

Abstract:

Oral health continues to be a major health problem worldwide, chronic periodontitis being one of the most prevalent oral diseases. The pathologic hallmark of periodontitis is the destruction of the supporting structures of the teeth involved. The first goal of periodontal therapy is the complete healing of inflammatory condition and next is the regeneration of all lost structures. One of the most important and currently unsolved problems in clinical periodontics is the covering of multiple adjacent recessions and predictable successful treatment of furcation defects. Currently, no single regenerative material can be considered the gold standard in the treatment of periodontal defects. Recently, importance has been given to the use of platelet-rich fibrin (PRF) for predictably obtaining periodontal regeneration. PRF is an intimate assembly of cytokines, glycan chains, and structural glycoproteins, which are enmeshed within a slowly polymerized fibrin network; it has the potential to accelerate soft and hard tissue healing. The purpose of this article is to present the clinical results of a Grade II mandibular furcation defect and Millers Class I gingival recession treated with PRF.

Keywords: Platelet Rich Fibrin, Periodontal Regeneration, Furcation Defect.

Introduction

Periodontal disease is an inflammatory disease that destroys the periodontium, including the alveolar bone, and if left untreated, can lead to tooth loss. Dental surgeons are constantly looking for an “edge” that jump starts the healing process to maximize predictability as well as the volume of regenerated periodontal tissue. Therefore goals of conventional periodontal therapy, both non surgical and surgical, have aimed at improving the health of the periodontal tissues and at arresting the periodontal disease, but this therapy does not replace the lost tissues.¹ Over the years, there has been a growing

interest in exploring the ability to regenerate the tissues lost to the disease, and thereby not only arresting the disease, but in reversing it.² The clinical attachment loss seen in periodontal diseases can be manifested as pocket and recession accompanied with bone loss.

Marginal tissue recession is due to the displacement of the gingival margin apical to the cemento-enamel junction with exposure of the root surfaces to the oral cavity. It may be a common cause of concern for the patient for a number of reasons like esthetic considerations, root hypersensitivity or root caries. Numerous periodontal plastic surgical

Corresponding Author: Dr. Nidhi Yadav, Post Graduate Student, Department of Periodontics, ITS CDSR, Muradnagar, Ghaziabad. (M) 8587978004 Email: dmidhiyadav24@gmail.com

1. Professor & Head, Department of Periodontics, SDM College of Dental Sciences and Hospital, Dharwad, Karnataka.
2. PG Student, Department of Periodontics, I.T.S. CDSR, Muradnagar, Ghaziabad.
3. Associate Professor, Department of Periodontics, I.T.S CDSR, Muradnagar, Ghaziabad.
4. Professor And Head, Department of Periodontics, I.T.S CDSR, Muradnagar, Ghaziabad.

procedures have been proposed in gingival recession treatment with varying predictability and success rates. One of the most widely employed procedures to cover denuded roots is the coronally advanced flap (CAF) procedure.³ The predictability can be increased by combining CAF with other regenerative techniques such as a connective tissue graft, enamel-matrix derivative, synthetic allograft, autologous platelet concentrates including platelet-rich fibrin (PRF) etc.

It has been reported that molars with furcation involvement, caused by periodontitis, have a higher rate of periodontal breakdown and respond less favorably to periodontal therapy than molars without furcation involvement or single-rooted teeth.⁴ This can be explained by an anatomy that impedes accessibility for individual oral hygiene in the molar region and professional root debridement.⁵ Multiple approaches have been used to resolve furcation defect including autografts, demineralized freeze-dried bone allografts (DFDBAs), bovine-derived xenografts, barrier membranes, and combinations of membranes and bone grafts.⁶ Although these regenerative materials are still used today, the introduction of biomimetic agents, such as enamel matrix derivatives, platelet rich plasma (PRP), platelet-derived growth factor, and bone morphogenetic proteins, has given new promise for better outcomes in furcation treatment.

Platelet-rich fibrin is a second generation platelet concentrate and is defined as an autologous leukocyte and platelet-rich fibrin biomaterial. It was first developed by Choukroun et al (2001).⁷ Unlike other platelet concentrates like PRP, this technique does not require anticoagulants nor bovine thrombin or

any other gelifying agent. PRF is a strictly autologous fibrin matrix containing a large quantity of platelet and leukocyte cytokines.

The crux of PRF synthesis lies in the attempt to accumulate platelets and release cytokines in a fibrin clot. The PRF clot is yielded by a natural polymerization process during centrifugation, and its natural fibrin architecture seems responsible for a slow release of growth factors (such as transforming growth factor 1β , platelet derived growth factor and vascular endothelial growth factor) and matrix glycoproteins (thrombospondin-1) during ≥ 7 days.

PRF promotes angiogenesis because as it has low thrombin level optimal for the migration of endothelial cells and fibroblasts. PRF entraps circulating stem cells due to its unique fibrin structure. This property of PRF finds application in healing of large osseous defects where there is migration of stem cells differentiating into osteoblast phenotype. PRF also helps in facilitating adhesion and spreading of cells, regulates gene expression of growth factors, growth factor receptors, proteins, and determines the outcome of a cell's response to growth factors due to the presence of collagen, fibronectin, elastin, other non-collagenous proteins, and proteoglycan in the extracellular matrix of PRF.⁸

PRF in various surgical procedures like, degree II furcation,⁹ sinus floor augmentation during implant placement,¹⁰ with coronally displaced flap in multiple gingival recessions¹¹ and in facial plastic surgery procedures¹² have been shown to provide promising results.

This report presents a case of single gingival recession treated by combined CAF-PRF

novel technique and a case of grade II furcation defect treated with PRF and bone graft.

Case 1

PRF in Gingival Recession

A 32-year-old male was referred by his general dentist for an evaluation of recession over the buccal prominence of the maxillary left canine. At the time of presentation, clinical examination revealed 4 mm of clinical attachment loss. The distance between the cemento-enamel junction and gingival margin was 2 mm and the distance between the gingival margin and the base of the pocket was 1 mm. (Fig.1)

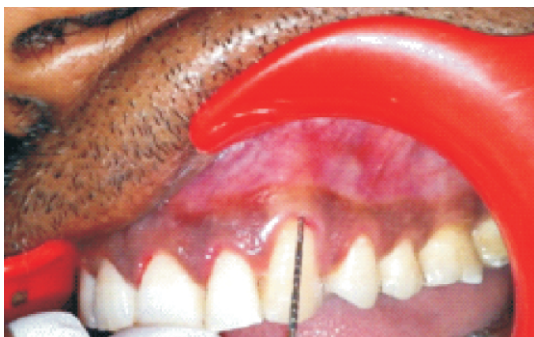

Fig. 1: Class I Recession in relation to canine.

Pre Surgical Therapy

The surgical procedure was explained to the patient and the informed consent obtained. Preparation of the patient included scaling and root planing of the entire dentition and oral hygiene instructions. The following parameters were recorded before and after surgery.

Probing Pocket Depth

Gingival recession (GR), by measuring the distance between the cemento – enamel junction (CEJ) to the free gingival margin.

PRF Preparations

The PRF was prepared in accordance with the protocol developed by Choukroun et al.¹³ The

patient's venous blood sample was taken before surgery in a 10 ml glass test tube without anticoagulant and centrifuged at 3000rpm for 10 minutes.

The resultant product consist of 3 layers

- Top most layer consisting of acellular PPP
- PRF clot in the middle
- RBCs at the bottom

Because of the absence of an anticoagulant, blood begins to coagulate as soon as it comes in contact with the glass surface. Therefore, for successful preparation of PRF, speedy blood collection and immediate centrifugation before the clotting cascade is initiated, is absolutely essential. PRF can be obtained in the form of a membrane by squeezing out the fluids in the fibrin clot. (Fig. 2)

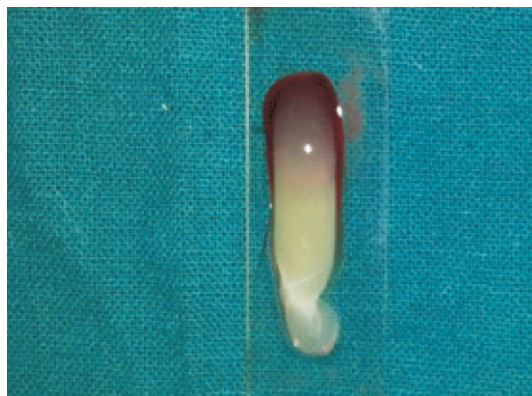


Fig. 2 : Platelet rich fibrin separated from RBC clot

Surgical Procedures

The concept of coronally advanced flap was introduced by Pini Prato et al.¹⁴ Following induction of local anaesthesia, the exposed and the intra sulcular root were gently planed with Gracey curette 7-8 to reduce root convexity. Immediately after this the root surface was washed with water spray for 60 seconds. The horizontal were made mesial and distal to the defect at the level of CEJ to the adjoining tooth terminated not less than 0.5mm away from the gingival margin of

adjacent teeth. Two oblique incisions were carried out from the mesial and distal extremities of the horizontal incisions. An intrasulcular incision was made connecting the horizontal incision. (Fig. 3) A full thickness flap was raised towards the mucogingival junction. Then a partial thickness was performed to a level that would permit adequate coronal positioning of the flap (Fig. 4). The root surface was carefully debrided using hand instrument. The PRF membrane was placed over the denuded root and stabilized (Fig. 5). The flap was slid to completely cover the membrane and secured using interrupted suture (Fig. 6).

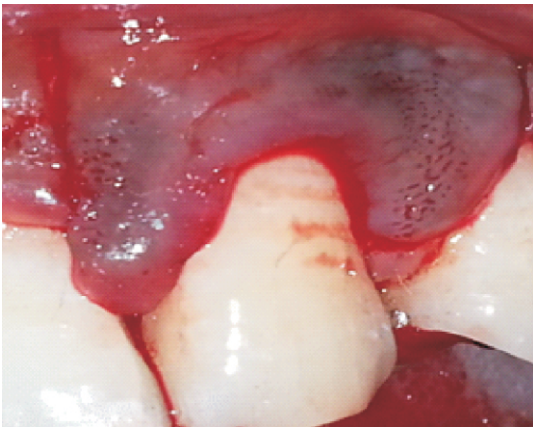


Fig. 3: Incisions given

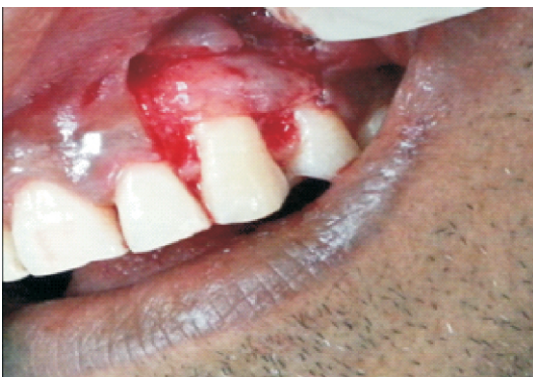

Fig. 4: Flap reflected

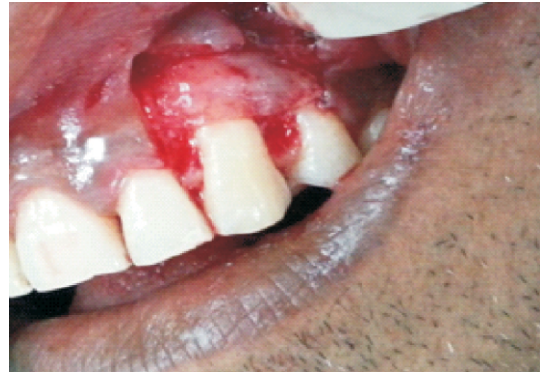

Fig. 5: PRF placed

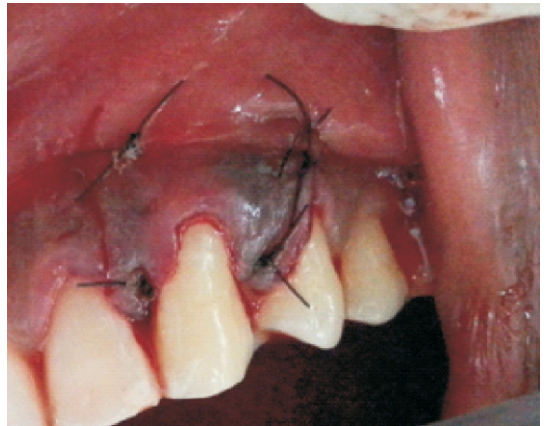


Fig. 6: Flap coronally displaced and sutured

Post Operative Care

Patients were placed on 0.12% chlorhexidine digluconate mouthrinse for four weeks. Systemic antibiotics were prescribed and advised to follow routine post-operative periodontal mucogingival instructions, with minor modifications. They were warned to avoid pulling on their lips to observe the surgical site. The surgical site was repacked after 1 week. Both dressings and sutures were removed 10 days after surgery.

Results

The patient was examined weekly up to 1 month after surgery and then at 3 months. Soft tissues healed within normal limits, and no gingival recession was noted after treatment (Fig. 7).

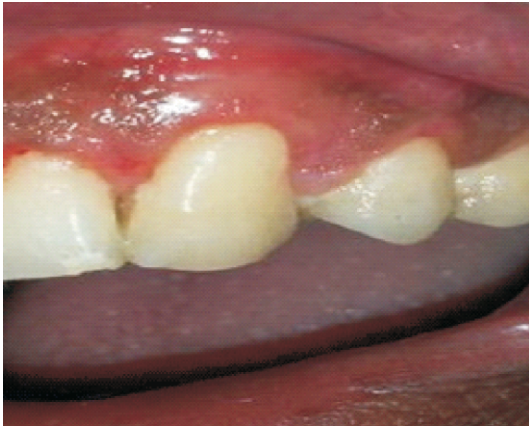

Fig. 7: Healing after 3 months

Case 2

PRF in Grade II Furcation

A 36-year-old female patient presented with mild pain and sensitivity of a lower left back tooth. The probing pocket depth (PPD) on the mid-buccal aspect of the tooth #36 (first molar) was 7 mm, while the clinical attachment level (CAL) was 8 mm, without tooth mobility. A Grade II furcation involvement was noted on the buccal side of #36 with a horizontal probing depth (PD) of 4 mm detected using Naber's probe. The tooth was vital. A periapical radiograph was taken using the standardized techniques, which revealed the presence of radiolucency in the furcation area of tooth #36. After a thorough Phase I therapy using ultrasonic scaler and standard Gracey curette, reevaluation was done after 8 weeks. The mid buccal PD of tooth #36 was 5 mm and the CAL was 6 mm. The horizontal PD in the furcation showed no change, with the persistence of Grade II furcation from the buccal side. Therefore, regenerative periodontal surgery using autologous PRF was planned, and informed consent was obtained for the same.

PRF Preparations

PRF was prepared in accordance with the

protocol developed by Choukroun et al¹³ as described above.

Surgical Procedure

After induction of local anesthesia, buccal vertical and sulcular incisions were made, and mucoperiosteal flaps reflected (Fig. 8). Meticulous defect debridement and root planing were carried out using area specific curettes. Bone graft was introduced into the furcation defect (Fig. 9) and then PRF membrane was placed over it (Fig. 10). The mucoperiosteal flaps were repositioned and secured in place by sling sutures by using 4-0 non-absorbable black silk (Fig. 11).

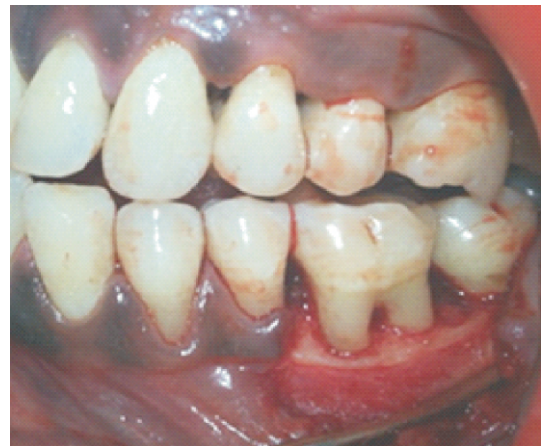

Fig. 8 : Grade II Furcation Involvement in mandibular molar

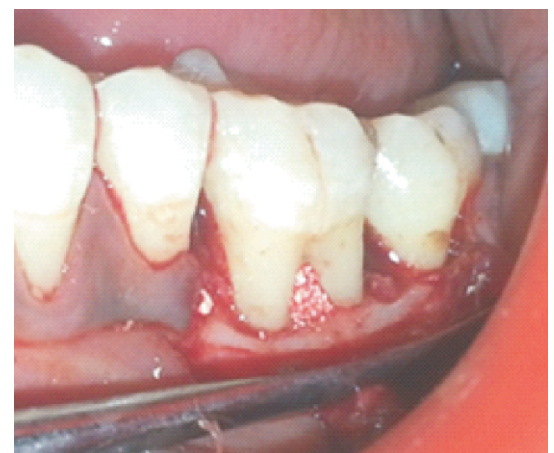


Fig. 9 : Bone Graft placed

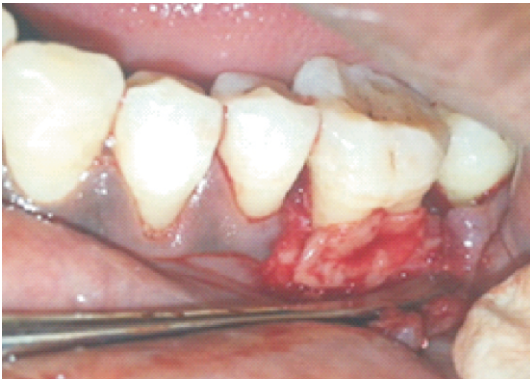

Fig. 10 : PRF membrane placed

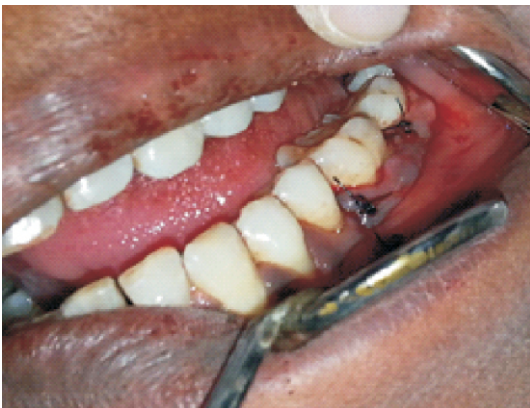

Fig. 11: Flap sutured

The surgical area was protected and covered with periodontal dressing. Postoperative instructions were given, and the patient was prescribed amoxicillin 500 mg t.i.d and paracetamol 500 mg T.I.D for 5 days. The sutures were removed after one week. Surgical wounds were gently cleansed with 0.2% of chlorhexidine digluconate, and patients were given instructions for gentle brushing with a soft toothbrush. Healing was reviewed in subsequent visits at 1, 3, and 6 months.

Results

The patient was examined weekly up to 1 month after surgery and then at 3 and 6 months. Soft tissues healed within normal limits, and no gingival recession was noted after treatment. Re-examination at 6 months after the periodontal surgery revealed

reduction in PPD (from 7 mm to 3 mm) and CAL (from 8 mm to 4 mm), with no sign of bleeding on probing and significant radiographic bone formation in the Grade II furcation defect.

Discussion

The aim of periodontal therapy is to arrest and control the periodontal infection and ultimately regenerate lost periodontal structures. The present paper evaluates the clinical efficacy of PRF in the treatment of Grade II furcation defect and Millers Class 1 gingival recession. The uneventful healing in the patients was in agreement with the findings of previous studies, thus supporting the excellent ability of autologous PRF to enhance periodontal wound healing. PRF afforded a great improvement in soft and hard tissue regeneration. The findings in the presented cases were in accordance with those of previous studies done by Pradeep *et al.*⁹ in the treatment of mandibular Grade II furcation and those of Aroca *et al.*¹⁵ in the treatment of multiple adjacent gingival recession. A report of clinical trails comparing the growth factors content of PRF and PRP was presented by Dohan and Diss at the second international Symposium on growth factors held in May 2005.¹⁶ Combining the growth factors has been shown to accelerate bone repair and promote fibroblast proliferation, and increase tissue vascularity, rate of collagen formation, mitosis of mesenchymal stem cells and endothelial cells, as well as osteoblasts, playing key roles in the rate and extent of bone formation. This activity, together with increased vessel ingrowth, is mediated by PDGF and TGF.¹⁷

Chang *et al.*¹⁸ conducted a study to present the clinical and radiographic changes of a patient with periodontal intrabony defects treated

with PRF. From a clinical and radiologic point of view at 6 months after surgery, the use of PRF as the sole grafting material seems to be an effective modality of regenerative treatment for periodontal intrabony defects. Pradeep et al¹⁹ conducted a study to explore the clinical and radiographic effectiveness of autologous PRF v/s PRF+HA (Hydroxyapatite) in treatment of intrabony defects in chronic periodontitis subjects. It resulted in significant improvements of clinical parameters compared with baseline. HA when added to PRF increases the regenerative effects observed with PRF in the treatment of human three wall intrabony defects.

The current case report assesses the clinical and radiographic parameters useful for evaluating the effect of autologous PRF on soft and hard tissue. In addition to the claimed benefits of using the PRF membrane in soft tissue wound healing, our results show the beneficial effects of using a PRF membrane for root coverage procedures. PRF preparation is simple, easy, fast, and cost-free, without the use of any anticoagulant. It causes sustained release of growth factors. Therefore, PRF is considered the leader in fibrin technology.

Conclusion

Due to its peculiar properties, the natural fibrin biomaterial PRF has great potential for surgical wound healing. PRF has been shown to be an effective regenerative material in the management of Grade II furcation, displaying greater reduction in pocket depths and gain in clinical attachments with significant radiographic evidence of bone fill. Similarly, for the treatment of multiple gingival recessions, PRF can be considered as a viable cost-effective option.

References

1. Caffesse RG, Mota LF, Morrison EC. The rationale for periodontal therapy. *Periodontol* 2000. 1995 Oct;9:7–13.
2. Needleman I, Tucker R, Giedrys-Leeper E, Worthington H. A systematic review of guided tissue regeneration for periodontal infrabony defects. *J Periodontol Res*. 2002 Oct;37(5):380–8.
3. Wennström JL, Zucchelli G, Pini Prato. *Mucogingival Therapy – Periodontal Plastic Surgery*. Lindhe's Clinical Periodontology and Implant Dentistry. 5th ed. 955
4. Goldman MJ, Ross IF, Goteiner D. Effect of periodontal therapy on patients maintained for 15 years or longer. A retrospective study. *J Periodontol* 1986;57:347-53.
5. Fleischer HC, Mellonig JT, Brayer WK, Gray JL, Barnett JD. Scaling and root planing efficacy in multirrooted teeth. *J Periodontol* 1989;60:402-9.
6. Simonpietri-C JJ, Novaes AB Jr., Batista EL Jr., Filho EJ. Guided tissue regeneration associated with bovine-derived anorganic bone in mandibular Class II furcation defects. 6-month results at re-entry. *J Periodontol* 2000;71:904-11.
7. Dohan DM, Choukroun J, Diss A, Dohan SL, Dohan AJ, Mouhyi J, Gogly B. Platelet-rich fibrin (PRF): a second-generation platelet concentrate. Part II: platelet-related biologic features. *Oral Surg Oral Med Oral Pathol Oral Radiol Endod* 2006; 101: e45-50.
8. Chandran P, Sivadas A. Platelet-rich fibrin: Its role in periodontal regeneration. *The Saudi Journal for Dental Research* 2014;5:117-22.
9. Sharma A, Pradeep AR. Autologous platelet-rich fibrin in the treatment of mandibular degree II furcation defects: A randomized clinical trial. *J Periodontol* 2011;82:1396-403.
10. Mazor Z, Horowitz RA, Del Corso M, Prasad HS, Rohrer MD, Dohan Ehrenfest DM. Sinus floor augmentation with simultaneous implant placement using Choukroun's platelet-rich fibrin as the sole grafting material: a radiologic and histologic study at 6 months. *J Periodontol*. 2009;80(12):2056-64.
11. Del Corso M, Sammartino G, Dohan Ehrenfest DM. "Clinical evaluation of a modified coronally advanced flap alone or in combination with a platelet-rich fibrin membrane for the treatment of adjacent multiple gingival recessions: a 6-month study". *J Periodontol*. 2009;80:1694-7.

12. Sclafani AP. Applications of platelet-rich fibrin matrix in facial plastic surgery. *Facial Plast Surg* 2009;25(4):270-6.
13. Choukroun J, Adda F, Schoeffler C, Vervelle A. A opportunité' in paroiimplantology: the PRF. *Implantodontie* 2001;42:55-62. (French)
14. Pini Prato GP, Baldi C, Pagliaro U, Nieri M, Saletta D, Rotundo R, Cortellini P. Coronally advanced flap procedure for root coverage. Treatment of root surface :Root planning v/s Polishing. *J Periodontol* 1999;70:1064-76.
15. Aroca S, Keglevich T, Barbieri B, Gera I, Etienne D. Clinical evaluation of a modified coronally advanced flap alone or in combination with a platelet-rich fibrin membrane for the treatment of adjacent multiple gingival recessions: A 6-month study. *J Periodontol* 2009;80:244-52.
16. Dohan D, Diss H. Platelet rich plasma versus Platelet rich fibrin (PRF): Comparison of growth factor content and osteoblast proliferation and differentiation in the cell culture. In report of second international symposium on growth factors. *Implantodontic* 2005;14:116-25.
17. Lozada JL, Caplanis N, Proussaefs P, Willardsen J, Kammeyer G. Platelet rich plasma application in sinus graft surgery: Part I-Background and Processing Techniques. *J Oral Implantol* 2001;27:38-42.
18. Chang YC, Wu KC, Zhao JH. Clinical application of platelet-rich fibrin as the sole grafting material in periodontal intrabony defects. *J Dent Sci* 2011;6:181-8.
19. Pradeep AR, Bajaj P, Rao NS, Agarwal E, Naik SB. Platelet-Rich Fibrin Combined with a Porous Hydroxyapatite Graft for the Treatment of Three-Wall Intrabony Defects in Chronic Periodontitis: A Randomized Controlled Clinical Trial. *J Periodontol* 2012;82:340-7.

Source of Support: NIL

Conflict of Interest: None Declared