

Rehabilitation of Resorbed Mandibular Ridge with Implant Supported Overdenture- A Clinical Report

Mittal R¹, Saxena D², Rao S¹, Kumar M¹

Abstract:

Statement of Problem: Complete denture rehabilitation can restore a patient's appearance and perceived social role, but many edentulous patient experience problems with their dentures, especially lack of stability and retention, together with a decrease of chewing ability and continued alveolar bone loss.

Aim: This article presents a case report where rehabilitation of mandibular resorbed ridge was done using 2 implant supported mandibular overdenture with ball attachment.

Materials And Method: A 68 years old female reported with a chief complaint of old loosened and unstable mandibular denture. The patient also complaint of severe gagging and discomfort in previous maxillary denture. The patient was advised to have implant supported overdenture for mandibular ridge and metal palate maxillary complete denture.

Results: The patient was satisfied with the prosthesis in terms of retention, stability, function and esthetics. The patient's complaint of gagging was taken care of by metal denture and the retention and stability in lower ridge was enhanced by implant supported overdenture.

Conclusion: Edentulous patient may experience a wide range of denture problems, including functional complaints related to the mandibular denture. Implant overdenture treatment (IOT) is generally considered to be an effective treatment modality in these cases.

Keywords: Edentulism, implant supported overdenture, rehabilitation, resorbed ridge.

Introduction

When an edentulous patient presents for treatment, the usual treatment modalities include a conventional removable complete denture. Complete denture rehabilitation can restore a patient's appearance, but other aspects of impaired oral functions may not be fully compensated.¹ Stability and retention of lower complete denture is well recognized as a potentially difficult treatment to achieve. Looseness and discomfort are the most frequent complaints

reported by patients. Many concepts have been put forward to increase stability and retention of mandibular complete denture including the mechanical principles^{2,3}, biometric guides⁴ etc. These techniques have been challenged and found insufficient. These techniques fail to restore function, aesthetics and comfort in patient with severely atrophic mandibular ridges (Atwood's Class V).⁵ Implant overdenture treatment (IOT) is generally considered to be an effective treatment modality in these cases.⁶

Corresponding Author :Dr. Rohit Mittal, PG Student, Department of Prosthodontics, D.J College of Dental Sciences and Research, Modinagar (UP) (M) +91-9868000377 E-mail: dr_rohitmittal@yahoo.in

1. PG Student, Department of Prosthodontics, D.J College of Dental Sciences and Research, Modinagar (UP)
2. Reader, Department of Prosthodontics, D.J College of Dental Sciences and Research, Modinagar (UP)

The feasibility of implant-supported overdentures was first tested at the University of Toronto, in early 1980's. Early positive observations lead to further studies establishing the efficacy and effectiveness of implant supported overdentures. An implant supported mandibular overdenture (ISO) with two implants is a simple treatment option for edentulous patients. Since the past 20 years, a variety of options have become available for retention of these implant retained prosthesis e.g. Magnets, clips, bars and ball attachments. Many reports on patient – base assessment of the outcome and functional effects of such therapy have shown greater patient satisfaction, comfort, stability, better chewing and speaking performance, higher jaw closing force and less residual ridge resorption as compared to the conventional mandibular dentures.⁶

This article presents a case report where rehabilitation of mandibular resorbed ridge was done using two implant supported mandibular overdenture with ball attachment.

Case Report

A 68 years old female reported to the Department of Prosthodontics, D J College of Dental Sciences and Research, Modinagar with a chief complaint of old loosened and unstable mandibular denture. The lower ridge was highly resorbed while the upper ridge was clinically acceptable. The patient also complaint of severe gagging and discomfort in previous maxillary denture. The patient was advised to have implant supported overdenture for mandibular ridge and metal palate maxillary complete denture. (Fig. 1)

Procedure

A detailed clinical examination was done and her previous dentures were evaluated for stability and retention. The old denture was

found to be unstable and unretentive. The lower ridge was highly resorbed as told earlier and the upper ridge was fine (Fig. 2). The patient had gagging because of the thickness of acrylic in upper denture.



Fig. 1: Extra-oral pre operative photograph of the patient

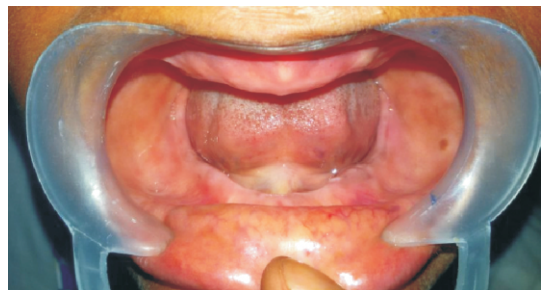

Fig. 2: Intra-oral pre operative photograph

- Primary impressions were made using impression compound (DPI Pinnacle functional impression compound) with edentulous stock trays.
- Closely fitting custom tray were fabricated and the border moulding was performed with low fusing type I impression compound, green stick (DPI Pinnacle tracing sticks) to represent muscle activity, recording functional depth and width of sulcus.
- The final wash impression was made with zinc oxide eugenol paste (DPI impression paste) and master cast was poured with

dental stone (Gypstone, Type III). Acrylic spacer was adapted on upper cast.

- The upper cast was duplicated in reversible hydrocolloid material, agar-agar (Bego-Castrogel), and poured in investment (refractory cast) (Neoloy Products, USA).
- A wax pattern for the metal framework was then made and the casting was done.(Fig.3) The metal framework was finished, polished and tried in the patient's mouth.(Fig. 4)
- The maxillary temporary denture base was completed using self cure acrylic resin (DPI Rapid Repair) and the occlusal rim was then fabricated.
- The lower temporary denture base and occlusal rim was fabricated in conventional manner.
- Tentative jaw relations and facebow transfer was then done and teeth setting was done on the articulator. Dentures were tried in patient's mouth.
- The trial dentures were then waxed up and processed in heat cure acrylic resin (DPI). After finishing and polishing, the dentures were inserted in patient's mouth for corrections and an appointment for implant surgery was given.
- Implants (Alpha- Bio) (4.2×10 mm) were inserted bilaterally in the mandibular canine region after marking the implant site using indelible pencil (Fig. 5).
- After 3 months of healing, gingival formers and subsequently ball abutments were placed.
- The abutment site was marked with indelible pencil in patient's mouth and these markings were transferred to lower denture (Fig. 6). The denture was relieved from that area and metal encapsulator was

incorporated and then again tried on to the abutment for proper fit.

- Then O ring was placed and the dentures were evaluated for fit, retention and stability. Patient was recalled after one week, 3 weeks, 3 months, 6 months for further evaluation (Fig.7 and Fig. 8).



Fig. 3: Fabrication of wax pattern

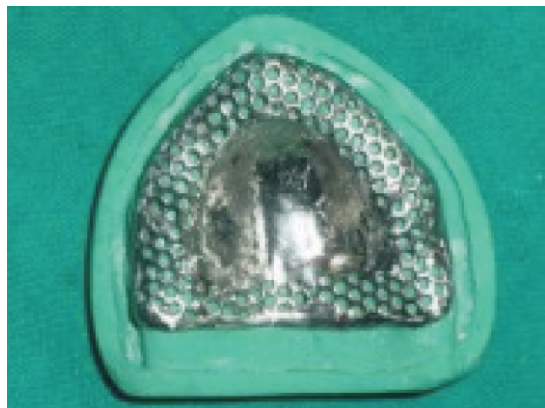

Fig. 4: Finished and polished metal framework

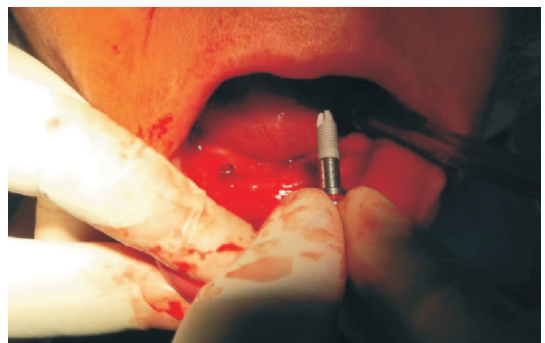


Fig. 5: Implants placed

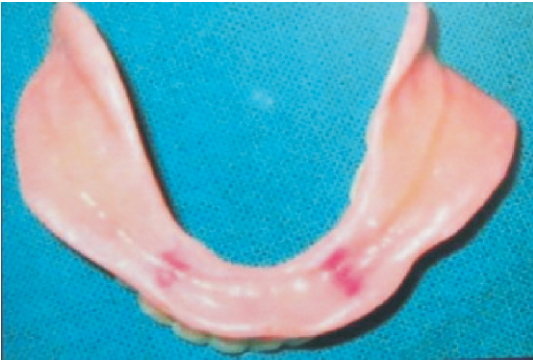

Fig. 6: Markings transferred to mandibular denture

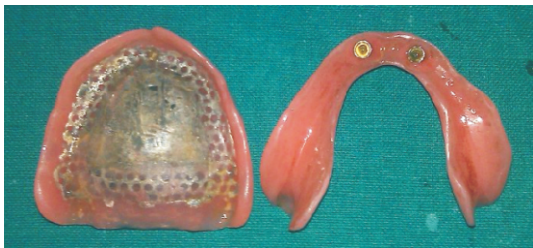

Fig. 7: Intaglio surface of final dentures




Fig. 8 : Post insertion

Discussion

The goal of modern dentistry is to restore the patient to normal function, speech, health and aesthetics, regardless of the atrophy, disease, or injury of the stomatognathic system. Dental implants are increasingly used as suitable prosthodontic substitutes for natural teeth. Mandibular implant overdenture treatment has gained considerable acceptance. It has effectively replaced the tooth-borne version of this treatment for many practitioners and has

been recommended as the new standard-of-care treatment when compared with conventional mandibular complete dentures.^{7,8} Many reports on patient – base assessment of the outcome and functional effects of such therapy have shown greater patient satisfaction, comfort, stability, better chewing and speaking performance, higher jaw closing force and less residual ridge resorption as compared to the conventional mandibular dentures.⁹

Conclusion

Mandibular complete overdenture treatment uses a removable completedenture that overlies retained teeth, tooth roots, or dental implants.⁸ Severe loss of alveolar bone often presents a challenge in fabrication of prosthesis.¹⁰ Implant supported overdenture is the treatment of choice in such cases. This case was evaluated and treated keeping in mind the DE VAN principle of PRESERVATION. The patient was satisfied with the prosthesis in terms of retention, stability, function and esthetics. The patient's complaint of gagging was taken care of by metal denture and the retention and stability in lower ridge was enhanced by implant supported overdenture.

References

1. Naert I. Prosthetic aspects and patient satisfaction with two implant retained mandibular overdentures: A 10 year randomized clinical study. *Int J Prosthodont* 2004;17:40.
2. Wright C, Swartz W, Godwin W. Mandibular denture stability: a new concept. *Overbeck*;1961.
3. Lammie G. Aging changes and the complete lower denture. *J Prosthet Dent* 1956;6:450-64.
4. Pound E. Esthetic dentures and their phonetic values. *J Prosthet Dent*. 1951;1:98-111.
5. Atwood Da. Postextraction changes in the adult mandible as illustrated by microradiographs of midsagittal sections and serial cephalometric roentgenograms. *J Prosthet Dent*. 1963;13(5); 810-24.

6. Cune M, Kampen F V, Bilt AV D, Bosman F. Patient satisfaction and preference with magnet, bar-clip, and ball-socket retained mandibular implant overdentures: a cross-over clinical trial. *INT J Prosthodont*:2005;18,99-100.
7. Burns DR. Mandibular implant overdenture treatment: consensus and controversy. *J Prosthodont* 2000;9(1):37-46.
8. Burns DR. The mandibular complete denture. *Dent Clin NAm* 48 (2004) 603-3.
9. Walton J. N. A Randomized Clinical Trial Comparing Two Mandibular Implant Overdenture Designs: 3-Year Prosthetic Outcomes Using a Six-Field Protocol. *Int J Prosthodont*: 2003;16,255-60.
10. Bencharit S, Sacco DS, Border MB, and Barbaro CP. Full Mouth Rehabilitation with Implant-Supported Prosthesis for Severe Periodontitis: A Case Report. *Open Dent J*. 2010; 4: 165-71.

<p>Source of Support: NIL Conflict of Interest: None Declared</p>
