

# Basal Cell Adenocarcinoma of Palate- A Case Report

Sharma M<sup>1</sup>, Sharma GK<sup>1</sup>, Bajaj P<sup>2</sup>, Sulatan KT<sup>3</sup>

## Abstract:

Basal cell adenocarcinoma (BCAC) of minor salivary gland is a rare salivary gland carcinoma, which have occasional reports in English literature. Due to insufficient data, this entity is of great concern as it should be differentiated from other basaloid tumors like basal cell adenoma, adenoid cystic carcinoma and basaloid squamous cell carcinoma. Here we report a case of basal cell adenocarcinoma of palate arising from minor salivary glands with special emphasis on histopathological parameters of diagnosis.

**Keywords:** Adenocarcinoma, minor salivary gland, Palate, Basal Cell Adenoma.

## Introduction

Basal cell adenocarcinoma (BCAC) is a rare neoplasm of salivary glands and affects specifically parotid and other major salivary glands.<sup>1</sup> BCAC has limited reports in English literature. Due to insufficient data in literature and rare incidence of this tumor, it is often difficult to diagnose this entity.<sup>2</sup> Ellis and Gnepp defined the histopathologic features of BCAC in 1988 and delineate its existence from other basaloid tumors like basal cell adenoma (BCA), adenoid cystic carcinoma (ACC) and basaloid squamous cell carcinoma (BSCC). Basal cell adenocarcinoma comprises of 1.6% of all salivary gland neoplasms and 2.9% of malignant salivary gland neoplasms.<sup>3</sup> BCAC is considered as malignant counterpart of basal cell adenoma with invasive growth pattern and destructive nature.

This article exemplifies a rare case of BCAC of posterior palate arising from minor salivary glands in 48 year old male patient with special

emphasis on its diagnostic clinicopathologic features.

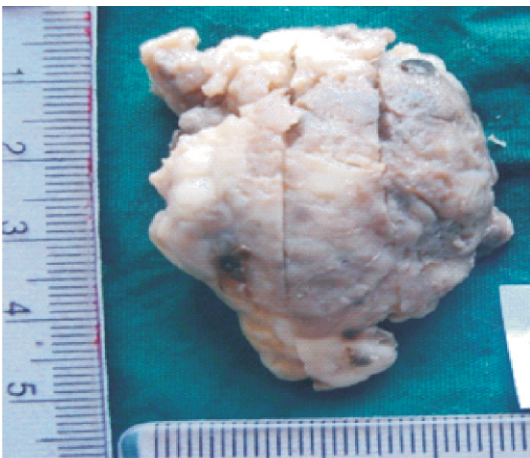## Case Report

A 48 year old male presented to department of oral pathology in January 2013 with a seven months history of a persistent swelling on his right side of posterior palate. During this period patient has no other symptoms of nasal sinus obstruction and dysesthesias. A unilateral firm smooth surfaced mass was seen on right side at the junction of hard and soft palate. Mass was 5x3 cm in size and extended from right second premolar to 1 cm beyond right third molar, swelling was tender on palpation. There was no sinus opening or ulceration associated. CT scan image revealed an enhancing soft tissue mass with limited palatal bone resorption. On the basis of clinical parameters a possible diagnosis of salivary gland neoplasm specifically mucoepidermoid carcinoma was given. An excisional biopsy was sent for histopathologic examination (Fig.1). Microscopically the

**Corresponding Author :** Dr. Manish Sharma, Reader, Oral Pathology, GND Dental College & Research Institute Sunam, Punjab.  
(M): +91-7696032790 E mail: drmanishsharma2007@gmail.com

1. Reader, Department of Oral & Maxillofacial Pathology. GND Dental College & Research Institute Sunam, Punjab.
2. Professor & Head, Department of Oral & Maxillofacial Pathology. Bhojia Dental College Baddi , Himanchal Pradesh.
3. Reader, Department of Oral & Maxillofacial Surgery. Purvanchal Institute of Dental Sciences Gorakhpur, Uttar Pradesh.

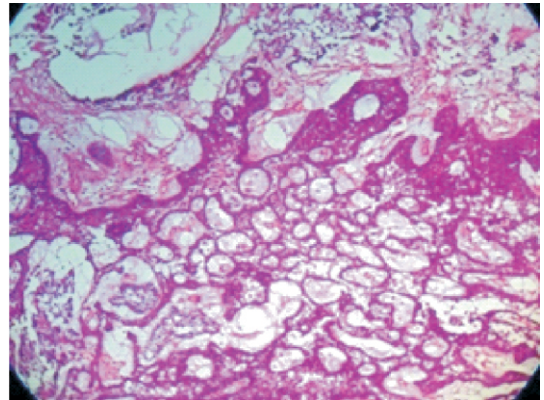
lesion showed sheets and strands of proliferating basaloid cells having hyperchromatic nuclei. Lesion showed characteristic tubulo-trabecular, cribriform and solid patterns of basal cells (Fig. 2 and 3). The bulk of solid nests and trabeculae were formed by two types of basal cells, peripheral dark stained basaloid cells with palisadation and central pale basophilic cells (Fig. 4). Lesion was devoid of encapsulation and penetrating deep to the edges into muscles. The connective tissue stroma was collagenous and vascular. Prominent atypia and mitotic figures were seen in few basal cells. Perineural infiltration was not much evident. Based upon the clinicopathologic features final diagnosis of basal cell adenocarcinoma was established. A surgical excision with wide margin was performed to ensure complete removal of the lesion and patient has remained without recurrence since 14 months of his operation. No radiotherapy was implemented.



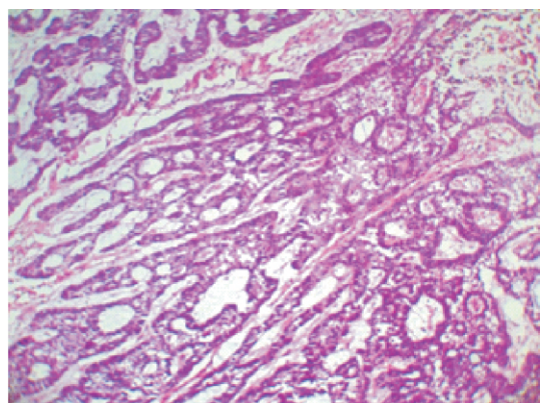
**Fig. 1:** Tissue specimen from right side of palate

### Discussion

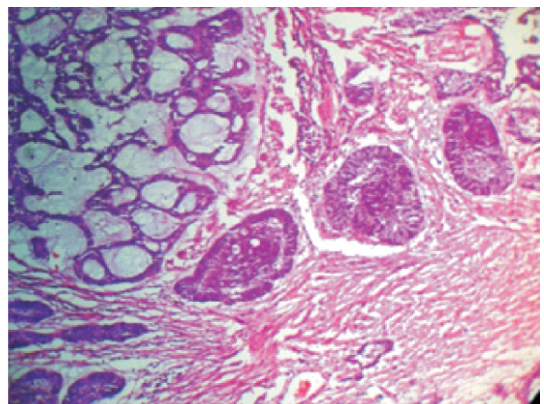
Basal cell adenocarcinoma of minor salivary glands is a comparatively rare slowly growing neoplasm with an infiltrating growth pattern.<sup>4</sup> Basal cell adenocarcinoma was classified as



**Fig. 2:** H& E stained section showing cribriform pattern with infiltrating margin



**Fig. 3 :** H& E stained section showing trabecular pattern.



**Fig. 4:** The solid pattern of basal cell adenocarcinoma. The tumor is composed of basaloid cells, which show two-cell morphologies and some palisadation at the periphery.

low grade tumor in WHO 2005 classification.<sup>5</sup> BCAC comprises of 1.6% of all salivary gland neoplasms and 2.9% of malignant salivary gland neoplasms.<sup>3</sup> BCAC is considered as

malignant counterpart of basal cell adenoma with invasive growth pattern and destructive nature. Due to fewer published data in English literature, it is difficult to distinguish this tumor from other basaloid tumors like basal cell adenoma and adenoid cystic carcinoma.<sup>2</sup>

The origin of BCAC is still unknown, but some authors propose it develop from preexisting basal cell adenoma while others believe it is a de novo lesion.<sup>6,7</sup> BCAC is supposed to originate from pluripotent ductal reserve cells.<sup>8</sup> The most of BCAC occur in parotid gland (90%), followed by submandibular and minor salivary glands rarely.<sup>2,8</sup> The age incidence in BCAC ranges from 24-73 years with a mean age incidence of 55.1 years.<sup>3</sup> In our case the age of patient was 48 years nearly to average age of occurrence. Each gender is equally affected. BCAC of minor salivary glands of palate clinically appear as asymptomatic swelling of longer duration.<sup>8</sup> Present case had seven months old swelling of palate with tenderness which may be due to infiltration of nerves by tumor.

Microscopically BCAC has four major patterns: tubulotrabeular, cribriform, solid and membranous.<sup>9,10</sup> All patterns usually have two types of basal cell population. Smaller cell with scant cytoplasm and dark nuclei and polygonal cells with eosinophilic cytoplasm and pale basophilic nuclei. The most common pattern is solid nests in collagenous stroma. Each nests vary in shape and size, composed of central polygonal cells and smaller peripheral cells with palisidation.<sup>2,10</sup> BCAC is difficult to differentiate from basal cell adenoma and adenoid cystic carcinoma.<sup>9</sup> BCAC consider as malignant counterpart of basal cell adenoma because most BCAC originate from preexisting basal cell adenoma. The diagnostic feature of BCAC is thought to

be infiltrative growth rather than pushing or multifocal growth (features of basal cell adenoma), neural invasion, vascular invasion and cellular atypia with mitosis.<sup>3</sup> Basal cell adenoma doesn't have these histopathological features except the pattern similarities. BCAC which are arises from preexisting basal cell adenoma may show diagnostic dilemmas, so caution should be taken by studying serial sections of tumor. Second differential diagnosis of consideration is adenoid cystic carcinoma due to the poorer prognosis. Major criterias to differentiate are -

- Presence of dark hyperchromatic angulated nuclei in ACC.<sup>6</sup>
- High mitotic index with necrosis in solid pattern in ACC.<sup>6</sup>
- Small lumens in cribriform pattern with thick interluminal wall and two cell population in ACC.<sup>8</sup>
- Zigsaw puzzle appearance of cells in solid pattern with peripheral palisidation in BCAC.<sup>8</sup>

Third lesion to distinguish is basaloid squamous cell carcinoma (BSCC) which shows squamous differentiation as major feature that involve mucosal epithelium.<sup>6</sup>

BCAC is considered as low grade malignancy with good prognosis. They are locally infiltrative and propensity to recur. Surgical excision with wide margin is primary approach to treat BCAC.<sup>9</sup> Radiotherapy is applicable for BCAC with invasion to neural and vascular elements. Metastasis is rare, only 10% in BCAC, if occur prognosis will be poor.<sup>4</sup>

### Conclusion

Basal cell adenocarcinoma is malignancy of low grade with favorable prognosis. Although it is a rare pathology, BCAC should be in

consideration of basaloid cell malignancies of salivary glands. They required local excision so need to be distinguish from adenoid cystic carcinoma and basaloid squamous cell carcinomas which needed aggressive clinical approach and usually metastasize. According to some studies the local recurrence rate of BCAC is 25-30 %.<sup>4</sup>

## References

1. Klima M, Wolfe K, Johnson PE: Basal cell tumors of the parotid gland. Arch Otolaryngol 1978, 104:111-6.
2. Jung MJ, Roh JL, Choi SH, Kim S Y, Lee SW, Cho KJ. Basal cell adenocarcinoma of the salivary gland: a morphological and immunohistochemical comparison with basal cell adenoma with and without capsular invasion. Diagnostic pathology 2013;8:171.
3. Sharma R, saxena S, bansal R .basal cell adenocarcinoma report of a case affecting submandibular gland. Journal of oral and maxillofacial pathology 2007; vol 11:issue 2; 56-9.
4. Farrell T, Chang YL. Basal cell adenocarcinoma of minor salivary glands. Arch Pathol Lab Med. 2007;131:1602-4.
5. Barnes L, Eveson JW, Reichart P, Sidransky D, eds. Pathology and genetics of tumors of head and neck. Lyon, france: IARC press; 2005. World health organization classification of tumors vol 9.
6. Jayakrishnan A, elmalah I, hussain K, odell EW. Basal cell adenocarcinoma in minor salivary glands. Histopathology 2003;42:610-4.
7. Luna M, Batsakis JG, Tortoledo ME, del Junco GW: Carcinomas exmonomorphic adenoma of salivary glands. J Laryngol Otol 1989, 103:756-9.
8. Peel RL, Seethala RR: Pathology of Salivary Gland Disease. In Salivary Gland Disorders Edited by: Myers EN, Ferris RL. Springer; 2007:449.
9. Parashar P, Baron E, Papadimitriou J, Ord R, Nikitakis N. Basal cell adenocarcinoma of the oral minor salivary glands: review of the literature and presentation of two cases. Oral Surg Oral Med Oral Pathol Oral Radiol Endod. 2007 ;103:77-84.
10. Ellis GL, Auclair PL, Basal cell adenocarcinoma. In: Rosai J, Sobin LH, eds. Tumors of the salivary glands. Washington, DC: armed forces institute of pathology; 1996: 257-67.

**Source of Support:** NIL  
**Conflict of Interest:** None Declared