

A Combination Prosthesis -Magnet Retained Lip Plumper- A Case Report

Dhanpal S¹, Chitturi RK², Bhasmey SR³, Mannava SP⁴

Abstract :

Acquired defects of the orofacial structures must be analysed as to the specific cause and the consequent objective of rehabilitation. Resection of tumors of the orofacial structures results in functional disability and cosmetic disfiguration which present a major challenge to the rehabilitation team. To restore functional efficiency and aesthetics in such instances by a prosthesis is often preferred over a surgical procedure. But such a device has to be made bulky resulting in increased weight and discomfort to the patient. However this can be overcome by fabricating two piece prosthesis. This paper discusses the prosthodontic rehabilitation of an acquired mandibular defect patient with conventional cast removable partial denture modified with magnetically attached lip plumper to provide lip support, prevent lip biting and improve the patient's oral competency.

Keywords: Mandibulectomy, Lip Plumper, Removable Partial Denture, Esthetics, Magnets.

Introduction

Odontogenic ameloblastoma (OA) of the jaws is found to be a rare neoplasm of oral cavity constituting 0.78 %. Within the oral cavity, its prevalence is 5 times more in the mandible than in the maxillae, with the molar region and the ascending ramus being the most affected areas¹.

Therapeutic management of oral carcinoma patients include extermination of the new growth and rehabilitation of the patient to normal function and form². Surgical excision of the lesion is the preferred route when compared to chemotherapy, radiation therapy, curettage and cryosurgery in case of oral cancer³. However surgical protocol may involve removing osseous elements which support intra and extra oral soft tissues. Hence oral cancer patients are often concerned about

post operative disfigurement, masticatory inefficiency, speech impairment, uncoordinated chewing, rotation and deviation of jaw during movements and parasthesia of the site. Therefore the primary challenge to the prosthodontist, while managing the post surgical defect of oral carcinoma patient is not only to restore the function with prosthesis but also to bring back the original facial form and esthetics. Many methods are employed to modify the basic prosthesis so that the contour of the face is maintained without making the former bulky and heavy.

A two piece device is more convenient and acceptable to the patient because it meets with the patient's needs at appropriate time. Improved instrumentation has offered magnets as suitable attachments for intra oral

Corresponding Author : Dr. Sravanthi D, Post Graduate Student, Department of Prosthodontics, Mamata Dental College, Khammam, Telangana. (M)+91-9866813676 **Email :** shravanthidhanpal@gmail.com

1. Post Graduate, Department of Prosthodontics, Mamata Dental College, Khammam.
2. Professor and Head, Department Of Prosthodontics, Mamata Dental College, Khammam.
3. Reader, Department Of Prosthodontics, Gitams Dental College, Vizag.
4. Consultant Prosthodontist, Indian Dental Academy, Hyderabad.

prostheses. Magnetic technology is constantly improving: currently available magnets based on Nd-Fe-B are small (which allows them to be incorporated into dentures) and have attractive forces that enable them to provide retention. Although magnets have disadvantage of being corroded in long term service, they are far superior to springs, suction cups, clips, and studs in medical applications⁴. This clinical report describes the procedure associated with the fabrication of a combination prosthesis which includes removable partial denture with magnet retained lip plumper.

Case Report

A 32 yr old male patient, name Balu Nayak reported to the department of Prosthodontics, Mamata Dental College with complaints of missing teeth and disfigured face. Patient gave a history of mandibular resection for intra oral growth followed by bone graft at NIMS Hospitals, Hyderabad. Extra oral examination revealed a 22cm post surgical scar, 6 cm below the right ear extending to 5cm beneath the left corner of his mouth. He also presented with 1.5cm deep mentolabial fold and puckering of chin (Fig. 1). On intra oral examination, there was loss of residual ridge and a saucer shaped defect extending from the mesial aspect of the right mandibular first molar to that of left mandibular first molar (Fig. 2). Anteriorly the labial sulcus was missing and mucosa of inner aspect of lower lip and that covering the alveolar ridge was at the same level. Labial frenum was missing, and edentulous space appeared shrunken and reduced. Support for the lower lip was lost and was pulled inside.

Full complement of maxillary arch and molars on the either side of the mandibular arch were present. Class I molar relation was observed.

The panoramic radiograph revealed that the base of the mandible was reconstructed with bone graft (Fig. 3). On enquiry patient revealed that a piece of bone was taken from right leg.

The intermaxillary space in the region of the surgical resection was excessive. To restore such large space would require a heavier prosthesis which might enhance resorption of the grafted area. In addition to excessive intermaxillary space, the skin over mentolabial fold was pulled inside due to cicatrization and presented disfigured appearance.

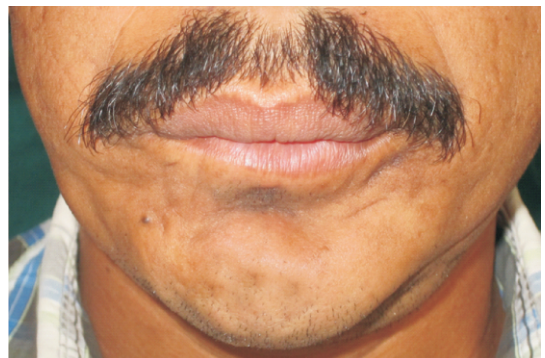

Fig. 1: Puckering of chin without prosthesis

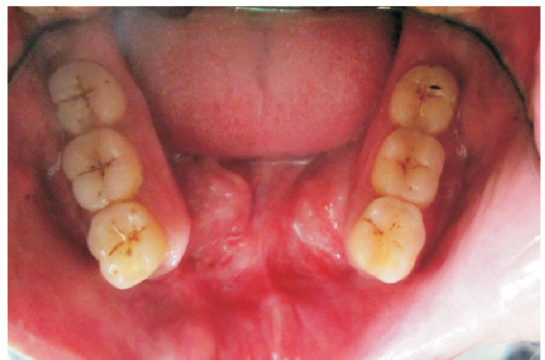

Fig. 2: Loss of residual ridge and saucer shaped defect.

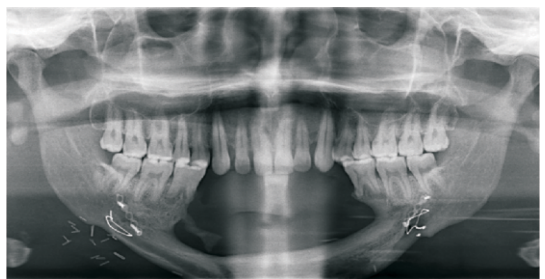


Fig. 3 : Panoramic radiograph revealing reconstruction with bone graft

Available treatment options to restore the missing teeth were a fixed partial denture, implant prosthesis and a removable partial denture. Although the first two options could result in an excellently stabilized prosthesis, they would not have provided lip support and restore normal facial profile. A removable prosthesis with a modified acrylic flange might provide the required support to the lower lip. A diagnostic wax build up was tried in increments in the intercanine region to assess its aesthetic affect. Patient's approval was sought. After the patient's acceptance was obtained, a treatment plan was made to restore edentulous area with six anterior teeth and left first premolar. Because of uneven resorption and healing of the residual ridge, a compromise in arrangement of lower teeth regarding the midline was made after informing the patient.

To provide the lip support the labial flange is needed to be modified without causing unfavourable sequelae either to the soft tissues or to the foundation. With this in mind, a single unit bulky labial flange was avoided and a sectional prosthesis jointed by magnets was planned. Magnets (MAGFIT DX-800 Dental Magnetic Attachment Aichi Steel Corporation, Aichi- Ken, Japan) used in this case had a Magnetic Field Leakage of 0.002T, and attractive force of 7.7N which has superior retentive force compared to other retentive aids. A sectional prosthesis would also have an advantage of easy retrieval whenever the patient would not need lip supporting component.⁵ Magnets were preferred over other attachment devices owing to their easy cleansability and simplicity, no difficulty during placement by the patient because of its automatic reseating nature, and long lasting retention even with number of cycles.⁴

Titanium alloy was chosen to provide metallic frame work of removable partial denture.

Diagnostic impressions were made with irreversible hydrocolloid (Zelgan 2002; Dentsply-India, Gurgaon, India) and initial survey was done. Mesial occlusal rests on 36 and 46 with embrasure clasps for 37, 38 and 47,48 were designed. Embrasure clasp assemblies in this design would also provide indirect retention. Because of restricted lingual sulcus in anterior region, lingual bar with extended minor connector over the ridge area and into labial sulcus was considered (Fig. 4).

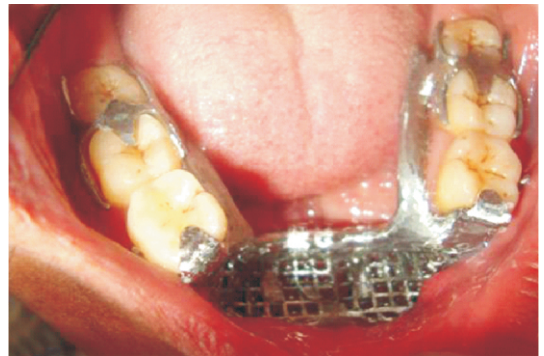

Fig. 4: Lingual bar with extended minor connector

This would provide enough surface for the acrylic portion of the labial flange and fixing of the magnet along with its yoke and outer lip (MAGFIT DX-800 Dental Magnetic Attachment Aichi Steel Corporation, Aichi- Ken, Japan). Keeper of the magnet assembly (MAGFIT DX-800 Dental Magnetic Attachment Aichi Steel Corporation, Aichi- Ken, Japan) would be in the plumper section (Fig. 5).

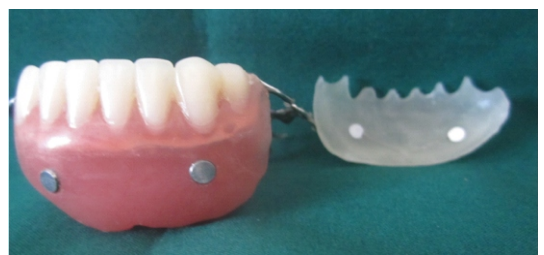

Fig. 5 : Magnets and magnetic keepers in to the denture base and template respectively

As per design occlusal rest seat preparation, guiding planes and abutment tooth modifications were included in mouth preparation before a final impression was made. A custom tray in acrylic resin was constructed on the diagnostic cast. The definitive cast was prepared from a dual impression of the mandibular arch with silicone impression material (AFFINIS Precious, Regular; coltene whaledent). Metal framework was fabricated and tried for retention, stability and comfort. Acrylization was done after necessary jaw relations and try-in. On insertion it was seen that only function could be restored but not the facial form (Fig. 6).



Fig. 6 : Frontal view after insertion of removable partial denture alone

Wax was added in increments on the labial surface of the definitive prosthesis until aesthetics was improved and accepted by the patient. Added wax was indexed in the putty which was further supported by dental plaster (Fig. 7).

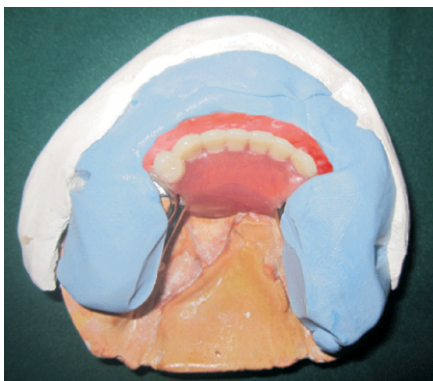


Fig. 7: Wax added in incremental is indexed by Putty index

Wax was removed and cold cure clear acrylic template was fabricated. Magnet keeper was incorporated in the template and magnets in the definitive prosthesis at equidistance from midline. Factor II Inc. A-2186 silicone elastomer (medical grade) was mixed in a 10:1 ratio by weight. Floccules, intrinsic strains, sealant, thixotropic agent were added in proportions until desired color and consistency were obtained. Care was taken to minimize air entrapment during mixing and the mix was loaded in the putty index and on to the template and placed against the prosthesis in situ on the master cast. Index was held until complete set of silicon material (Fig. 8). Modified partial denture (Fig. 9) was inserted to check for occlusion in centric, phonetics, and aesthetics (Fig. 10). The opinion on patient's immediate relative was also considered regarding aesthetics. Patient's approval was obtained.

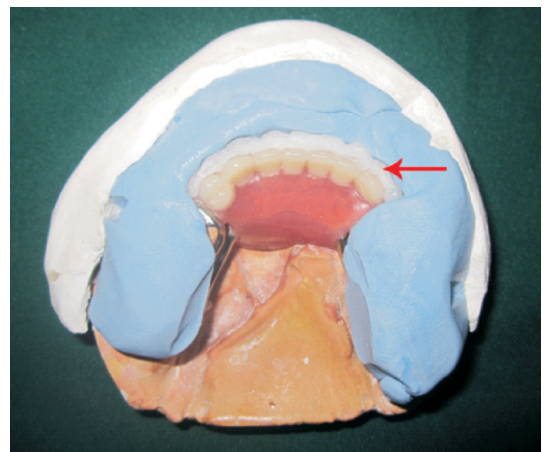


Fig. 8: Silicon material loaded within the putty index and placed against removable partial denture

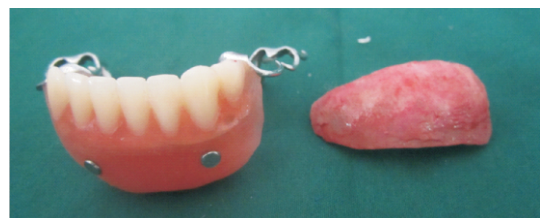

Fig. 9: Removable partial denture and lip plumper



Fig. 10: Frontal view of the patient with lip plumper prosthesis

86(2):137-42.

5. Chakravarthy R. Magnet Retained Sectional Lip Plumper Prosthesis For A Patient With Hemi-Mandibulectomy: A Clinical Report. *Journal of Clinical and Diagnostic Research* 2010 June; 4:2582-6.

Source of Support: NIL

Conflict of Interest: None Declared

Discussion

Surgical excision of oral lesions may lead to loss of bone and may cause facial disfigurement. In the reported case, the patient underwent a procedure where by mandibular teeth from 35 to 45 were extracted along with bulk of supporting bone. Discontinuity was repaired with fibula bone graft. Cicatrization and loss of teeth pulled mentolabial fold inward. Patient desired the oral function as well as facial appearance to be restored. A sectional prosthesis with silicon lip plumper attached with magnets was fabricated. This was the most economical way to meet the demands of functional efficiency, comfort, and aesthetics for such a clinical condition.

References

1. Martins RH, Rapoport A, Rosa MP. Histopathologic features and management of ameloblastoma: study of 20 cases. *Sao Paulo Med J.* 1999 Jul 1; 117(4):171-4.
2. Eugene N. Myers, MD and David E. Eibling, M. *Operative Otolaryngology: Head and Neck Surgery.* 2nd edition, Saunders Elsevier, 1997; Chapter 32.
3. Reichart PA, Philipsen HP, Sonner S. Ameloblastoma: biological profile of 3677 cases. *Eur J Cancer B Oral Oncol.* 1995 Mar; 31B(2):86-99.
4. Riley MA, Walmsley AD, Harris IR. Magnets in prosthetic dentistry. *J Prosthet Dent.* 2001 Aug;