



## Case Report

# Twinned lateral incisors

Neha Upadhyay<sup>1,\*</sup>, Inrajeet Singh<sup>2</sup>, Rakesh Mishra<sup>3</sup>

<sup>1</sup>Dept. of Oral and Maxillofacial Pathology, Chandra Dental College and Hospital, Barabanki, Uttar Pradesh, India

<sup>2</sup>Dept. of Oral Surgery, Chandra Dental College and Hospital, Barabanki, Uttar Pradesh, India

<sup>3</sup>Dept. of ENT, Hind Institute of Medical Sciences, Barabanki, Uttar Pradesh, India



### ARTICLE INFO

#### Article history:

Received 20-08-2022

Accepted 25-08-2022

Available online 05-09-2022

#### Keywords:

Anomaly

Double tooth

Twinning

Mid line shift

twin tooth

### ABSTRACT

Twinning is referred to the development of two separate teeth that arose from the complete separation of one tooth bud. The present paper discusses twinning in detail and attempts to differentiate twinning from gemination, fusion and concrescence.

This is an Open Access (OA) journal, and articles are distributed under the terms of the [Creative Commons Attribution-NonCommercial-ShareAlike 4.0 License](https://creativecommons.org/licenses/by-nc-sa/4.0/), which allows others to remix, tweak, and build upon the work non-commercially, as long as appropriate credit is given and the new creations are licensed under the identical terms.

For reprints contact: [reprint@ipinnovative.com](mailto:reprint@ipinnovative.com)

## 1. Case Report

A twenty-year-old male patient reported to the dental college with the complaint of irregular front teeth of the upper jaw. On clinical examination, a midline shift was observed in the maxillary arch along with an extra maxillary left lateral incisor. The both left lateral incisors showed up labially out of occlusion without proper contour and contact with the adjacent central incisor and each other. The patient had normal compliment of teeth for his age. [Figures 1 and 2] The orthopantomogram of the patient also revealed an extra maxillary left lateral incisor, relatively very similar in size and shape of both, was suggestive of a case of twinning involving maxillary left lateral incisor. [Figure 3]

Developmental disorders in the teeth are not uncommon and they may range from abnormalities starting as early as demarcation of the dental lamina to the anomalies of tooth germs in number, size and shape, extending to the abnormalities in the growth of the dental hard tissues (structure). Dental anomalies though largely congenital but

may also be idiopathic, inherited or acquired.<sup>1</sup>

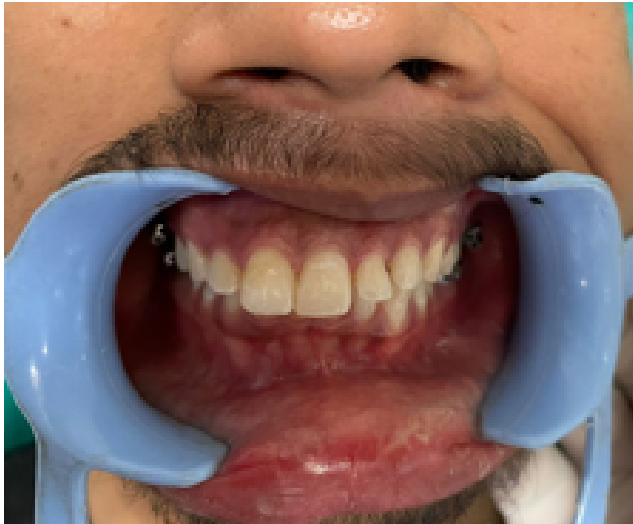The terms “twin teeth”, “fused teeth”, “connoted teeth”, “conjoined teeth”, “double formations” are commonly used to exemplify twinning, gemination and fusion. These anomalies together are one of the primary developmental disorders of the teeth.<sup>2</sup>

The aetiology of gemination, twinning along with fusion or concrescence remains largely unknown; however a key feature of the initiation of tooth development is the formation of dental placodes, which seems to initiate the formation of each tooth family. Whether the incisors, canine and premolars or molars are initiated from their own placodes remains to be demonstrated. Interactions between the surface epithelium and underlying mesenchyme have key functions in the formation of placodes. The balance of stimulatory and inhibitory signals is important in the initiation of the placode and the fine tuning of signaling affects the pattern of the teeth formed. When the placode grows larger than normal and is over activated, it may develop as supernumerary teeth and/or a larger teeth.<sup>3</sup>

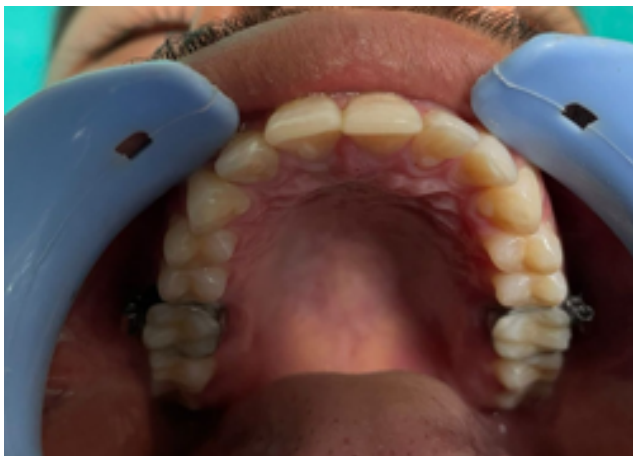Some of the suggested interferences which may occur during morpho differentiation of the tooth

\* Corresponding author.

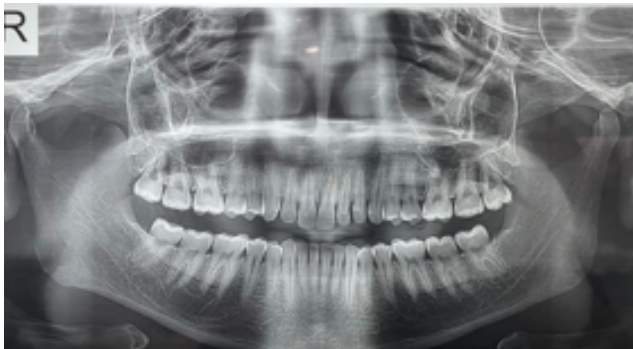E-mail address: [upadhyayaneha16@gmail.com](mailto:upadhyayaneha16@gmail.com) (N. Upadhyay).



**Fig. 1:** Showing midline shift towards right side in the maxillary arch.



**Fig. 2:** Showing midline shift towards right side in the maxillary arch along with two lateral incisors on the left side.



**Fig. 3:** Showing two lateral incisor on the left maxillary arch with proper pulp chambers and one root canal each.

germ that may cause fusion of two tooth buds or separation of single tooth bud into two are hereditary or congenital diseases, nutritional deficiency, local traumas, infectious/inflammatory processes, ionizing radiation, endocrine influences, excessive ingestion of medicines.<sup>2</sup>

Thus, Double teeth are two separate teeth exhibiting merger by dentin and perhaps their pulps. The unification may be the result of fusion of two adjacent tooth buds or the unfinished splitting of one into two.<sup>4,5</sup>

Gemination is defined as an attempt of a single tooth bud to split, with the ensuing development of a tooth with a bifid crown and typically a general root and root canal. It is not always possible to differentiate between gemination and a case in which there has been fusion between a normal tooth and a supernumerary tooth.<sup>6</sup> On the other hand, fusion is considered as the union of two normally separated tooth buds with the consequential development of a joined tooth with confluence of dentin. Finally, Concrescence is the union of two teeth by cementum only, without confluence of the dentin. Twinning is considered when there is development of two separate teeth that arose from the complete division of one tooth bud.<sup>7</sup>

Many case reports of gemination involving primary and permanent dentition have been reported in literature.<sup>8,9</sup> However, occurrence of twinning in primary or permanent dentition is very rare. However, the prevalence of twinned tooth is more in permanent dentition than primary. Twinned tooth shows a low deep groove from incisal to gingival third and is considered when the division results in equivalent structures consequentially leading to one normal and one supernumerary tooth. Radiographically, in twinning there will be only one pulp chamber with two root canals.

Tannenbaum and Alling defined gemination as the formation of the equivalent of two teeth from the same follicle, with an attempt for teeth to be incompletely separate. This incomplete separation is usually indicated clinically by a depression or groove which might demarcate two teeth. Radiographically, there appears to be only one root canal. The bifid tooth is counted as one entity, the total number of teeth in the dental arch is otherwise normal.<sup>10</sup>

Gemination has a higher prevalence in deciduous teeth, with a higher frequency in anterior maxillary region with equal sex predilection. Hence it is most commonly seen in maxillary primary incisors but is rare in permanent dentition. This anomaly has a large bifid crown which is incompletely separated that has single pulp chamber and root canal. Complete case history, clinical examination, and radiographic investigation can provide the information required for the distinction between gemination and twinning.<sup>11</sup> The tooth involved in our case was permanent maxillary left lateral incisor.

## 2. Conclusion

The present case is twinning because there is an extra formation of teeth by complete division of the bud of the lateral left maxillary incisor into two and striking resemblance to each other.

## 3. Conflict of Interest

None.


## 4. Source of Funding

None.

## References

1. Neville BW, Damn DD, Allen CM, Bouquot JE. Oral and maxillofacial pathology 1st Edn. Philadelphia, W.B Saunders Company; 1995. p. 362–84.
2. Hunasgi S, Koneru A, Manvikar V, Vanishree M, Amrutha R. A Rare Case of Twinning Involving Primary Maxillary Lateral Incisor with Review of Literature. *J Clin Diagn Res.* 2017;11(2):9–11. doi:10.7860/JCDR/2017/23510.9212.
3. Pipsa J, Thesleff I. Mechanisms of ectodermal organogenesis. *Dev Biol.* 2003;262(2):195–205. doi:10.1016/s0012-1606(03)00325-7.
4. Tarasingh P, Balaji K. Gemination in primary teeth – A Report of Two Clinical Cases. *Ann Essences Dent.* 2010;2(2):48–51.
5. Yuen S, Chan JCY, Wei S. Double primary teeth and their relationship with the permanent successors: A radiographic study of 376 cases. *Pediatr Dent.* 1987;9(1):42–8.
6. Shafer WG, Hine MK, Levy BM. Text Book of Oral Pathology. 4th Edn. Philadelphia: West Washington Square, WB Saunders Company; 1983.
7. Krishnan S, Wadhvani KK. Case of Twinning in Permanent lateral incisor. *Endodontology.* 1999;11(2):57–9. doi:Case of twinning in permanent lateral incisor.
8. Sharada HL, Deo B, Briget B. Gemination of a Permanent Lateral Incisor- A Case Report with Special Emphasis on Management. *J Int Oral Health.* 2013;5(2):49–53.
9. Nandini DB, Deepak BS, Selvamani M, Puneeth HK. Diagnostic Dilemma of a Double Tooth: A Rare Case Report and Review. *J Clin Diagn Res.* 2014;8(1):271–72.
10. Tannenbaum KA, Alling EE. Anomalous tooth development: Case reports of germination and twinning. *Oral Med and Oral Path.* 1963;16:883–7. doi:10.1016/0030-4220(63)90326-8.
11. Rao PK, Veena KM, Chatra L, Shenai P. Twin tooth on either side: A case report of bilateral gemination. *Ann Med Health Sci Res.* 2013;3(2):271–3. doi:10.4103/2141-9248.113677.

## Author biography

**Neha Upadhyay**, Associate Professor  <https://orcid.org/0000-0001-6046-2694>

**Inrajeet Singh**, Professor

**Cite this article:** Upadhyay N, Singh I, Mishra R. Twinned lateral incisors. *J Dent Spec* 2022;10(2):70-72.