



Original Research Article

Journey to a confident smile: Management of hyperpigmented lips with 940 nm diode laser along with topical vitamin C - A case series

Anjali Singh^{1,*}, Shalini Dubey¹, Bhavneet Kaur¹, Joochi Chandra¹, Vidya Sekhar¹, Sumit Malhotra¹

¹Dept. of Periodontology and Implantology, ITS Dental College, Ghaziabad, Uttar Pradesh, India



ARTICLE INFO

Article history:

Received 30-06-2022

Accepted 18-07-2022

Available online 05-09-2022

Keywords:

Ozone gel

Chlorhexidine gel

Gingivitis

Plaque

ABSTRACT

Objective: To evaluate the results of Diode Laser along with topical Vitamin C in management hyperpigmented lips.

Materials and Methods: Two systemically healthy patients (1 male and 1 female) were chosen with hyperpigmented lips. Demographic record including the age, sex, duration of symptoms, nature and course of progression, history of treatment done if any, and familial predisposition of melasma was taken. All the patients were also instructed not to use any external cosmetic agent throughout the course of the therapy. A duly signed informed consent was taken after explaining the complete procedure to patient. Both cases went through Laser depigmentation session; topical anesthetic cream Prilox (2.5% lignocaine) was applied 40 minutes prior to each session. Vit C lip balm was prescribed after 3 weeks for better healing.

Results: There was a significant reduction in DOPI score for both the patients. A scale 4 colour improvement at 21 days postoperatively for both which signifies "great improvement". Pain and discomfort were measured by using VAS scale with a score 2 i.e. slight pain during the procedure and during 24 hours after the Laser ablation of the lips. Patient scored 3 which is completely satisfied on the Likert's scale.

Conclusion: Diode laser can be used as potential tool to achieve good aesthetic results for the management of lip hyperpigmentation and it is sufficiently tolerated by patients with minimal pain and lesser adverse effects.

This is an Open Access (OA) journal, and articles are distributed under the terms of the [Creative Commons Attribution-NonCommercial-ShareAlike 4.0 License](https://creativecommons.org/licenses/by-nc-sa/4.0/), which allows others to remix, tweak, and build upon the work non-commercially, as long as appropriate credit is given and the new creations are licensed under the identical terms.

For reprints contact: reprint@ipinnovative.com

1. Introduction

Lips form an important aspect of our smile. The contour and shape of the lips and its colour defines lip's beauty and are integral element of so.

Pink and reddish colour of the lips is normally observed but it could varies from individual to individual. This depends on various factors some of which include production of melanin, skin colour, vascular supply of the lip and extent of dryness (dehydration) of the lips.

Lip darkening has been a common problem among people. Wide variety of conditions that are associated

with the darkening of lips are physiologic changes, some non-melanotic conditions, inflammatory diseases, genodermatoses, drugs and chemicals, endocrinologic disorders, benign and malignant neoplasm.

Factors influencing lip colour changes may include sun exposure, smoking, vascular lesions, anaemia, syndromes, medications, antimicrobial antifungals, topical chemicals, hormones, skin colour etc. The change of the lip colour is usually considered unesthetic. This affects the patient's self-confidence and social activities.

Lips have minor salivary glands and have extensive supply nerve endings, which render them sensitive to pain; therefore, any procedures performed on the lips should

* Corresponding author.

E-mail address: anjalitasma@gmail.com (A. Singh).

consider the anatomy in order to avert pain, scars and mucocoeles.¹

Various techniques have been implemented for depigmentation. The superficial epithelial layer contains the melanin pigmentation making its elimination easy. The various treatment modalities documented in literature for depigmentation of lips include laser therapy, chemical peeling (micro abrasion), cryotherapy, photodynamic therapy, pigmentation and topical medicated agents (Vit. C, arbutin, liquid nitrogen and hydroquinone).^{2,3} Most of the possible treatment modalities have variable outcomes and are associated with adverse effects.^{4,5} However, lasers are well tolerated by patients and have depicted good acceptable results in terms of aesthetics.

Diode laser is the 4th generation of its technology. At 940 nm, its transmission is through water, and it attracts melanin and haemoglobin pigment. The mechanically gated pulsed or continuous wave, both modes produce a long tissue interaction time, requiring longer relaxation time for tissue to cool down. Therefore, 1 to 1.5W (low power) for most soft tissue procedures is recommended. Dr. Mick Swick developed the use of “High Fluency Technique”, for 940 nm diode wavelength. The major precaution for any soft tissue laser procedure is using water irrigation as a coolant, this increases the power and reduces collateral tissue damage and heat stacking effect that damages the adjacent tooth structures and underlying bone. This is done to avoid deep penetration of the laser energy. The melanin that causes pigmentation of the laser energy is selectively absorbed causing photothermal ablation of melanocytes leading to its disruption.

Ascorbic acid or Vitamin C alternatively known as ascorbate which is a water-soluble vitamin and is highly labile, is majorly disintegrated during food processing owing to its property. It is fundamental for the growth and prompt function of teeth, gums, ligaments, healthy bones, and blood vessels and contribute to vital metabolic functions. The minimal daily requirement is 40–60 mg/day to maintain healthy adults.⁶ It also plays a part as an antipigmentation agent by activating the tyrosinase-active sites through interaction with copper ions which imparts the conversion mechanism of tyrosine into melanin. This decreases melanin production and manifestation. In a clinical study assessing efficacy of a topical formulation of 25% vitamin C along with a chemical penetration enhancer reported substantial reduction in pigmentation level attributed by melasma post 16 weeks.⁷

With these considerations, Diode laser, in ablative mode along with topical application of vitamin C has been evaluated in this study.

2. Materials and Methods

Two patients (1 male and 1 female) reported to Department of Periodontology, ITS Dental College, Ghaziabad were

initially interviewed and assessed regarding their concern about lip hyperpigmentation post a thorough consultation with general physician to negate the presence of any systemic condition. Patient were assessed extensively to rule out the exclusion criteria of history of pregnancy and lactation, severe actinic damage, on pharmacological agents causing aggravation of pigmentation and with obvious allergy to any of the ingredients were excluded. Demographic record including the age, sex, duration of symptoms, nature and course of progression, history of treatment done if any, and familial predisposition of melasma was taken. All the patients were also instructed not to use any external cosmetic agent throughout the course of the therapy.

2.1. Laser equipment

1. Laser from Biolase with a wavelength of 940nm ± 10nm was used. Following parameters were used under the Low Surgery Program:
2. Spot size: 400µm tip initiated,
3. Peak Power: 1 W
4. Average Power: 0.6 W

2.2. Paramaters

1. The lip pigmentation underwent assessment according to Dummett Oral Pigmentation Index (DOPI 1971).⁸ The scoring of DOPI was done as:
 - (a) Score 1: No clinical pigmentation (pink gingival)
 - (b) Score 2: Mild clinical pigmentation (mild light brown colour)
 - (c) Score 3: Moderate clinical pigmentation (medium brown or mixed pink and brown)
 - (d) Score 4: Heavy clinical pigmentation (deep brown or bluish black).
2. Pain Perception: During the procedure and 24 hours after the treatment: Quantity of pain was assessed with Visual analogue scale. VAS score.⁹ It was scored for 1-10 mm as:
 - (a) Score 0: 0 mm: no pain
 - (b) Score 1: 1 to 3 mm: slight pain
 - (c) Score 2: 4 to 6 mm: moderate pain
 - (d) Score 3: 7 to 10 mm: severe pain.

Patients were asked to score the pain intensity and discomfort felt during the procedure and at 24 hour period after the Laser treatment.
3. Colour improvements were assessed at baseline and at 1 month post-operatively. The colour improvement objective recording of lip colour variation was assessed using a five-point smile improvement scale⁹ as follows:
 - (a) Scale 1: No improvement

- (b) Scale 2: Little improvement
- (c) Scale 3: Average improvement
- (d) Scale 4: Great improvement
- (e) Scale 5: Complete improvement (natural lip colour)

Photographs of smiles of the patients were taken before and after treatments, at baseline and at 1 month post-operatively.

4. Self-assessment was used via a three-point Likert scale

- (a) 1 = not satisfied
- (b) 2 = moderately satisfied
- (c) 3 = completely satisfied

This above mentioned grading system was chosen as it offers clarity and understanding to the patients owing to its simple nature.

1. Clinical parameters: Any adverse effects and post-op pain was assessed between consequent sessions. Post-operative healing time and the colour improvements were assessed 2 weeks post-operatively.
2. Esthetic parameters: Photographs assessment of smiles were taken pre operatively and post operatively, further assessment was done by three calibrated professionals. The whole procedure was kept blinded and randomized in order to rule out the biases and was repeated for validity and repeatability. Ratings were also measured on basis of the five-point smile improvement scale.

2.3. Procedure

Two systemically healthy patients aged between 38 and 25 years, with hyperpigmented lips were selected for the therapy. Clinical photographs were taken for the same. According to the Dummett Oral Pigmentation Index.

Table 1: DOPI score before the procedure

DOPI score	
Case 1	4
Case 2	3

A duly signed informed consent was taken after explaining the complete procedure to patient. Both cases went through Laser depigmentation session; topical anesthetic cream Prilox (2.5% lignocaine) was applied 40 minutes prior to each session. All prescribed laser safety precautions were also followed. The patient was made to open the mouth widely and the depigmentation procedure was performed starting right from the upper lip to the lower lip. The initiation of laser was done and the outer skin layers of the lips were gently ablated sequentially in a clockwise manner so that none of the areas were left untreated. Depigmentation was performed with the

Laser by applying short repetitive light paint brush strokes maintain the contact mode, majorly in horizontal direction for removal of the epithelial lining. The surgically treated site was continuously wiped off with saline soaked gauze. Patients comfort level was continuously monitored using VAS score. Crust formation over the lips was observed during the first 3 days of healing post operatively, which might be transiently visually unesthetic. Patients was asked to apply Vaseline and vitamin E since it gives profound comfort to the patients. This crust being self-withering sheds off leaving the pink-colored tone to the lips beneath it in approximately 7 days.

2.4. Post-operative care

1. Proper analgesic was prescribed.
2. Cold fomentation was advised for 3 days, done every 30 minutes.
3. Sun block was advised for lips until appropriate healing occurs.
4. Patients were asked to eat only sweet and cold food for a period of 24 hours.
5. Patient were advised to avoid usage of alcoholic beverages, smoking, as well as spicy foods for one week post operatively.
6. Upto 24 hours after the surgical procedure, patients were asked to apply Vaseline to keep lips moisturised.
7. Additional Vit C lip balm can be added to aid faster healing.

3. Result

The table below describes the changes in various parameters assessed.

Table 2: Scores of parameters assessed

	Dopi s core	Vas scale	Colour Improvement	Likert Scale
Case 1	2	2	4	3
Case 2	3	2	4	3

There was a significant reduction in DOPI score for both the patients. A scale 4 colour improvement at 21 days post-operatively for both which signifies “great improvement”. Pain and discomfort was measured by using VAS scale with a score 2 i.e. slight pain during the procedure and during 24 hours after the Laser ablation of the lips. Patient scored 3 which is completely satisfied on the likert scale.

4. Discussion

Lip Depigmentation is a choiced cosmetic treatment modality for removing melanin pigments and dark colour from the lips. In our study we have used laser for the depigmentation procedure. Kassem (2016)¹⁰ used Diode laser of 810nm for treatment of lip depigmentation

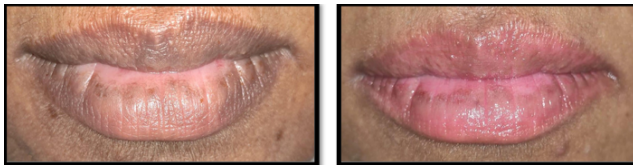

Fig. 1: Case 1 - Pre and post-operative pictures

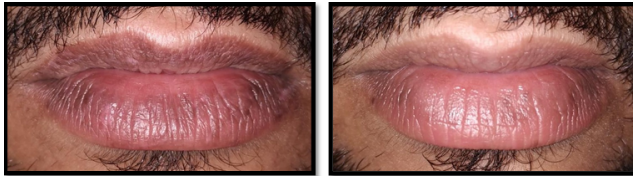


Fig. 2: Case 2 - Pre and post-operative pictures

procedure. Similarly we have also used the diode laser, with a wavelength 940nm. Soft tissue laser does not interfere with dental hard tissues and is majorly indicated for incision, excision and coagulating soft tissue. Recent studies have reported additional anti-microbial effects which is an add-on advantage of using diode laser therapy along with patients' acceptance and overall safety. There are many articles that have been documented in regard to lip melanin depigmentation with a laser using near-infrared (1064, 940, and 810 nm) and also the Q-switched 532 nm.⁴

In above mentioned cases a marked improvement in the colour of lips after 21 days of healing was observed. Patients underwent complete wound healing 14 days after the procedure. Healing could have also been faster due to application of Vit-C.

Ascorbic Acid is available around the globe as a variety of ointments, toner, serum and transdermal patches. It is unstable and is present in an almost colourless form. It gets oxidized to dehydro-AA when exposed to light and imparts a yellow colour to it. Ascorbic Acid (Vitamin C) formulations for topical application, that have been used in the concentration range of 1%–20%. Therefore, in our cases we asked the patient to use Vitamin C lip balm 3 days post operatively till 21 days for uneventful healing.

A case of post laser melanin hyperpigmentation in a woman suffering from melasma reported by Lee and the management of their technique is similar to our study.¹¹ Lee concluded that Vitamin C when administered intravenously is fairly beneficial in treating post laser melanin hyperpigmentation. Similar studies by Sheel et al. concluded that Vitamin C can be used as an adjunct along with the surgical scalpel depigmentation to achieve good aesthetic results with low subjective pain levels. Moreover no recurrence was observed 9 months post operatively.¹²

The limitation of the case series was the lesser number of cases and lesser follow-up period. There was no study to be taken as control group for assessing the efficacy of Vit C.

5. Conclusion

Diode laser can be used as potential tool to achieve good aesthetic results for the management of lip hyperpigmentation and it is sufficiently tolerated by patients with minimal pain and lesser adverse effects. Thus, making it an efficient way to change the pigmentation for aesthetically concerned patients.

6. Conflict of Interest

The authors declare no relevant conflicts of interest.

7. Source of Funding

None.

References

- Arda O, Göksüğü N, Tüzün Y. Basic histological structure and functions of facial skin. *Clin Dermatol.* 2014;32(1):3–13. doi:10.1016/j.clindermatol.2013.05.021.
- Dadzie OE. Defining ethnic dermatology: Challenges, limitations, and merits. *Ethnic Dermatology: Principles and Practice* ; 2013. p. 1–4.
- Bandyopadhyay D. Topical treatment of melasma. *Indian journal of dermatology.* 2009;54(4):303–303.
- Kunachak S, Kunachakr S, Kunachakr S, Leelaudomlapi P, Wongwaisayawan S. An effective treatment of dark lip by frequency-doubled Q-switched Nd: YAG laser. *Dermatol Surg.* 2001;27(1):37–40.
- Limpjaroenviriyakul N, Jurairattanaporn N, Kamanamool N, Rojhirunsakool S, Kanokrungrsee S, Udompataikul M, et al. Low-fluence Q-switched Nd:YAG 1064-nm laser versus Q-switched Nd:YAG 532-nm laser in the treatment of hyperpigmented lips: a prospective, randomized, controlled, evaluator-blinded trial. *Lasers Med Sci.* 2020;35(1):165–71. doi:10.1007/s10103-019-02814-4.
- Hwang SW, Oh DJ, Lee D, Kim JW, Park SW. Clinical efficacy of 25% L-ascorbic acid (C'ensil) in the treatment of melasma. *J Cutaneous Med Surg.* 2009;13(2):74–81.
- Walingo KM. Role of vitamin C (ascorbic acid) on human health—a review. *Afr J Food Agriculture Nutr Dev.* 2005;5(1):1–11. doi:10.18697/ajfand.8.1155.
- Dummett CO, Gupta OP. Estimating the epidemiology of oral pigmentation. *J National Med Assoc.* 1964;56(5):419–20.
- Agha MT, Polenik P, Hassan M. Er,Cr:YSGG 2780 nm Laser Treatment of Lip Melanin Hyperpigmentation. *Int J Dent.* 2021;p. 6621341. doi:10.1155/2021/6621341.
- Kassem I, Al-Agha M. Lip depigmentation (pinkification) using 810nm diode laser, kassem's protocol: initial case report. *Smile Dent J.* 2016;110(3852):1–4.
- Lee GS. Intravenous vitamin C in the treatment of post-laser hyperpigmentation for melasma: A short report. *J Cosmetic Laser Ther.* 2008;10(4):234–6.
- Sheel V, Purwar P, Dixit J, Rai P. Ancillary role of vitamin C in pink aesthetics. *BMJ Case Rep.* 2015;p. bcr2014208559. doi:10.1136/bcr-2014-208559.

Author biography

Anjali Singh, Post Graduate

Shalini Dubey, Post Graduate

Bhavneet Kaur, Post Graduate

Joohi Chandra, Research Scholar

Vidya Sekhar, Professor

Sumit Malhotra, Professor and HOD

Cite this article: Singh A, Dubey S, Kaur B, Chandra J, Sekhar V, Malhotra S. Journey to a confident smile: Management of hyperpigmented lips with 940 nm diode laser along with topical vitamin C - A case series. *J Dent Spec* 2022;10(2):62-66.