



Case Report

Apexification of an infected untreated immature tooth with calplus (Calcium hydroxide paste with Iodoform)

Shakir Hussain Rather^{1,*}, Sohel Salim Sidat², Humaira Mir¹

¹Dr. Shakir's Dentzmania Dental Care, Shopian, Jammu and Kashmir, India

²Priyadarshini Dental College and Hospital, Chennai, Tamil Nadu, India



ARTICLE INFO

Article history:

Received 24-02-2022

Accepted 01-03-2022

Available online 30-03-2022

Keywords:

Apexification

Apexogenesis

Calplus (Calcium hydroxide paste with Iodoform)

MTA

Open apex

ABSTRACT

Apexification is a method to induce a calcific barrier across an open apex or the sustained apical development of an incomplete root in teeth with necrotic pulp. Apical closure occurs approximately three years after eruption. Apexification is a treatment option that is done with the aim of apical repair by formation of hard tissue barrier through apex. Conventionally, a calcified barrier is induced using a calcium hydroxide mixture. Various materials that can be used for apexification include Calcium hydroxide, MTA, Tricalcium phosphate, Dentin chips, Calcium phosphate ceramics and hydroxyapatite and bone morphogenetic proteins. Calcium hydroxide is the most common and traditional material employed for inducing apexification. Multi visit technique requiring 6-24 months to complete by using calcium hydroxide paste with Iodoform.

This is an Open Access (OA) journal, and articles are distributed under the terms of the [Creative Commons Attribution-NonCommercial-ShareAlike 4.0 License](https://creativecommons.org/licenses/by-nc-sa/4.0/), which allows others to remix, tweak, and build upon the work non-commercially, as long as appropriate credit is given and the new creations are licensed under the identical terms.

For reprints contact: reprint@ipinnovative.com

1. Introduction

Apexification is a method to induce a calcific barrier across an open apex of an immature, pulpless tooth.^{1,2} It is the process in which an environment is created within the root canal and periapical tissues after death of pulp, which allows a calcified barrier formation to occur on an open apex.^{3,4} An open apex due to the absence of sufficient root development to provide a conical taper to the canal is called Blunder Buss canal.^{1,5} Apexogenesis can also be defined as the treatment of a vital pulp by pulp capping or pulpotomy in order to permit continued physiological closure of open apex and growth of root.⁶ Although opposite has been reported by Chala et al.⁷ duration of this method has several drawbacks such as the risk of tooth fracture due to prolonged use of CaOH₂⁸ with re-infection of the root canal⁹ or difficulties in patient recall. Considering all these negative factors, single-visit apexification is suggested for the management

of teeth with open apex.¹⁰ Mineral trioxide aggregate (MTA) was first introduced in 1993 by Torabinejad et al¹¹ and received food and drug administration approval in dentin formation occurred around large particles in contrast to small particles. It was described as an alternative to traditional apexification treatment¹² which incorporates the application of the material in the apical third of the canal to create an apical barrier. MTA is a biomaterial with excellent biocompatibility and superior sealing abilities even in the presence of moisture. Kaiser in 1964 first introduced Calcium Hydroxide in apexification mixed with CMCP which was later popularized by Frank, Klein & Levy 1974⁵ used Calcium Hydroxide and Cresatin. Other materials used are MT A, Biphasic calcium phosphate, Hydroxyapatite and dentin chips. Nevins (1978) suggested use of collagen-calcium phosphate gel.

* Corresponding author.

E-mail address: doctorshakir786@gmail.com (S. H. Rather).

1.1. Apexogenesis (root formation)

Apexogenesis describes the continued physiologic development and formation of the root's apex in vital young permanent teeth. It can be achieved by implementing the appropriate vital pulp therapy techniques.^{13,14}

1.2. Apexification (root end closure)

Apexification is a technique of inducing root end closure in an immature nonvital permanent tooth by removing the coronal and radicular tissue and placing a suitable biocompatible agent.^{15,16}

2. Case Report

An 8 year-old boy had reported to Dr. Shakir's Dentzmania Dental Care with the chief complaint of pain and swelling in the maxillary anterior region for the past 1 week. He had suffered dental trauma 5 years back. On Intraoral examination Ellis class II fracture in maxillary left central incisor. Coronal access was prepared with a round burr and the canal was easily located. Working Length was determined through radiography. Gentle circumferential filing used to remove necrosed pulp. Copious irrigation with 2.5% NaOCl was done along with continuous aspiration. The canal was dried with sterile paper points and a mixture of CaOH₂ with Iodoform was placed inside.

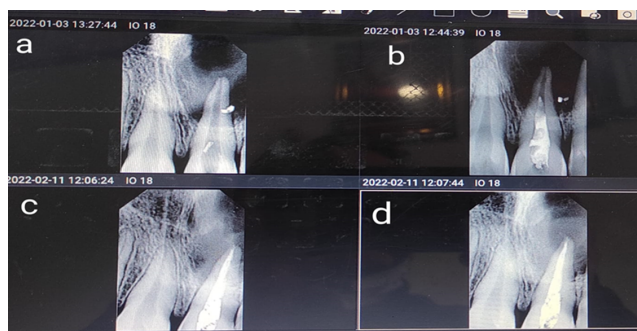


Fig. 1: a: An intraoral periapical radiograph revealed an open apex along with periapical radiolucency; **b:** The canal filled with calcium hydroxide paste with iodoform and sealed temporarily with IRM and Immediate postoperative radiograph was taken to confirm the presence of calcium hydroxide in the canals; **c:** Calcium hydroxide paste with iodoform placed and IOPA was taken after 2months. The patient was kept on 4 months recall and on every visit the radiograph was taken. It took 4-8 months for the complete apical barrier to be formed; **d:** Once the apex was formed obturation was done.

3. Conflict of Interest

The authors declare that there is no conflict of interest.


4. Source of Funding

None.

References

- Grossman. Grossman's endodontic practice. Twelfth edn. New Delhi: Wolters Kluwer (India) Pvt. Ltd.; 2010. p. 515.
- Soares AJ, Nagata JY, Casarin RCV, de Almeida J, de Almeida Gomes B, Zaia AA. Apexification with a new intra-canal medicament: a multidisciplinary case report. *Iran Endod J.* 2012;7(3):165–70.
- Trope M, Chivian N, Sigurdsson A. The role of endodontics after dental traumatic injuries. In: Pathways of the pulp. 10th Edn.. vol. 10. St Louis: Mosby; 2006. p. 610–49.
- Nair PN. Pathogenesis of apical periodontitis and the causes of endodontic failures. *Crit Rev Oral Biol Med.* 2004;15:348–81.
- Rater M. Apxification: A Review. *Dent Traumatol.* 2005;21(1):1–8. doi:10.1111/j.1600-9657.2004.00284.x.
- Ansary MA, Day PF, Duggal MS, and PAB. Interventions for treating traumatized necrotic immature permanent anterior teeth: inducing a calcific barrier & root strengthening. *Dent Traumatol.* 2009;25(4):367–79.
- Chala S, Abouqal R, Rida S. Apexification of immature teeth with calcium hydroxide or mineral trioxide aggregate: systematic review and meta-analysis. *Oral Surg Oral Med Oral Pathol Oral Radiol Endod.* 2011;112(4):36–42. doi:10.1016/j.tripleo.2011.03.047.
- Andreasen JO, Farik B, Munksgaard EC. Long-term calcium hydroxide as a root canal dressing may increase risk of root fracture. *Dent Traumatol.* 2002;18(3):134–7. doi:10.1034/j.1600-9657.2002.00097.x.
- Maroto M, Barbería E, Planells P, Vera V. Treatment of a non-vital immature incisor with mineral trioxide aggregate (MTA). *Dent Traumatol.* 2003;19(3):165–9. doi:10.1034/j.1600-9657.2003.00106.x.
- Khalilak Z, Vali T, Danesh F, Vatanpour M. The Effect of One-Step or Two-Step MTA Plug and Tooth Apical Width on Coronal Leakage in Open Apex Teeth. *Iran Endod J.* 2012;7(1):10–4.
- Lee SJ, Monset M, Torabinejad M. Sealing ability of a mineral trioxide aggregate for repair of lateral root perforations. *J Endod.* 1993;19(11):541–4. doi:10.1016/S0099-2399(06)81282-3.
- Torabinejad M, Chivian N. Clinical applications of mineral trioxide aggregate. *J Endod.* 1999;25(3):197–205. doi:10.1016/S0099-2399(99)80142-3.
- American Academy of Pediatric Dentistry clinical Guideline on Pulp Therapy for Primary and Immature Permanent Teeth. Reference manual . 2009;33:11–2.
- Cooke C, Rowbotham TC. Root canal therapy in nonvital teeth with open apices. *Brit Dent J.* 1960;108:147–50.
- Ball JS. Apical root formation in non-vital immature permanent incisor. Report of a case. *Brit Dent J.* 1964;116:166–7.
- Heithersay GS. Calcium hydroxide in the treatment of pulpless teeth with associated pathology. *J Br Endod Soc.* 1975;8(2):74–93. doi:10.1111/j.1365-2591.1975.tb01000.x.

Author biography

Shakir Hussain Rather, Private Practitioner  <https://orcid.org/0000-0003-0441-5791>

Sohel Salim Sidat, Private Practitioner

Humaira Mir, Private Practitioner

Cite this article: Rather SH, Sidat SS, Mir H. Apexification of an infected untreated immature tooth with calplus (Calcium hydroxide paste with Iodoform). *J Dent Spec* 2022;10(1):36-37.