



## Case Report

# Large atypical odontome in the ramus of mandible: A rare case report

Meenakshi Singhal<sup>1,\*</sup>, Devi Charan Shetty<sup>1</sup>, Saurabh Juneja<sup>1</sup>, Anshi Jain<sup>1</sup>,  
Nikita Gulati<sup>1</sup>

<sup>1</sup>Dept. of Oral pathology and Microbiology, ITSCDSR, Muradnagar, Ghaziabad, Uttar Pradesh, India



### ARTICLE INFO

#### Article history:

Received 25-11-2021

Accepted 12-12-2021

Available online 20-12-2021

#### Keywords:

Compound odontoma

Odontogenic tumors

Atypical Odontoma

### ABSTRACT

Compound odontoma is considered to be a developmental anomalies of the dental tissues or a hamartomatous lesion rather than a true odontogenic tumour. It has an unknown etiology. Odontomas are further subdivided into compound and complex types depending on the extent of morpho-differentiation or on the resemblance to normal teeth. Since, these lesions are asymptomatic, they are usually detected in routine radiographs only. Early diagnosis, prompt clinical decision making followed by a proper treatment at the right time, results in a favorable prognosis. The present report describes a large atypical radiopaque mass located in the ramus of mandible. After the lesion was surgically removed under local anesthesia, histopathological examination confirmed the diagnosis of compound odontoma. The results achieved indicate that the early diagnosis of odontomas allows the adoption of a less complex and expensive treatment and ensures better prognosis.

This is an Open Access (OA) journal, and articles are distributed under the terms of the [Creative Commons Attribution-NonCommercial-ShareAlike 4.0 License](https://creativecommons.org/licenses/by-nc-sa/4.0/), which allows others to remix, tweak, and build upon the work non-commercially, as long as appropriate credit is given and the new creations are licensed under the identical terms.

For reprints contact: [reprint@ipinnovative.com](mailto:reprint@ipinnovative.com)

## 1. Introduction

Tooth eruption & shedding is a physiological process, any variation in normal process is a common finding but deviation from normal should signify the clinician for an alert investigation.<sup>1,2</sup> Odontomas are mixed odontogenic tumors & are considered to be hamartomatous rather than true neoplasms.<sup>3</sup>

Odontomas are further subdivided into compound & complex types according to their clinical resemblance & histo-morphodifferentiation.<sup>4</sup> Odontomas represent tooth duplication but in a disturbed fashion. They seem to arise from budding of odontogenic epithelial cells from dental lamina.<sup>5–7</sup> Odontomas can be found anywhere; those which are located in anterior maxilla are mostly compound while those located in posterior mandible are mostly complex.<sup>8–10</sup>

Odontomas are usually well encapsulated & often come to clinical attention by causing delayed exfoliation of primary tooth, delayed eruption of permanent tooth, over-retention & impaction.<sup>3</sup> Thus, early diagnosis will provide a conservative approach for the clinician to ensure a better prognosis.<sup>1</sup>

## 2. Case History

A 32 years old male patient reported with the complain of pain in the lower right back tooth region since 10-15 days. Pain is mild, intermittent, localized in nature, aggravates on eating and subsides by itself. (Figure 1A)

An intraoral examination revealed bony hard swelling with mild expansion of the buccal cortex in the ramus region when compared to the contralateral side. It was tender on palpation & the overlying mucosa was of normal color. The medical & family history was non-contributory.

\* Corresponding author.

E-mail address: [min13021987@gmail.com](mailto:min13021987@gmail.com) (M. Singhal).

OPG reveals a large radio-opaque tooth like mass surrounded by well circumscribed radiolucent line evident posteriorly few mm anterior to posterior ramus, superiorly upto sigmoid notch, & 0.5cm above the inferior border of mandible. (Figure 1B) Gross specimen revealed multiple hard tissue bits (Figure 1C). Specimen radiography revealed radio-opaque calcified masses. (Figure 1D).

Stereomicroscopic examination was also observed for the present case which revealed glistening appearance of hard tissue. (Figure 1E& F)

Upon clinical & radiological examination, a provisional diagnosis of ossifying fibroma was made along with differential diagnosis of odontome.

Under local anaesthesia, the specimen was removed for histopathological confirmation.

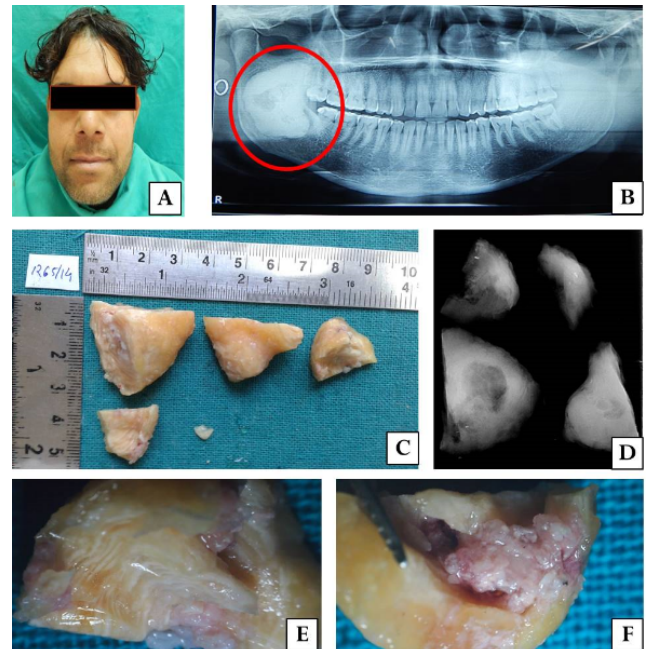
Histopathologically, H and E stained decalcified section showed admixture of dentinal tissues arranged in a haphazard manner with serrated borders. The enamel cap on the denticles was removed during decalcification, the section revealed teeth containing dentin with dentinal tubules, pulp, cementum and periodontal ligament-like tissue. Some of them were surrounded by a compressed connective tissue stroma. (Figure 2A,B,C,D) Ground section of Specimen shows disorganized arrangement of dental hard tissues such as dentin & cementum. (Figure 3)

By co-relating the clinical, radiological & histopathological findings, a definitive diagnosis of compound odontome was made.

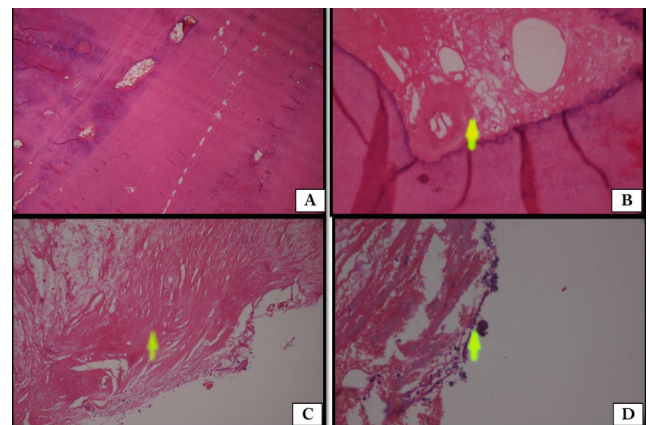
### 3. Discussion

Odontomas are mixed odontogenic tumours classified as benign, mixed, calcified odontogenic tumours constitute about 22% of all odontogenic tumours of the jaws.<sup>3</sup> WHO 2005, has classified two types as; complex and compound odontomes, occurring in the ratio of 1:2. They are hamartomatous lesions rather than true neoplasms. They may occur at any age and in any gender; however, most cases are detected in the first two decades of life on routine radiographs. Majority of compound odontomas are located in the anterior region of the maxilla and diagnosis is frequently made on the basis of the failure of a permanent tooth to erupt while complex odontomes are located in the mandible especially in the posterior areas.<sup>1</sup>

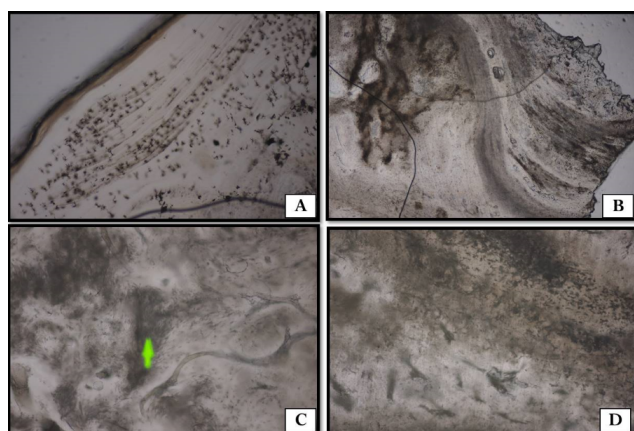
The mechanism of odontome eruption appears to be different from tooth eruption because of the lack of periodontal ligament and root in odontoma. Therefore the force required to move the odontoma is not linked to the contractility of the fibroblasts, as in the case for teeth.<sup>11</sup> Although there is no root formation in odontoma, its increasing size may lead to the sequestration of the overlying bone and hence occlusal movement or eruption. An increase in the size of the odontoma over time produces a force sufficient to cause bone resorption. Another reason for odontoma eruption could be the bone remodeling of the



**Fig. 1:** (A): Clinical picture, (B): OPG revealing Large tooth like radio-opaque mass in the Ramus of Mandible, (C): Gross examination of the specimen revealed multiple hard tissue bits, (D): Specimen Radiograph revealed radiopaque structures suggestive of mineralized tissue component, (E & F): Stereomicroscopic examination of the specimen shows glistening appearance of hard tissue.



**Fig. 2:** Decalcified sections of specimen showing admixture of dentinal tissues arranged in a haphazard manner with serrated borders. (A): H & E stained section (10x), (B): H & E stained section (40x), (C): H & E stained section (10x) and (D): H & E stained section (4x) showing calcifications.



**Fig. 3:** Ground section of Specimen showing disorganized arrangement of dental hard tissues such as dentin & cementum.

jaws. However, for this to occur dental follicle is required although indirectly, as it provides both the conductance and chemoattraction for the osteoclasts necessary for tooth eruption.<sup>12</sup>

Odontomas are relatively common odontogenic lesions, generally asymptomatic, and are rarely diagnosed before the second decade of life. They frequently lead to impaction or delayed eruption of permanent teeth. Clinical experience suggests and the dental literature supports that an individualized radiographic examination of any pediatric patient that presents clinical evidence of delayed permanent tooth eruption or temporary tooth displacement with or without a history of previous dental trauma should be performed.<sup>8</sup>

#### 4. Conflicts of Interest

The authors declare that there are no conflicts of interest regarding the publication of this paper.

#### 5. Source of Funding

None.

#### References

1. Choudhary PJ, Gharote HP, Hegde K, Gangwal P. Compound Odontoma Associated with Impacted Teeth: A Case Report. *IJSS Case Rep Rev.* 2014;1(3):12–5.
2. Eversole LR. *Clinical Outline of Oral Pathology-Diagnosis and Treatment.* 3rd Edn. Hamilton: BC Decker Inc; 2002. p. 298–9.
3. Sharma U, Sharma R, Gulati A, Yadav R, Gauba K. Compound composite odontoma with unusual number of denticles - A rare entity. *Saudi Dent J.* 2010;22(3):145–9.
4. Solanki NS, Thakkar V, Kolte DR. Erupted complex composite odontome: a rare case. *IOSR-JDMS.* 2014;13(7):8–11.
5. & Kaur PKM. Odontoma associated with non-syndrome multiple supplemental supernumerary teeth. *J Clin Diagn Res.* 2011;5(1):142–5.
6. Wood NK, Goaz P. *Differential diagnosis of oral and maxillofacial lesions.* Har count Brace and company Asia Pt Ltd; 1998. p. 467–9.
7. Jacobson JK. The Odontomas<sup>1</sup>. *Am J Ortho.* 1946;32:147–52. doi:10.1016/0096-6347(46)90223-2.
8. Oliveira BHD, Campos V, Marçal S. Compound odontoma—diagnosis and treatment: three case reports. *Pediatr Dent.* 2001;23(2):151–7.
9. Bengston AL, Bengston NG, Benassi. LRDC: Odontomas em pacientes pediátricos. *Revista de Odontopediatria.* 1993;2:25–33.
10. Budnick SD. Compound and complex odontomas. *Oral Surg Oral Med Oral Path.* 1976;42(4):501–7. doi:10.1016/0030-4220(76)90297-8.
11. Nadendla LK. Erupted compound odontoma: Report of a rare case. *J Oral Maxillofac Radiol.* 2013;1(2):83–5.
12. Jindal MK, Hashmi GS, Maheshwari S, Khan MT. Interdisciplinary management of Compound Odontoma- A case report. *Univ J Dent Sci.* 2015;1(2):68–71.

#### Author biography

**Meenakshi Singhal**, Senior Lecturer

**Devi Charan Shetty**, Principal, Professor and Head

**Saurabh Juneja**, Reader

**Anshi Jain**, Reader

**Nikita Gulati**, Reader

**Cite this article:** Singhal M, Shetty DC, Juneja S, Jain A, Gulati N. Large atypical odontome in the ramus of mandible: A rare case report. *J Dent Spec* 2021;9(2):88-90.