



## Case Report

# Mineral trioxide aggregate for apexification in non-vital teeth with open apices: A case report

Priya Mendiratta<sup>1,\*</sup>, Pooja Srivastava<sup>1</sup>, Bhavna Gupta<sup>1</sup>

<sup>1</sup>Dept. of Pediatric and Preventive Dentistry, Sudha Rustagi College of Dental Sciences and Research, Faridabad, Haryana, India



## ARTICLE INFO

### Article history:

Received 26-11-2021

Accepted 05-12-2021

Available online 20-12-2021

### Keywords:

Apexification

Non vital immature teeth

MTA

Open apex

Young permanent teeth

Calcium hydroxide

## ABSTRACT

Management of immature non-vital teeth poses challenge for the clinician owing to the thin root canal walls and open apices which may show apical divergence. Apexification is the technique of inducing the apical closure with a root end filling material for non-vital immature young permanent teeth. Traditionally, Calcium hydroxide was the material of choice for apexification of immature permanent teeth but introduction of MTA has shown remarkable promise as an alternative to calcium hydroxide. This report presents a case of apexification of anterior two young permanent teeth with open apices using MTA and Gutta percha followed by esthetic build up using cast metal posts and full coverage restorations.

This is an Open Access (OA) journal, and articles are distributed under the terms of the [Creative Commons Attribution-NonCommercial-ShareAlike 4.0 License](https://creativecommons.org/licenses/by-nc-sa/4.0/), which allows others to remix, tweak, and build upon the work non-commercially, as long as appropriate credit is given and the new creations are licensed under the identical terms.

For reprints contact: [reprint@ipinnovative.com](mailto:reprint@ipinnovative.com)

## 1. Introduction

Traumatic dental injuries occur very commonly to anterior teeth. Maxillary central incisors are the most commonly affected teeth with traumatic injuries. In these, about 16% injuries are complicated crown fractures involving the pulp.<sup>1</sup> When traumatic injuries are severe, it results in pulpal inflammation which progresses to pulpal necrosis later.<sup>2</sup> In young permanent teeth, trauma causes the incomplete formation of dentinal walls at the apical end of the root resulting in blunderbass canals.<sup>1</sup> Due to the absence of apical constriction in these teeth, apexification i.e. closure of the root end can be done in place of conventional root canal procedure. This has widely gained popularity over the years.<sup>3</sup> Apexification is the technique of inducing a hard tissue barrier in the root with incompletely formed apex or continuation of development in the apical region of teeth with necrosis in the pulp.<sup>4</sup> Calcium Hydroxide has been used extensively for this. However, it

has several disadvantages like lengthy course of treatment, difficulty in patient recall system, increased risk of fracture of the teeth after calcium hydroxide dressings are left in root canal systems for longer periods.<sup>3</sup> For these reasons, MTA was tried as a material for apexification instead of conventional calcium hydroxide. With the introduction of MTA, apexification could be completed in one or two appointments thus eliminating the problem of long term patient recall as seen with calcium hydroxide.<sup>5</sup> MTA constitutes a mixture of particles of tricalcium oxide, tricalcium silicate and silicate oxide in a hydrophilic medium dispensed as a fine powder. It has properties of excellent biocompatibility, anti-bacterial action with superior ability to seal when used in the open apices of the roots.<sup>6</sup> Other properties are low toxicity, setting ability not inhibited by moisture, effect on odontoblastic induction and hard barrier formation.<sup>7</sup>

This article describes management of a case of two immature non vital anterior teeth using MTA for apexification followed by their esthetic rehabilitation using cast metal posts and full coverage restorations

\* Corresponding author.

E-mail address: [docpriya25@gmail.com](mailto:docpriya25@gmail.com) (P. Mendiratta).

## 2. Case Report

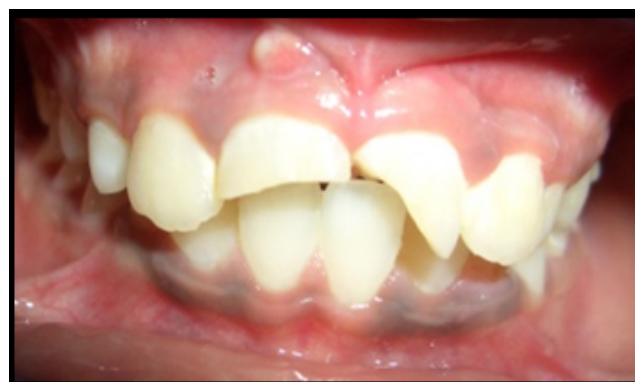A 9 year old patient came to the department of pediatric and preventive dentistry with symptoms of pain with respect to upper front teeth. Patient had undergone trauma to his anterior teeth 2 years back for which no treatment was sought at that time. Intraoral examination revealed right and left central incisors in normal position with Ellis class IV fracture. Periapical sinus tract formation was seen with 11.(Figure 1) Symptoms also included tenderness to percussion wrt 11, 21. Radiographic examination revealed wide root canals, with incompletely formed root apices and periapical lesions with 11, 21.(Figure 2) Lingual access was made with 11, 21. Biomechanical preparation of the roots was performed under rubber dam isolation. Apex locator was used to determine the length of the root canals which was confirmed radiographically. Calcium hydroxide was added as an intracanal medicament and left in the canals for 1 week.

In the second appointment, calcium hydroxide was removed from the canals by mechanical instrumentation followed by irrigation with sterile water. Drying of the root canals was done with sterile paper points. MTA was prepared immediately before use as mentioned by the manufacturer, plugged into the canals with MTA carrier and condensed with the use of a hand plugger till an apical plug of 3 to 4 mm was formed (Figure 3). Radiograph was taken to check if any apical extrusion of the material happened. Wet paper points were inserted in the canals and temporary restorative material was used to close the access cavities.

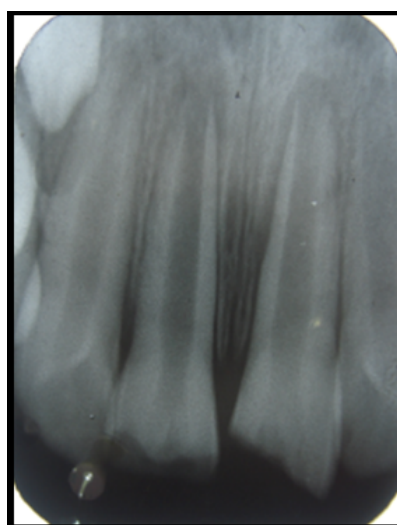
After two days, coronal and middle third of the canals were filled with Gutta percha (Figure 4). Post space preparation was done wrt 11, 21 using Peezo reamers. Inlay wax was used to make impression of the post and core using the direct technique. The patterns were processed for casting using base metal (Figure 5). Glass ionomer luting cement was used for cementation of cast posts wrt 11, 21(Figure 6). Preparation of the teeth was done for polycarbonate crowns (Figure 7). Crowns were luted using Glass ionomer luting cement (Figure 8). Patient was kept under follow up to check for periapical healing and lesion resolution.

## 3. Discussion

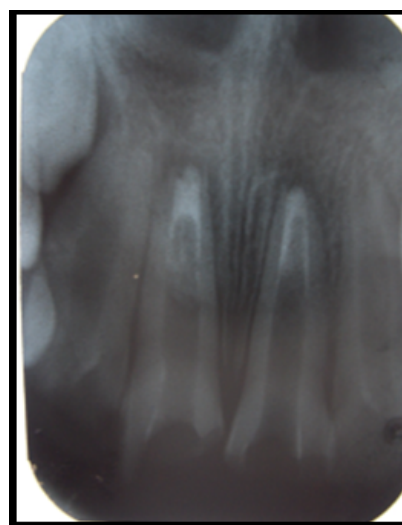
In Endodontics, the success of the treatment depends on obtaining an impervious seal in the apical area of the tooth. Endodontic management of non-vital young permanent teeth affected by traumatic injury is complex due to the presence of open apices with thin walls of dentin, pulp necrosis, and divergence of root canals.<sup>8</sup> Apexification is the procedure of forming a hard tissue artificial barrier at the apex of the tooth. Over the years, apexification with calcium hydroxide has gained a lot of popularity but lately, a few studies indicate that the barrier formed with calcium hydroxide is incomplete. It has a swiss cheese appearance



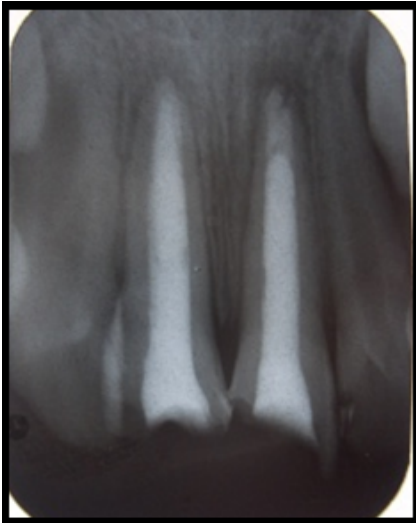**Fig. 1:** Pre-operative photograph showing fractured 11,21. Periapical sinus tract formation wrt 11.



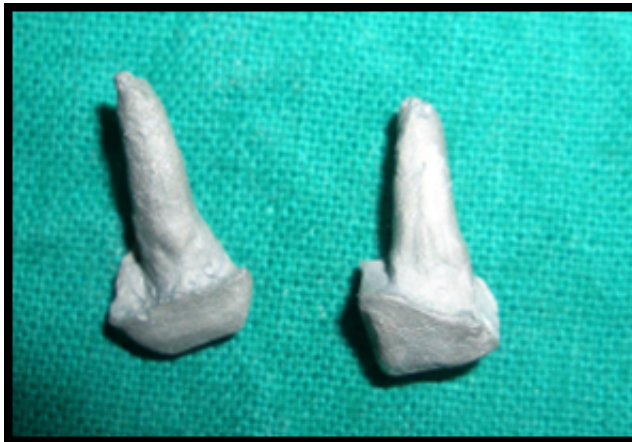**Fig. 2:** Pre-operative radiograph



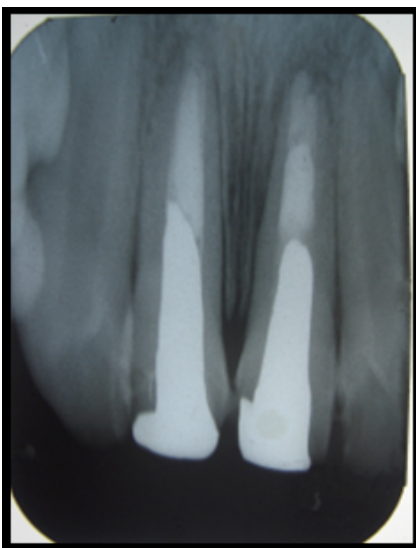**Fig. 3:** MTA placed



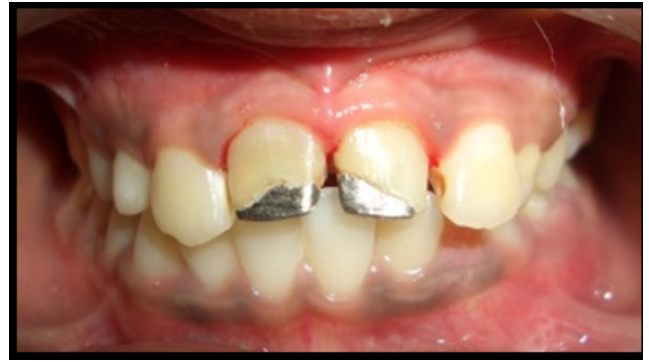**Fig. 4:** Obturation done with gutta percha



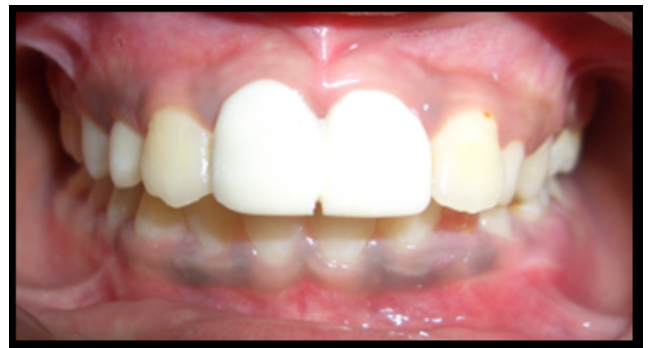**Fig. 5:** Metal posts fabricated



**Fig. 6:** Metal posts placed



**Fig. 7:** Post and core restoration in place



**Fig. 8:** Polycarbonate Crown placement wrt 11,21.

and it also allows microleakage which leads to the chances of reinfections. It also takes a long time (12-24 months) to form hard barrier.<sup>9</sup> Due to these reasons, MTA is being used widely as a suitable material for apexification.<sup>5</sup>

The introduction of MTA as a material for apical closure of roots happened in 1993 at the Loma Linda University (USA). Owing to its excellent biocompatibility and the availability of calcium ions and phosphate ions leading to the accumulation of odontoblastic cells thereby promoting a suitable environment for the deposition of calcium,<sup>5</sup> it has successfully replaced calcium hydroxide in apexification. MTA has a pH of 12.5 after its setting. This shows similarity to the pH value of calcium hydroxide. This has been advocated to contribute to some of its antibacterial properties. As a material used for apexification, Mineral trioxide aggregate behaves as a monoblock. Interfacial deposits like apatite crystals are formed at the time of the maturation phase of MTA. This causes the gaps to fill during the shrinkage phase of the material thereby enhancing the resistance of the material to walls of the root canal.<sup>2</sup> Several studies have shown its suitable properties of less solubility, capability of inducing differentiation of odontoblasts, expansion after setting, good radiopacity, and antimicrobial activity.<sup>4</sup>

In a study done by Shababhang et al, the effectiveness of MTA, osteogenic protein-1 and calcium hydroxide as

apexification agents was compared, it was seen that the extent of hard issue formed was similar but the thickness of apical barrier produced in MTA group had higher stability compared to the other two groups.<sup>10</sup> However, Apexification with MTA has its own drawbacks like the need of specific instruments like MTA carriers and pluggers to facilitate its insertion into the root canals and in cases of large apical foramina, proper adaptation within perfect apical limit can be extremely challenging.<sup>11</sup>

In this case report, the thin root canal walls and thin roots acted posed a challenge to the clinician due to the risk of root fracture with the normal root canal obturation. Thus for the purpose of reinforcement of the root canal walls of both teeth cast metal post and core was selected. It has several advantages like anti-rotational property, preservation of maximum amount of tooth structure as the post is fitted into the radicular space with better adjustment to the morphology of the root canal.<sup>6</sup>

#### 4. Conclusion

In Endodontics, MTA has many wide range of applications. Its use as a favourable material for apexification has widely increased. The most rewarding advantages of this material for the formation of an apical barrier include development of ideal apical seal, reducing the number of appointments to one or two, excellent biocompatibility. Although several other investigations are required to determine more indications of MTA, it can safely act as a replacement for conventional calcium hydroxide as an apexification material.

#### 5. Conflicts of Interest

The authors declare that there are no conflicts of interest regarding the publication of this paper.

#### 6. Source of Funding

None.

#### References

1. Vekaash CJV, Reddy TVK, Sivakumar M, Venkatesh KV. Kondas Vijay Venkatesh: Apexification using MTA - 2 case reports. *Sch J Dent Sci.* 2017;4(3):149–50.
2. Muhamad AH, Azzaldeen A, Mai A, Jabareen A. Single-Step Apexification with Mineral Trioxide Aggregate (MTA) -Case Reports. *J Dent Med Sci.* 2016;15(2):49–53.
3. Kumar GA, Anusha T. Single visit apexification with mineral trioxide aggregate. *Ann Essences Dent.* 2010;.
4. Jaikaria A, Negi P, Kukreja S. Apexification: Use of MTA and Biodentin to form apical barrier in immature permanent teeth. *Int J Appl Dent Sci.* 2019;5(4):156–8.
5. Mathew J, Syriac G, Nair M, Rahul J. Conventional Multivisit Calcium Hydroxide Apexification with Rare Apexogenesis Like Outcome and Novel Single Visit MTA Apexification Followed by Root Reinforcement with Fiber Post: Two Case Reports. *Saudi J Oral Dent Res.* 2017;2(2):43–8.
6. Narang K, Nayak M, Wahed A, George JV, Mathew S. Management of Non-Vital Teeth with Open Apices using MTA: Two Case Reports. *J Dent Oro-facial Res.* 2018;14(1):75–9.
7. Muhamad AH, Abdulgani A, Hanali AS. Abu-Shilabayeh Hanali: Mineral Trioxide Aggregate (MTA) in apexification. *J Endod.* 2013;25(2):97–101.
8. Kakani AK, Chandrasekhar V, Muralidhar T, Chandrakanth M, Rakesh D. Mineral Trioxide Aggregate as an Apical Plug Material in Tooth with Open Apex : A Case Report. *Int J Sci Stud.* 2015;2(11):218–21.
9. Huang GT. Apexification : the beginning of its end. *Int Endod J.* 2009;42(10):855–66. doi:10.1111/j.1365-2591.2009.01577.x.
10. Rafter M. Apexification: a review. *Dent Traumatol.* 2005;21(1):1–8.
11. Silva RV, Silveira FF, Nunes E. Apexification in non-vital teeth with immature roots: report of two cases. *Iran Endod J.* 2015;10(1):79–81.

#### Author biography

**Priya Mendiratta**, Senior Lecturer

**Pooja Srivastava**, Senior Lecturer

**Bhavna Gupta**, Professor and HOD

**Cite this article:** Mendiratta P, Srivastava P, Gupta B. Mineral trioxide aggregate for apexification in non-vital teeth with open apices: A case report. *J Dent Spec* 2021;9(2):84-87.