



Case Report

Emergency management of maxillary dentoalveolar fracture: A case report

Archana H. Dhusia^{1,*}, Heena Sonawane¹, Rishi S Verma¹, Pooja Uchale¹,
Harshada Jagdale¹

¹Dept. of Oral and Maxillofacial Surgery and Dentistry, HBT Medical College and Dr. R. N. Cooper General Hospital, Mumbai, Maharashtra, India



ARTICLE INFO

Article history:

Received 29-06-2021

Accepted 20-10-2021

Available online 20-12-2021

Keywords:

Dentoalveolar

Incisor

Diagnosis

Exarticulation

Intrusive

Luxation

Splinting

Comminution

ABSTRACT

Dentoalveolar trauma occurs in relation to injuries of fall, road traffic accidents, sports injury or physical violence. There may be injury limited to the tooth, or may involve the periodontium around, or in severe cases, alveolar bone or oral mucosa may be traumatised. There can be myriad injuries of the same structure depending upon the severity of impact. The injuries of tooth most commonly being crown fractures, followed by root fractures, luxation or complete avulsion of the tooth. Every type of dentoalveolar injury requires a specific set of clinical protocols to be followed in order to successfully diagnose and manage the particular case.

We hereby report a case of a 29-year-old male patient with a history of fall under the influence of alcohol, who had fallen flat on his face and had suffered intrusive luxation of permanent maxillary right central incisor and avulsion of permanent maxillary left central and lateral incisors. The exarticulated teeth still had slight soft tissue attachment to the socket. On the patient's first visit to dental OPD, being a dental emergency, the avulsed teeth were immediately restored back into the socket under local anaesthesia after adequately irrigating and debriding the socket, followed by repositioning of the internally luxated tooth, so that all were in their correct anatomical position. After checking for occlusion, they were splinted in position with Erich's arch bar and 26 gauge SS wire and after giving post-operative instructions patient was asked to follow up after 6 weeks. At 6 weeks, the affected teeth were found to be firm and so arch bar were removed. Patient was advised to follow up further. At periodic follow ups, the patient was asymptomatic and maintained adequate oral functioning of the injured teeth, thus with good patient compliance and proper diagnosis and treatment, dentoalveolar fractures can be managed successfully. The main purpose of this article is to lay emphasis on the timing of treatment of the dentoalveolar injuries. The earlier they are managed, the better is the outcome.

This is an Open Access (OA) journal, and articles are distributed under the terms of the [Creative Commons Attribution-NonCommercial-ShareAlike 4.0 License](https://creativecommons.org/licenses/by-nc-sa/4.0/), which allows others to remix, tweak, and build upon the work non-commercially, as long as appropriate credit is given and the new creations are licensed under the identical terms.

For reprints contact: reprint@ipinnovative.com

1. Introduction

The maxillary anterior teeth are the most predisposed teeth for fractures during accidental injuries. Most often, single tooth injury is observed following trauma during sports activity, while road traffic accidents or violent activities result in trauma to multiple teeth and often to the

dentoalveolar complex. Factors that govern the extent of injury include direction, shape, energy of impacting object.¹ Depending upon the intensity, the tooth may suffer crown fracture, dislocation or even avulsion out of its socket with possibility of pulpal trauma. The maxillary central and lateral incisors most frequently are involved in dental trauma owing to their position in the anterior region of the jaw.

* Corresponding author.

E-mail address: adhusia@yahoo.co.in (A. H. Dhusia).

1.1. Aetiology and epidemiology

Falls are the most frequent cause of such injuries accounting for 31 to 64 percent, followed by sports injuries (40 percent), cycling and road traffic accidents (27 percent) and physical violence being 7 percent of all cases.² More than 75 percent of tooth fractures occur in the upper jaw, with more than 50 percent of such cases involving central incisors, followed by lateral incisors and canines. Dentoalveolar injuries occur more in permanent dentition compared to the primary dentition.² Tooth fractures thus require emergency intervention in most scenarios depending on the depth of injury.

1.2. Classification of dentoalveolar trauma

Dental trauma, depending on the site of tooth fracture, involvement of the pulp, and other findings, can be classified using

1.3. The Ellis and Davey Classification (1970)²

1. Class I - Simple fracture of the crown-involving little or no dentin
2. Class II - Extensive fracture of the crown involving considerable dentin, but not the pulp
3. Class III - Extensive fracture of the crown involving considerable dentin, and exposing the dental pulp
4. Class IV - The traumatized tooth which becomes non-vital with or without loss of crown structure
5. Class V- Teeth lost as a trauma
6. Class VI - Fracture of the root with or without loss of crown structure
7. Class VII - Displacement of the tooth without fracture of crown or root
8. Class VIII - Fracture of the crown en masse and its replacement
9. Class IX – Traumatic injuries of primary teeth

Classification by Andreasen (1981)³

1.4. Injuries to the hard dental tissues and pulp

Crown infarction - An incomplete fracture (crack) of the enamel without loss of the tooth substance.

Uncomplicated crown fracture - A fracture contained to the enamel or involving enamel and dentin, but not exposing the pulp

Complicated crown fracture- A fracture involving enamel and dentin and exposing the pulp.

Uncomplicated crown root fracture- A fracture involving enamel, dentin and cementum but not involving the pulp.

Complicated crown root fracture - A fracture involving enamel, dentin and cementum and exposing pulp.

Root fracture - fracture involving dentin, cementum and the pulp

1.5. Injuries to the periodontal tissues

Concussion- An injury to the tooth supporting structures without abnormal loosening or displacement of the tooth, but with marked reaction to percussion.

Subluxation - An injury to the tooth supporting structures with abnormal loosening but without displacement of the teeth.

Intrusive Luxation (central dislocation) -Displacement of the tooth into the alveolar bone. This injury is accompanied by comminution or fracture of the alveolar socket.

Extrusive luxation (peripheral dislocation partial avulsion) - Partial displacement of the tooth out of its socket.

Lateral Luxation- Displacement of the tooth in a direction other than axially. This is accompanied by comminution or fracture of the alveolar socket.

Exarticulation (complete avulsion) -Complete displacement of the tooth out of its socket.

The outcome of dentoalveolar traumatic injuries depends upon the timing of management of such cases. The earlier the treatment is initiated, the better is the outcome. We describe a case of intrusive luxation and exarticulation of maxillary anterior teeth which were managed within an hour of sustaining the injury, following the established protocols resulting in an excellent outcome in terms of aesthetics and function.

2. Case Report

A 29-year-old male patient reported to the department of dentistry and maxillofacial surgery with a history of fall under the influence of alcohol. He complained of completely loose and avulsed two left upper front teeth which were just attached to the gum tissue and intrusive luxation of right upper central incisor (Figures 1 and 2)

Patient had been taking anti-epileptic medication phenytoin 100mg orally.

Patient gave history of diastema between permanent maxillary central incisors since they erupted in the oral cavity. There was history of oral bleed present. No history of ear/nose bleed, no loss of consciousness was present. Similarly, no history of bleeding disorder was present and patient was not taking any anticoagulant medication at the time of presentation. He did not have any known drug allergy/ other relevant medical history.

2.1. Clinical findings

On extraoral examination, there was a tender swelling over the chin and upper lip with multiple bruises over the face. Intraorally the maxillary left central incisor and the maxillary left lateral incisor were completely avulsed out of the socket attached by a pedicle of palatal gingiva, with bleeding sockets of the same teeth. There was intrusion of the right maxillary central incisor. The tooth was tender to

percussion and had bleeding around the gums. The labial cortical bone around the injured teeth was comminuted.

The occlusion was derranged because of avulsed maxillary central and lateral incisors of the left side, which were obstructing achievement of correct occlusion.

Diagnosis of dentoalveolar fracture with comminution and intrusive luxation of the maxillary right central incisor and avulsion and exarticulation of the maxillary central incisor and lateral incisors of the left side was made.

As it was a dental emergency, we did not wait for radiological investigations and planned the treatment in the form of wiring the avulsed teeth to the adjacent firm teeth after repositioning them back to their anatomical position. In order to prevent aspiration of the avulsed teeth which were hanging in the oral cavity by a thin tissue pedicle, it was decided to skip the imaging and go for fixation immediately.

2.2. Surgical procedure

The patient's written informed valid consent was taken. The patient was scrubbed, painted and draped in routine surgical fashion. A test dose of 0.1 ml of lignocaine was administered. After confirming no allergic reaction, Lignocaine (2 percent with 1:2,00,000 adrenaline) was infiltrated in the upper anterior region. The intruded maxillary right central incisor was repositioned by pulling it down with upper anterior extraction forceps into correct occlusion. The avulsed maxillary left central and lateral incisor were pushed back into the sockets and positioned back properly. The occlusion was checked and after it was found to be satisfactory, fixation of the dentoalveolar fracture involving the maxillary right central incisor and left central incisor and left lateral incisors was done using Erich's arch bar and 26 G SS wire from maxillary right canine to maxillary left canine which were firm and found fit for anchorage. The involved teeth were disoccluded slightly (Figure 3). Post-operative instructions of maintaining soft diet and avoiding mastication from upper front teeth and no alcohol use were given. The patient was also instructed to take his antiepileptic drug as per his physician's advice to prevent any seizures. Antibiotics and Non-steroidal anti-inflammatory drugs were prescribed to control infection and pain respectively. Post operatively an orthopantomogram was made to rule out any other jaw fractures. Patient was asked to follow up every week for 6 weeks, the time during which endodontic treatment of the affected teeth was done. After 6 weeks, the arch bar and wire were removed (Figure 4) and the teeth were checked and were found to be fixed in position with no mobility. Patient was subsequently followed up for 6 months periodically (Figure 5) and thereafter, the affected teeth were found to be firm and patient was satisfactorily maintaining oral function with all teeth in good health.

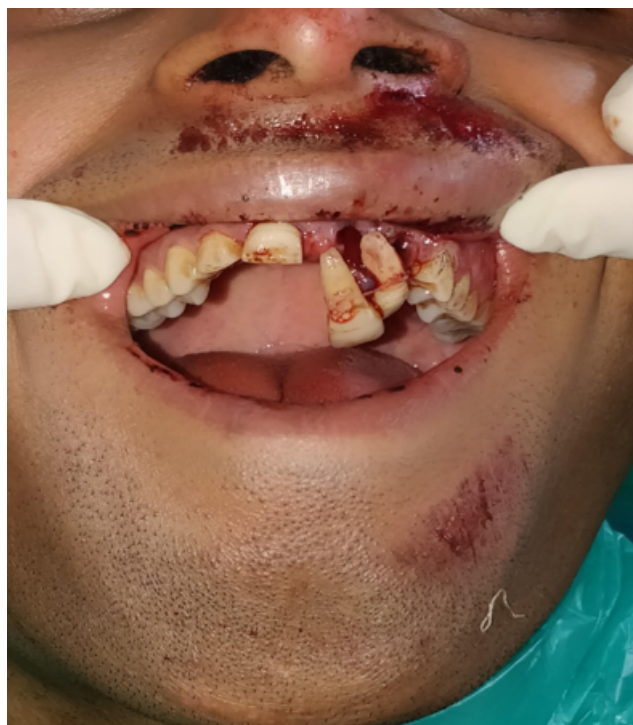

Fig. 1: (Intrusive luxation of maxillary right central incisor and avulsion/ exarticulation of maxillary left central and lateral incisors)

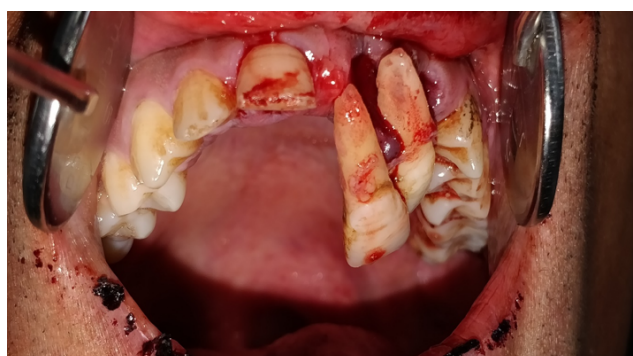


Fig. 2:

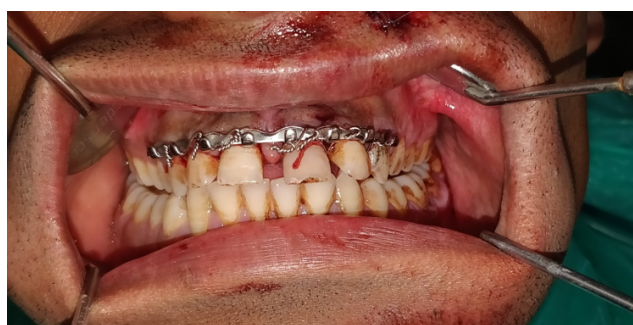

Fig. 3: (Immediate post operative picture showing repositioning and splinting of involved teeth)

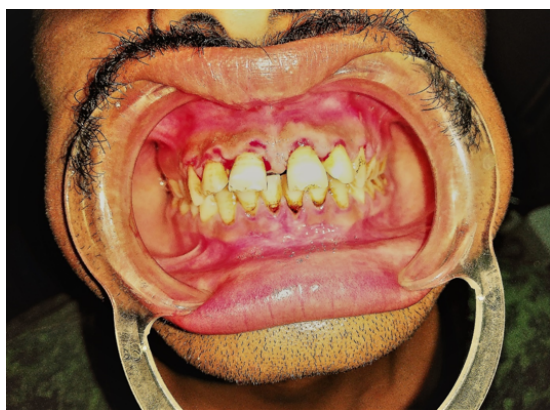

Fig. 4: (6 weeks post operative, immediately after arch bar removal)

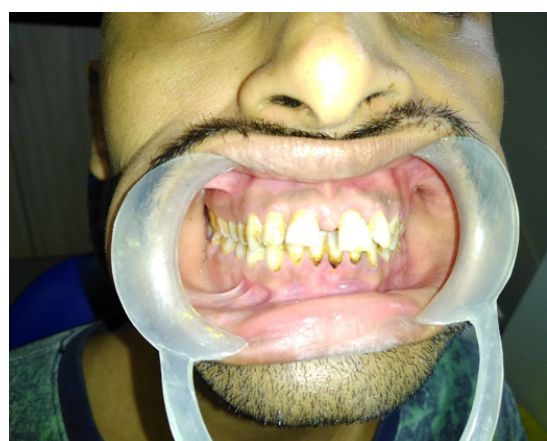

Fig. 5: (6 months post operative)

3. Discussion

Dentoalveolar injuries can present in wide variety. In our case, the patient presented with intrusive luxation of one tooth and avulsion and exarticulation of two upper front teeth.

With regards to treating luxation injuries of teeth, Oikarinen⁴ reported that flexible splinting affords lateral support to fixation of luxated teeth permitting some vertical flexibility, which results in better periodontal healing of the affected teeth. The luxated tooth was subject to endodontic treatment in our case, as Robertson and Andreasen added to the literature that luxative injuries significantly increase the risk of pulpal necrosis.⁵ Moreover, Wang et al, reported that pulpal circulation is more commonly impaired in intrusive luxation, correlating it positively to the chances of pulpal necrosis.⁶

The soft tissue pedicle of palatal gingiva being attached to the tooth might have served the major advantage of preserving periodontal ligament cells, resulting in good healing post splinting. Endodontic treatment of the avulsed teeth was done as pulpal vessels might have been severed

following exarticulation of the tooth from the socket and to prevent further necrosis and discoloration.⁶

4. Conclusion

The emergency dental management in dentoalveolar trauma cases involves proper diagnosis and prompt treatment of injuries. In our case, proper diagnosis of dental injuries along with following established clinical protocols for their treatment resulted in a good healing of the affected teeth and they maintained adequate functioning as was seen in subsequent follow-ups. The timing of treatment plays a very important role in achieving a satisfactory outcome.

5. Conflicts of Interest

The authors declare that there are no conflicts of interest regarding the publication of this paper.


6. Source of Funding

None.

References

1. Treatment and restoration of adult dentoalveolar trauma ;A clinical case report. *J Clin Exp Dent.* 2016;8(5):634–7.
2. Patnana AK, Kanchan T. Tooth Fracture. [Updated 2020 Jul 10]. . In: StatPearls [Internet]. Treasure Island (FL): StatPearls Publishing; 2021.
3. Pagadala S, Tadikonda DC. An overview of classification of dental trauma. *IAIM.* 2015;2(9):157–64.
4. Oikarinen K, Andreasen JO, Andreasen FM. Rigidity of various fixation methods used as dental splints. *Dent Traumatol.* 1992;8(3):113–9. doi:10.1111/j.1600-9657.1992.tb00447.x.
5. Robertson A, Andreasen FM, Andreasen JO, Norén JG. Long-term prognosis of crown-fractured permanent incisors. The effect of stage of root development and associated luxation injury. *Int J Paediatr Dent.* 2000;10(3):191–9. doi:10.1046/j.1365-263x.2000.00191.x.
6. Wang C, Qin M, Guan Y. Analysis of pulp prognosis in 603 permanent teeth with uncomplicated crown fracture with or without luxation. *Dent Traumatol.* 2014;30(5):333–7. doi:10.1111/edt.12099.

Author biography

Archana H. Dhusia, Associate Professor and Head
 <https://orcid.org/0000-0002-5414-7011>

Heena Sonawane, Assistant Professor

Rishi S Verma, Junior Resident

Pooja Uchale, Junior Resident

Harshada Jagdale, Senior Resident

Cite this article: Dhusia AH, Sonawane H, Verma RS, Uchale P, Jagdale H. Emergency management of maxillary dentoalveolar fracture: A case report. *J Dent Spec* 2021;9(2):76-79.