



Review Article

Clear aligner therapy – A review

Sanjana Shetty^{1,*}, Naazia Shaikh²

¹Dept. of Orthodontics and Dentofacial Orthopedics, Sinhgad Dental College and Hospital, Pune, Maharashtra, India

²Dept. of Orthodontics and Dentofacial Orthopedics, M.A. Rangoonwala College of Dental Sciences & Research Centre, Pune, Maharashtra, India



ARTICLE INFO

Article history:

Received 29-07-2021

Accepted 20-10-2021

Available online 20-12-2021

Keywords:

Invisalign

Clear aligners

Aesthetics

ABSTRACT

Aesthetics is a major factor in Orthodontic treatment and it is a primary concern among patients seeking orthodontic treatment. To meet the growing aesthetic desire for an alternative to traditional braces, researchers have created a variety of alternatives, including ceramic or composite braces, lingual orthodontics, and transparent aligners. Clear aligner therapy is a treatment that consists of a set of clear dental appliances that are custom-made to fit the contour of a patient's teeth. Clear Aligners are an alternative to traditional braces that are used to guide teeth into appropriate alignment. Clear aligners, like braces, utilise a progressive force to regulate tooth movement, but without the need of metal wires or brackets.

This is an Open Access (OA) journal, and articles are distributed under the terms of the [Creative Commons Attribution-NonCommercial-ShareAlike 4.0 License](https://creativecommons.org/licenses/by-nc-sa/4.0/), which allows others to remix, tweak, and build upon the work non-commercially, as long as appropriate credit is given and the new creations are licensed under the identical terms.

For reprints contact: reprint@ipinnovative.com

1. Introduction

With the recent rise in the number of people seeking orthodontic treatment, there has been a proportional rise in demand for appliances that are both more aesthetic and more comfortable than traditional fixed equipment. Clear aligners are orthodontic devices that are a clear, plastic version of dental braces used to correct teeth.

2. History

Dr. Kesling described using flexible tooth positioners to move teeth in 1945. The tooth positioning appliance was originally composed of rubber and was a flexible appliance in a single piece that covered the upper and lower tooth surfaces. It permitted active tooth movement and was used for treatment of moderate relapse as well as a retainer.¹

Nahoum introduced the vacuum moulded dental contour appliance in 1964.²

Ponitz pioneered the notion of the "invisible retainer" in 1971, recognising that these thin thermoplastic devices might be used to shift teeth.³

McNamara discussed invisible retainers in 1985 and use of these retainers for minor tooth movements.⁴

Zia Chishti and Kelsey Wirth, both Stanford University graduates, invented the initial technology of Invisalign trays. Chishti's orthodontist provided him with his own plastic retainer to maintain his teeth in place after his treatment was completed and his metal braces were removed. When he noticed that these plastic retainers could also move his teeth back into position when they became out of alignment, he recognised that retainers on their own may be just as effective at aligning teeth. Christi had background in Computer Science and had an idea these new teeth aligners might be built to the desired specifications using 3D CAD-CAM software before being sent to manufacturing. With 3D design tools, software programming, and 3D printing technologies, Align Technology produced "incremental retainers." They can digitally model a patient's existing

* Corresponding author.

E-mail address: sanjanashetty816@gmail.com (S. Shetty).

bite using software they created in-house and then utilise that to construct an aligner particularly for the patient. Align Technology received FDA clearance for Invisalign, a patented term derived from the words "invisible" and "aligners," in 1998. Robert Boyd, chairman of the Department of Orthodontics, University of the Pacific helped Wirth and Christi with means and assistance for testing this technology.⁵(Figure 1)

Zia Chishti cut connections with Align Technology, the parent business he founded, in 2005. He went on to start his own company, OrthoClear. Align Technology eventually went to court, and after a lengthy legal struggle, Align paid Zia and asked him to stop manufacturing.

After 8 years of research and development, Clearpath was incorporated in the United States in 2008.

ClearCorrect, which was established in 2006, gained FDA clearance in 2009. It was launched to Australia in 2015 by osseodent.

K-line was also launched in 2008.

Inman aligners are a variation on the conventional spring retainer. The Inman aligner, unlike the Invisalign system, is not completely transparent and includes a visible metal bar that runs across the front teeth.

3M Clarity aligners entered the clear aligner market in 2008. The analysis and treatment planning were carried out by Dr. Neil Warshawski.

Airnivol aligners were introduced by NIVOL in association with the University of Pisa in Italy, in 2010.

NovoAlign was created in the United States in 2016 after two years of research and development by a team of orthodontists, engineers, dental technicians, and information technology specialists.

3. Indications^{6,7}

1. Problems with mildly crowded and misaligned areas (1–5 mm). Treatment that can be accomplished with lateral and/or antero-posterior expansion, minor interproximal tooth reduction, or removal of a lower incisor.
2. Problems with spacing (1–5 mm).
3. Class II division 2 type malocclusions associated with deepbite where the overbite can be addressed by incisor intrusion and advancement.
4. Narrow arches that may be extended without tipping the teeth.
5. Cases of relapse after fixed orthodontic treatment.
6. Minor rotations.

There is considerable debate over whether moderate to severe orthodontic treatment can be performed frequently using Invisalign. Case reports of effective management of moderate to difficult malocclusions with Invisalign have recently surfaced in the literature.⁸ The Invisalign system's inability to regulate root movement restricts

its usage in malocclusions needing premolar extractions. This is regarded as one of the appliance's most severe shortcomings.⁹ Case studies including premolar extractions emphasise this issue, since it indicated need of permanent appliances to straighten the molars, premolars, and canines at the end of aligner therapy.^{10,11} Honn and Goz provided a case study of a successful Invisalign premolar extraction therapy. One advantage of using the method was that it needed little bodily movement, simply small rotations, and no extrusion, intrusion, or torque movements. The effectiveness of Invisalign therapy is highly dependent on which tooth movements are necessary to address the clinical condition, as well as comprehending the appliance's indications.¹²

4. Contra-indications¹²

1. Crowding and spacing greater than 5 mm.
2. Skeletal anterior-posterior differences greater than 2 mm. Sagittal discrepancies are measured in comparison to Class 1 canine relation.
3. Discrepancies between Centric-relation and centric-occlusion.
4. Teeth that have been severely rotated (greater than 20 degrees).
5. Anterior and posterior open bites that must be closed.
6. Teeth extrusion.
7. Teeth that are tipped more than 45 degrees.
8. Teeth with clinical crowns that are too short.
9. Arches with a many missing teeth.

Although certain aspects of a malocclusion are difficult to manage with Invisalign, this does not mean it should be avoided altogether as it can be used in combination with other treatment.

5. Advantages

1. Great cosmetics- The aligners are totally transparent, making them considerably more difficult to detect than traditional wire and bracket orthodontics. As a result, the procedure is especially popular among adults who wish to straighten their teeth without the appearance of traditional metal braces, which are widely used by children and teenagers.³
2. Facilitate excellent dental hygiene- The benefits of aligner treatment have been highlighted as periodontal health benefits and better dental cleanliness. To back up such assertions, case reports of effective therapy in periodontally impaired individuals have been reported in the literature. These studies have concluded unlike fixed appliance therapy, treatment using clear aligners appears to have no negative impact on gingival health throughout treatment.¹³
3. Easy for patients to use.¹⁴

4. More convenient than fixed appliances- Miller et al. conducted a research in adult patients to assess the therapeutic effects of Invisalign aligner and fixed appliance therapy during the first week of treatment. In terms of function, emotional impact, and pain-related factors, the Invisalign group had less negative effects on their life.¹⁵
5. Aligners need to be removed which helps with patient compliance.
6. Less chairside time.¹⁶

6. Disadvantages

1. Because the aligners are removable, they are not always correcting the teeth, thus they are primarily dependent on a patient's habits and consistency in using the aligners.
2. Lower premolars with round morphology might be challenging for aligners to grab and rotate.
3. During space closure, Invisalign has a limited capacity to maintain teeth upright.
4. Limited root movement control is seen with clear aligners such as root paralleling, general rotation correction, tooth uprighting, and tooth extrusion.
5. Patient compliance is very important.¹⁶
6. There is possibility of misplacing the appliance.¹⁶
7. The physician has no capacity to change the appliance during treatment since the aligners are manufactured by the company from treatment start to treatment conclusion.
8. The entire treatment with clear aligner therapy is expensive as compared to conventional treatment. If treatment drifts off course, new impressions are required, and the case is rebooted in the software and the treatment starts anew and which becomes more expensive.¹⁷
9. Though exceedingly rare, allergic and toxic responses to the aligner material may occur.

6.1. A. Studies comparing fixed orthodontic treatment and clear

1. Kevin Blaine Miller compared the treatment impacts of invisalign and fixed appliance therapy over the first seven days of treatment. During the initial period, the fixed appliance group reported a more severe reduction in overall quality of life and a more severe rise in pain.¹⁸
2. M.G. Taylor conducted a research on the effect of orthodontic tooth movement on periodontal soft tissue using Invisalign. The use of Invisalign aligners enhanced periodontal tissue health as evaluated by papillary bleeding score and periodontal pocket depth throughout treatment.¹⁹

3. Aligners provide less force every week and cause less discomfort than fixed appliances. Fixed appliances are adjusted every six weeks and use larger pressures.
4. Demineralisation or tooth decay develops in many situations because permanent equipment cannot be removed for eating and cleaning. When eating, drinking, brushing one's teeth, or sleeping, one's aligners should be removed. Patients are no longer restricted in what they may eat because the aligners need to be removed.¹⁸
5. The Invisalign procedure requires computerised treatment planning. This allows the prospective patient to see the projected smile design, discover how long the treatment is expected to take, compare alternative designs, and make a better informed decision about the treatment.
6. A study conducted by Djeu G, Shelton C, Maganzini A. assessed outcome of Invisalign and traditional orthodontic treatment. It was concluded that Invisalign's ability to repair significant anteroposterior abnormalities and occlusal contacts was particularly lacking. Invisalign's strengths were its ability to close spaces and rectify anterior rotations and marginal ridge heights.²⁰
7. Kuncio D, Maganzini A, Shelton C, Freeman K conducted a study to examine the post-retention dental alterations between patients treated with Invisalign and those treated with traditional fixed appliances. Results showed that patients treated with Invisalign relapsed at a higher rate than those treated with conventional appliances.²¹
8. The purpose of study conducted by Grunheid T, Gaalaas S, Hamdan H, Larson BE was to evaluate the changes in buccolingual inclination of mandibular canines and intercanine distance in individuals treated with clear aligners vs those treated with preadjusted edgewise appliances. In contrast to treatment with fixed appliances, which leaves the intercanine distance unaltered but results in more upright mandibular canines, orthodontic treatment with clear aligners tends to increase the mandibular intercanine distance with no change in inclination.²²
9. Pavoni C, Lione R, Lagana G, Cozza P conducted a study to compare the changes in transverse dimension and maxillary arch perimeter caused by low friction self-ligating brackets to the Invisalign technique. It was concluded that treatment with self-ligating was helpful in alleviating moderate crowding by increasing arch width and rectifying buccolingual inclination, occlusal contacts, and root angulations. Invisalign therapy has also been shown to be effective in straightening arches by derotating teeth and levelling arches. Because of the absence of control over tooth movement, Invisalign may readily tip crowns but not roots.²³

10. The purpose of the study conducted by Hennessy J, Garvey T, Al-Awadhi EA was to examine the mandibular incisor proclination caused by fixed labial appliances with third generation clear aligners. It was concluded that there was no difference in the degree of mandibular incisor proclination induced by transparent aligners versus fixed labial appliances in mild crowding conditions.²⁴

7. G. Tooth movements with clear aligners

7.1. Tooth attachments²⁴

During clear aligner therapy, tiny white tooth-coloured forms are attached to the teeth. Because of the round and smooth shape of teeth, attachments assist in precisely moving the teeth in the proper direction to get the greatest possible outcome in the shortest amount of time. They are also called precision attachments sometimes.

Attachments are divided into three commonly used categories: ellipsoid, bevelled, and rectangular.

Ellipsoid attachments are utilised individually for derotations or in pairs when attempting root movements. When used alone, ellipsoid attachments should provide more rotational control. When used in pairs, they should be able to generate moment of couple to upright roots.

When attempting to extrude a tooth, bevelled attachments are most commonly employed. They have an active border, similar to fixed brackets, which should prevent slipping between the aligner and the teeth.

When considerable mesio-distal motions are required, rectangular attachments are employed. These attachments, it is believed, will allow teeth to be moved physically by allowing for a greater span of force application.

When all three types of attachments are bound to the tooth, they are not entirely engaged at first. The attachments become increasingly active as the patient progresses through the various aligners., This technique is identical to working through archwires when employing the pre-adjusted edgewise.(Figure 2)

7.2. Space closure

Closing the space at the extraction sites necessitates the use of "root control" attachments on the teeth next to the extraction sites. Correct use of these attachments can to control root movements can yield good results and studies in literature support this.²⁴

7.3. Molar distalization

The use of aligners in conjunction with composite attachments and class II elastics allowed for translational movement of the maxillary molars. Simon et al. onducted a research to assess the efficacy of aligners in terms of incisal torque movement, premolar derotation, and molar

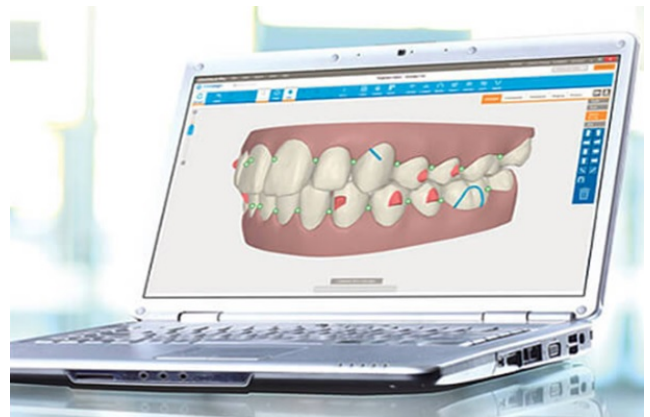


Fig. 1: Invisalign software.

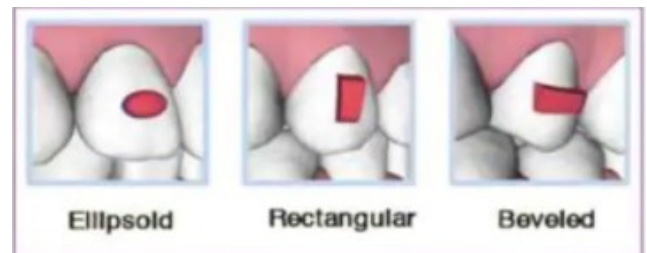


Fig. 2: Attachments used in clear aligners.

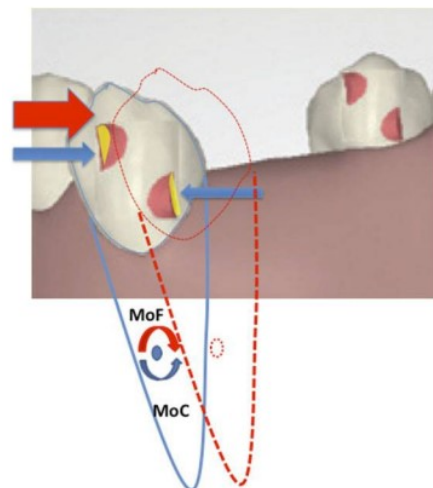


Fig. 3: Translational movement of mandibular canine into extraction space with help of ellipsoid attachment.

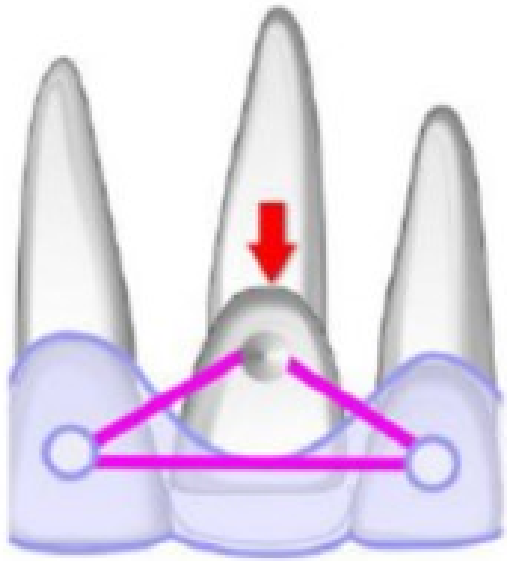


Fig. 4: Power grip for extrusion of tooth.

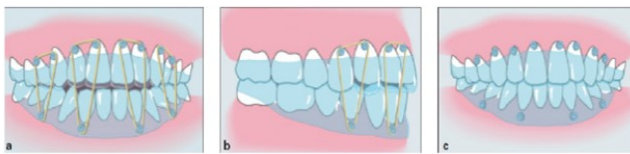


Fig. 5: Extrusion with help of elastics

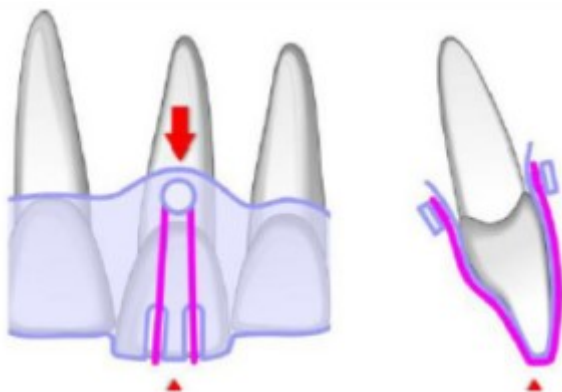


Fig. 6: Intrusion of a central incisor with help of vestibular and lingual buttons.

distalization. Molar distalization had the highest rate of accuracy.²⁵

Kravitz et al. assessed the efficiency of tooth movement using removable polyurethane aligners in a prospective clinical trial, and the least accurate movement was extrusion (29.6 percent) - particularly, extrusion of the maxillary (18.3 percent) and mandibular (24.5 percent) central incisors.²⁶

7.4. Extrusion

Kravitz et al.²⁶ assessed the effectiveness of tooth movement using removable polyurethane aligners in a clinical trial, and the least accurate movement was extrusion - particularly, extrusion of the maxillary and mandibular central incisors. But development of attachments has improved the efficiency of extrusion. Then, attachments with an active flat surface on which the aligner may apply force are required. The active portion is the most important aspect of the attachment since it is the area that the aligner engages. The remainder of the attachment acts as a link and reinforcement. When extruding a tooth, bevelled attachments (bevelled towards the gingiva) are most commonly used. Another method is to utilise a Power grip connected to the buccal surface of the extruded tooth, two aligner buttons at the adjoining teeth, and elastics. Extrusion is initiated by changing the elastics three to four times each day. When the necessary extrusion is finished, the aligner secures the tooth in the proper place. Intermaxillary elastics can be utilised in situations with open bite needing 2 to 3 mm extrusions. The extrusion teeth have buttons that are connected to the opposite arch by elastics on the buttons. When the intended extrusion is complete, the target teeth will be in contact with the aligner's inner surface, and no additional extrusion will occur.²⁴

7.5. Intrusion

The optimum aligner treatment procedure for achieving intrusion in a shorter amount of time is to apply optimal intrusion force to the target teeth while keeping the anchoring teeth stable. The aligners are advantageous because they cover all of the teeth, preventing posterior teeth extrusion. In most cases, composite attachments on the affected teeth are not required. However, for anchoring and relative extrusion of these premolars, the anchor teeth should be provided with horizontal rectangular attachments.²⁷ Another technique is to place two buttons on the aligner at the gum level of the target tooth, buccally and lingually. The incisal edge is then cut with two deep grooves to hook the elastics in the event of anterior tooth intrusion.²⁸

7.6. Uncontrolled tipping

A research was carried out to describe the movement of teeth around the premolar extraction site during space closure using aligner appliances, followed by fixed

appliances. Treatment with aligners resulted in considerable tipping of the teeth next to premolar extraction sites in this study.²⁹

7.7. Controlled tipping

In 2017, a study was conducted to assess the influence of material thickness on the forces and moments imparted by aligners to a maxillary incisor during tipping and intrusion.³⁰

7.8. Torque

Power - Ridges may be used to perform torque movement with aligners. They are meant to impart a lingual or palatal force to the cervical section of the crown, which, when limited by the plastic covering the incisal edge of the same tooth, produces a couple of forces, one of which is expected to cause the lingual torque.³¹

To control the torque of an upper central incisor, an efficient couple of forces must be created. One is a tipping force created by reversible deformation of the device along the gingival line and other is a resulting force produced by movement of the tooth against the opposing internal surface of the appliance near the incisal edge.

7.9. Rotations

There are two ways to complete the rotation: By attaching buttons to the buccal and palatal surfaces of the turned tooth and using elastic chains between them before or during the aligner treatment, a pair of forces can be produced to rotate a tooth. Until the rotation is rectified, the chains can be replaced every three weeks. Using improved rotation attachments, it is also feasible to conduct canine and bicuspid rotations in a more predictable manner. These vary in form according on the force necessary to rotate the affected tooth. The aligner itself rotated the 21, 22, while an optimum attachment positioned distal of the 23 allowed for mesio-palatal rotation correction.

8. Conclusion

During treatment, the clear aligners can give outstanding aesthetics and is simple and comfortable to use. It is useful for small space closure, lingual and constriction, and correction of anterior rotations and marginal ridge height disparities. Clear aligners have certain restrictions in terms of attaining the same outcomes as traditional fixed orthodontic equipment. Further study and design improvement are still necessary for the development of this useful therapy.

9. Conflicts of Interest

The authors declare that there are no conflicts of interest regarding the publication of this paper.

10. Source of Funding

None.

References

1. Kesling HD. The philosophy of the tooth positioning appliance. *Am J Orthod Oral Surg.* 1945;31(6):297–304. doi:10.1016/0096-6347(45)90101-3.
2. Nahoum HI. The vacuum formed dental contour appliance. *New York State Dent J.* 1964;9:385–90.
3. Ponitz RJ. Invisible retainers. *Am J Orthod.* 1971;59(3):266–72. doi:10.1016/0002-9416(71)90099-6.
4. Mcnamara JA, Kramer KL, Juenker JP. Invisible retainers. *J Clin Orthod.* 1985;19(8):570–8.
5. Align Technology and Ortho Clear Complete Definitive Agreement. Available from: www.aligntechnology.com.
6. Joffe L. Current Products and Practice Invisalign: early experiences. *J Orthod.* 2003;30(4):348–52.
7. Naik VR, Chavan P. Invisalign: The invisible braces. *IJCD.* 2010;1(2):54–7.
8. Chenin DA, Trosien AH, Fong PF, Miller RA, Lee RS. Orthodontic treatment with a series of removable appliances. *J Am Dent Assoc.* 2003;134(9):1232–9. doi:10.14219/jada.archive.2003.0358.
9. Giancotti A, Greco M, Mampieri G. Extraction treatment using Invisalign Technique. *Prog Orthod.* 2006;7(1):32–43.
10. Giancotti A, Girolamo RD. Treatment of severe maxillary crowding using Invisalign and fixed appliances. *J Clin Orthod.* 2009;43(9):583–9.
11. Miller RJ, Kuo E, Choi W. Validation of Align Technology's Treat III digital model superimposition tool and its case application. *Orthod Craniofac Res.* 2003;6(1):143–9.
12. Boyd RL. Complex orthodontic treatment using a new protocol for the Invisalign appliance. *J Clin Orthod.* 2007;41(9):525–47.
13. Boyd RL. Esthetic orthodontic treatment using the invisalign appliance for moderate to complex malocclusions. *J Dent Educ.* 2008;72(8):948–67.
14. Miller RJ, Kuo E, Choi W. Validation of Align Technology's Treat III digital model superimposition tool and its case application. *Orthod Craniofac Res.* 2003;6(1):143–9.
15. Miller KB, Mcgorray SP, Womack R, Quintero JC, Perelmuter M, Gibson J, et al. A comparison of treatment impacts between Invisalign aligner and fixed appliance therapy during the first week of treatment. *Am J Orthod Dentofac Orthop.* 2007;131(3):302.e1–9. doi:10.1016/j.ajodo.2006.05.031.
16. Vlaskalic V, Boyd R. Orthodontic treatment of a mildly crowded malocclusion using the Invisalign System. *Aust Orthod J.* 2001;17(1):41–6.
17. Joffe L. Current Products and Practice Invisalign: early experiences. *J Orthod.* 2003;30(4):348–52.
18. Miller KB, Mcgorray SP, Womack R, Quintero JC, Perelmuter M, Gibson J, et al. A comparison of treatment impacts between Invisalign and fixed appliance therapy during the first week of treatment. *Am J Orthod Dentofacial Orthop.* 2007;131(3):302.e1–9.
19. Taylor MG, Mcgorray SP, Durrett S. Effect of Invisalign aligners on periodontal tissues. *J Dent Res.* 2003;82:1483.
20. Djeu G, Shelton C, Maganzini A. Outcome assessment of Invisalign and traditional orthodontic treatment compared with the American Board of Orthodontics objective grading system. *Am J Orthod Dentofac Orthop.* 2005;128(3):292–8. doi:10.1016/j.ajodo.2005.06.002.
21. Kuncio D, Maganzini A, Shelton C, Freeman K. Invisalign and traditional orthodontic treatment postretention outcomes compared using the American Board of Orthodontics objective grading system. *Angle Orthod.* 2007;77(5):864–9. doi:10.2319/100106-398.1.
22. Grunheid T, Gaalaas S, Hamdan H, Larson BE. Effect of clear aligner therapy on the buccolingual inclination of mandibular canines

- and the intercanine distance. *Angle Orthod.* 2016;86(1):10–6. doi:10.2319/012615-59.1.
23. Pavoni C, Lione R, Lagana G, Cozza P. Self-ligating versus Invisalign: analysis of dento-alveolar effects. *Ann Stomatol.* 2011;2(1-2):23–30.
 24. Hennessy J, Garvey T, Ea AA. A randomized clinical trial comparing mandibular incisor proclination produced by fixed labial appliances and clear aligners. *Angle Orthod.* 2016;86(5):706–12. doi:10.2319/101415-686.1.
 25. Simon M, Keilig L, Schwarze J, Jung BA, Bourauel C. Treatment outcome and efficacy of an aligner technique-regarding incisor torque, premolar derotation and molar distalization. *BMC Oral Health.* 2014;14(1):68. doi:10.1186/1472-6831-14-68.
 26. Kravitz ND, Kusnoto B, Begole E, Obrez A, Agran B. How well does Invisalign work? A prospective clinical study evaluating the efficacy of tooth movement with Invisalign. *Am J Orthod Dentofac Orthop.* 2009;135(1):27–35. doi:10.1016/j.ajodo.2007.05.018.
 27. Liu Y, Hu W. Force changes associated with different intrusion strategies for deep-bite correction by clear aligners. *Angle Orthodontist.* 2018;88(6):771–8.
 28. Chaudret F. Biomécanique des aligneurs en orthodontie. *Sciences du Vivant [q-bio]. dumas-01938617;* 2018.
 29. Baldwin DK, King G, Ramsay DS, Huang G, Bollen AM. Activation time and material stiffness of sequential removable orthodontic appliances. Part 3: premolar extraction patients. *Am J Orthod Dentofac Orthop.* 2008;133(6):837–45.
 30. Smith RJ, Burstone CJ. Mechanics of tooth movement. *Am J Orthod.* 1984;85(4):294–307.
 31. Brezniak N. The Clear Plastic Appliance. A Biomechanical Point of View. *Angle Orthod.* 2008;78(2):381–2.

Author biography

Sanjana Shetty, Post Graduate Student

Naazia Shaikh, Post Graduate Student

Cite this article: Shetty S, Shaikh N. Clear aligner therapy – A review. *J Dent Spec* 2021;9(2):46-52.