



Case Report

Class II correction by maxillary molar distalization with pendulum appliance - A case report

Nivedita Nandeshwar^{1,*}, Sujoy Banerjee², Rashmi Jawalekar¹, Usha Shenoy²

¹Dept. of Orthodontics and Dentofacial Orthopedics, SDKS Dental College, Nagpur, Maharashtra, India

²Dept. of Orthodontics and Dentofacial Orthopedics, VSPM's Dental College & Research Center, Nagpur, Maharashtra, India



ARTICLE INFO

Article history:

Received 25-07-2021

Accepted 04-09-2021

Available online 09-10-2021

Keywords:

Maxillary Molar Distalization

Pendulum

Class II Malocclusion

ABSTRACT

24 year male patient presented with skeletal class II base with prognathic maxilla and orthognathic mandible. Angles class II division 1 subdivision malocclusion with proclined upper and lower anteriors, increase overjet, increased overbite, spacing with upper and lower anteriors, scissor bite with 35, class I molar and canine relation on right side, end on molar and canine relation on left side. Distalization was planned in maxillary arch to correct end on molar relation on left side and upper incisor proclination. Unilateral Pendulum appliance was used to distalize upper left molar. Post treatment Class I molar relationship was achieved bilaterally within 2-4 months with incisor proclination reduced. The total treatment ended in 18 months.

This is an Open Access (OA) journal, and articles are distributed under the terms of the [Creative Commons Attribution-NonCommercial-ShareAlike 4.0 License](https://creativecommons.org/licenses/by-nc-sa/4.0/), which allows others to remix, tweak, and build upon the work non-commercially, as long as appropriate credit is given and the new creations are licensed under the identical terms.

For reprints contact: reprint@ipinnovative.com

1. Introduction

Class II malocclusion is one of the most frequent malocclusion encountered in orthodontics where distalization is considered as one of the conservative ways of treatment.¹ Maxillary molar distalization has been used successfully for more than 100 years in orthodontics to treat cases with class II malocclusion. This technique is used to relieve crowding and reduce the increased overjet by utilization of space gained.² The primary advantage in this technique is the ability to gain space in a conservative way without the need for extraction. A myriad of devices have been developed over the years to distalize the maxillary molars with agreeable clinical outcomes. Of various distalization appliances Pendulum Appliance introduced by Hilgers in 1992³ emerged and the clinical application of the pendulum appliance has demonstrated good result.

2. Case Report

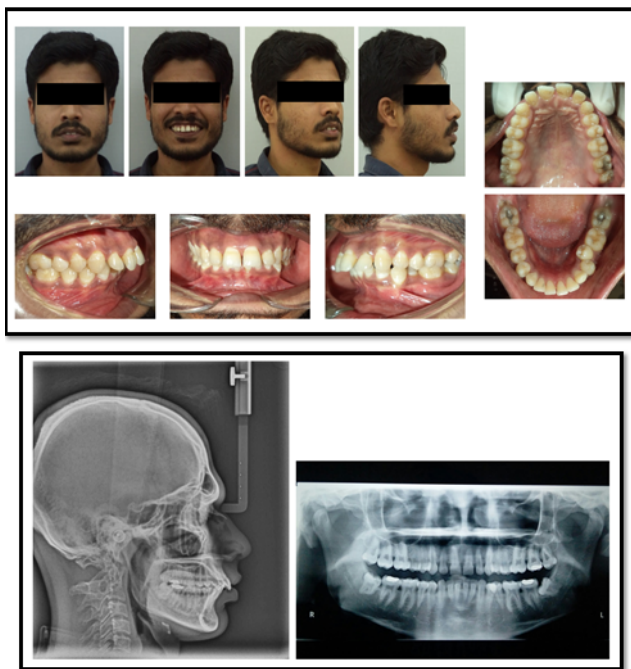
24-year male presented with the chief complaint of proclined upper front teeth with no relevant medical and dental history. On clinical examination no abnormality was detected with temporomandibular joint. Facial form was mesoprosopic and mild convex soft tissue profile incompetent lips, reduced nasolabial angle, deep mentolabial sulcus, non-consonant smile. On intraoral examination patient had end on molar and canine relation on left side, class I molar and canine relation on right side with mild proclination of upper and lower anteriors, increase overjet, increased overbite, spacing with upper and lower anteriors, scissor bite with 35 (Figure 1). Cephalometric analysis revealed that patient had skeletal Class II base with prognathic maxilla and orthognathic mandible with average growth pattern (Table 1).

* Corresponding author.

E-mail address: niveditan2804@gmail.com (N. Nandeshwar).

Table 1: Comparative Cephalometric Analysis

Measurements	Mean Values	Pre Treatment	Current Status
SNA	82°	85°	85°
SNB	80°	81°	81°
ANB	2°	4°	4°
SN- (Go-Gn)	32°	30°	31°
U1 – NA angular	22°	24°	25°
U1 – NA linear	4 mm	5 mm	6 mm
L1 – NB angular	25°	26°	27°
L1 – NB linear	4 mm	4 mm	5 mm
L1 – MPA	90°	91°	92°
Interincisal angle	130°	129°	127°
S line to U lip	-2 mm	2 mm	2 mm
S line to L lip	0 mm	1 mm	2 mm
Nasolabial Angle	90 - 110°	94 °	96°

**Fig. 1:** Pre-treatment records.

3. Treatment Objectives

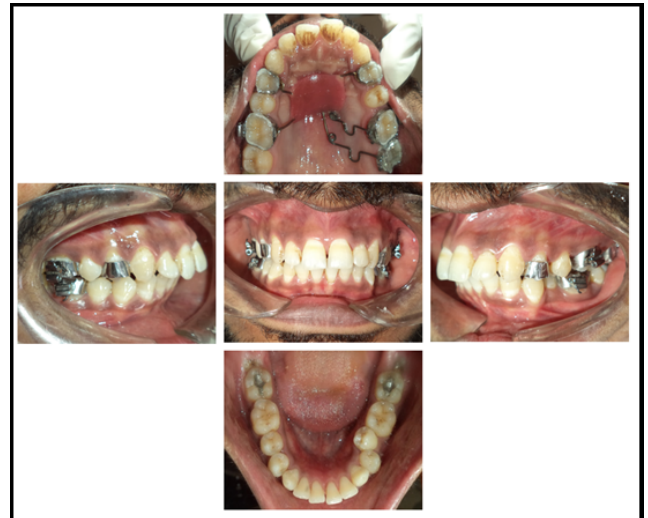Treatment objectives were to correct proclined upper and lower anteriors, spacing with upper and lower anteriors, increase overjet overbite, scissor bite with 35, end on molar and canine relation on left side, convex profile, and incompetent lips.

3.1. Treatment Plan

Unilateral distalization of the maxillary molars was planned using Pendulum Appliance with respect to upper left quadrant, followed by fixed appliance therapy.

3.2. Treatment Progress

Maxillary 1st premolars, 1st molar and 2nd molars both right and left sides were banded and Pendulum Appliance with 0.032 TMA wire was fabricated and attached (Figure 2). The appliance was activated by 90° to deliver a force of 220 grams. After the desired distalization was achieved in 2-4 months, appliance was kept in place for 2 months to retain the distalization effect, followed by placement of Nance palatal arch. Fixed mechano therapy by bonding with 0.018 MBT was initiated. Alignment and levelling in the both arches was carried out by following wire sequence: (a) 0.016" heat activated nickel-titanium arch wires (b) 0.016x0.022" nickel-titanium arch wires (c) 0.016x0.022" SS arch wires (d) 0.017x0.025" NiTi arch wires (e) 0.017x0.025" SS arch wires. The arch wires were cinched distal to molar to avoid maxillary and mandibular incisor proclination. Treatment was completed in 18 months. After debonding patient was given essix retainer and follow up was done for next 6 months.

**Fig. 2:** Pendulum Appliance

4. Treatment Result

Post treatment a good occlusion was achieved with bilateral Class I molar and canine relation along with normal overjet and overbite, with no spacing, no crowding in upper and lower arch and coinciding upper and lower dental and facial midlines, consonant smile and lip seal (Figure 3)

5. Discussion

In most of the non-extraction borderline case molar distalization procedures has been the choice of management. Unilateral Class II molar was successfully treated with Pendulum appliance. Unilateral distalization had the advantage of stronger anchorage because the

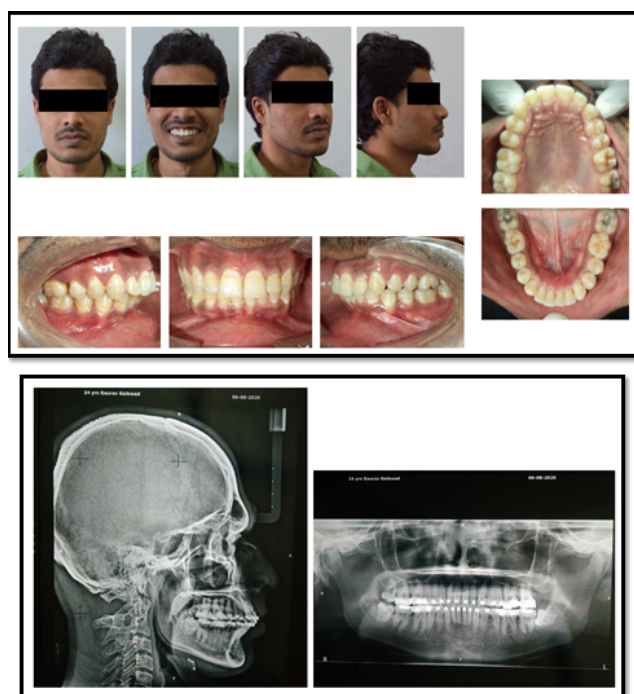


Fig. 3: Post-treatment records.

contralateral side was utilized as an anchorage unit. The pendulum appliance is the preference of choice because of its simple fabrication and ease of use. To prevent side effects on the premolar and incisor regions from the pendulum springs, many modifications have been made to yield optimal clinical results.⁴In the sagittal plane, molar distalization occurred at the expense of the mild proclination of the maxillary anterior teeth due to reciprocal mesial force, thus causing anchorage loss.⁵Side effects on distalized molars are the mesial rotation caused by palatal force application and the extrusion that are similar but less than with double distalization.⁶Influence of second molar on the distal movement of the first molar remains a matter of debate. Some authors reported that presence of second molars increases treatment duration, produces more tipping of molars,⁷ and more anterior anchorage loss.⁸

6. Conclusion

For attainment of molar distalization Pendulum appliance was found to be efficient, non-invasive and non-compliant appliance where 4 mm of distalization was achieved in 4

months and occlusion was settled with class I molar and class I canine relation.

7. Conflicts of Interest

All contributing authors declare no conflicts of interest.

8. Source of Funding

None.

References

1. Sfondrini M, Cacciafesta V, Sfondrini G. Upper molar distalization: a critical analysis. *Orthod Craniofac Res.* 2002;5(2):114–26.
2. Almuzian M, Alharbi F, White J, McIntyre G. Distalizing maxillary molars-how do you do it? *Orthodontic Update.* 2016;9(2):42–50. doi:10.12968/ortu.2016.9.2.42.
3. Hilgers JJ. The Pendulum appliance for class II non-compliance therapy. *J Clin Orthod.* 1992;26(11):706–20.
4. Kinzinger G, Fuhrmann R, Gross U, Diedrich P. Modified pendulum appliance including distal screw and uprighting activation for non-compliance therapy of Class II malocclusion in children and adolescents. *J Orofac Orthop.* 2000;61(3):175–90. doi:10.1007/s000560050003.
5. Siatkowski RE. Asymmetric Headgear in Nanda(Red) Biomechanics in Orthodontics. Philadelphia, Pa, USA: W.B. Saunders; 1997.
6. Ghosh J, Nanda RS. Evaluation of an intraoral maxillary molar distalization technique. *Am J Orthod Dentofacial Orthop.* 1996;110(6):639–46. doi:10.1016/s0889-5406(96)80041-2.
7. Gianelly AA, Bednar J, Dietz VS. Japanese Ni-Ti coils used to move molars distally. *Am J Orthod Dentofac Orthop.* 1991;99(6):564–6. doi:10.1016/S0889-5406(05)81633-6.
8. Bondemark L, Kurol J, Bemhold M. Repelling magnets versus superelastic nickel-titanium coils in simultaneous distal movement of maxillary first and second molars. *Angle Orthod.* 1994;64(3):189–98. doi:10.1043/0003-3219(1994)064<0189:RMVSNC>2.0.CO;2.

Author biography

Nivedita Nandeshwar, Assistant Professor

Sujoy Banerjee, Associate Professor and Reader

Rashmi Jawalekar, Professor and HOD

Usha Shenoy, Professor and HOD

Cite this article: Nandeshwar N, Banerjee S, Jawalekar R, Shenoy U. Class II correction by maxillary molar distalization with pendulum appliance - A case report. *J Dent Spec* 2021;9(1):26-28.