



Case Report

Prong maxillary complete denture for better facial aesthetic: A case report

Neha Pathania^{1,*}, Jenny Lalmalswami Sailo¹, Sabat Un Noor¹, Archana Nagpal¹, Mamata Mahajan¹

¹Dept. of Prosthodontics, Himachal Dental College, Sundar Nagar, Himachal Pradesh, India



ARTICLE INFO

Article history:

Received 18-06-2021

Accepted 24-09-2021

Available online 09-10-2021

Keywords:

Prosthodontics

Unconventional complete dentures

Labial fullness

Prong (Flangeless)

Wing denture

ABSTRACT

Denture teeth and denture flange are two very important aspects of a complete denture. For aesthetic purpose while fabricating the complete denture prosthesis, restoring the labial fullness is a sensitive procedure. There are some clinical situations where the labial flange gives poor facial aesthetics. It is more occur in proclined maxillary anterior ridge or thick labial cortical plate with severe labial undercut. In this article we are presenting a case with thick labial cortical plates and severe labial undercut. So, we have modified the complete denture and delivered a prong (flangeless) denture to give more aesthetic appearance to the patient.

This is an Open Access (OA) journal, and articles are distributed under the terms of the [Creative Commons Attribution-NonCommercial-ShareAlike 4.0 License](https://creativecommons.org/licenses/by-nc-sa/4.0/), which allows others to remix, tweak, and build upon the work non-commercially, as long as appropriate credit is given and the new creations are licensed under the identical terms.

For reprints contact: reprint@ipinnovative.com

1. Introduction

In prosthodontics during complete denture fabrication, we have to come across different types of ridge anatomy. Ridge anatomy may differ from patient to patient from massive ridges to severely resorbed ridges. Complete dentures gives more esthetic appearance if its labial fullness is accurate. An excessively prominent ridge more commonly present in maxilla than mandible.¹

Its very challenging to fabricate the complete denture when the ideal biological consideration of both hard and soft tissues are not fulfilled.² Labially proclined maxilla with associated undercut is the most common condition that effects the esthetics and fabrication of complete denture.³ Sometimes prior to the construction of a complete denture there are some abnormal conditions which can be corrected by surgically, but that is not always possible.⁴ It is also essential to differentiate certain systemic conditions or syndromes that incapacitate the individual from using his surrounding musculature to aid in holding the prosthesis.⁵

* Corresponding author.

E-mail address: drnehapathania737@gmail.com (N. Pathania).

In those cases we can add some modifications in dentures which is also called unconventional complete dentures. This case report presents a non-surgical procedure of complete denture fabrication and producing an esthetic appearance in proclined maxillary anterior ridge with severe labial undercut with the help of prong (flangeless) denture. Many authors have referred to this as “gum fit dentures” and “ridge grip esthetic prosthesis”.^{6,7}

2. Case Report

A fifty-six years old male patient came to the Department of Prosthodontics and Crown and Bridge, Himachal Dental College, Sundernagar with the chief complaint of missing teeth. He had been edentulous for last one year. Patient had history of smoking for last twenty-five years and had quit smoking one year back. This patient had tapered face with normal muscle tone and adequate lip length (Figure 1), as found on extraoral examination. An U-shaped maxillary arch with severe labial undercut on intraoral examination (Figure 2).

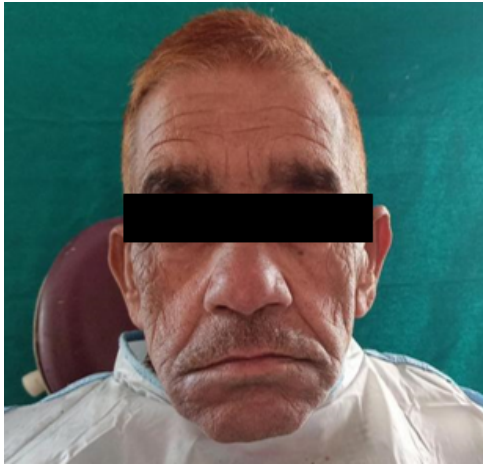

Fig. 1: Patient with tapered profile

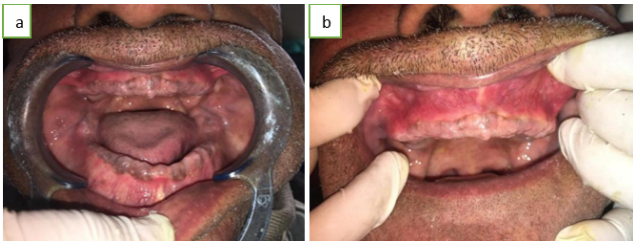


Fig. 2: (a) and (b) Severe Labial Undercut

Surgical procedures like alveoplasty and implant supported overdentures were explained to the patient, but the patient was not ready for any of the surgical treatment. A flangeless maxillary denture with conventional mandibular denture was planned and patient was explained about the problems with conventional denture. Impression compound was used to take the primary impression (Figure 3).

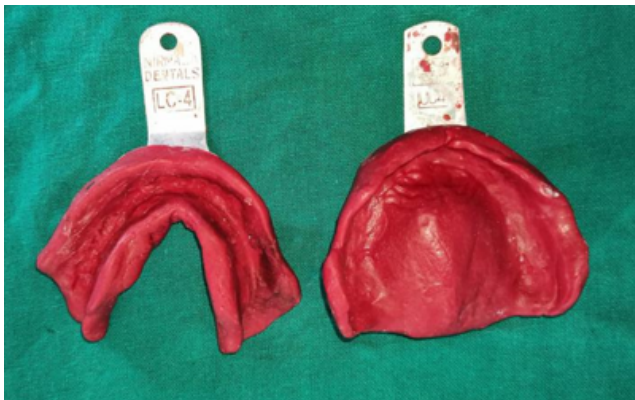


Fig. 3: Primary impression

Casts were poured in plaster of paris. After that special trays were fabricated and border moulding was done with green stick compound and secondary impressions were

made (Figure 4).

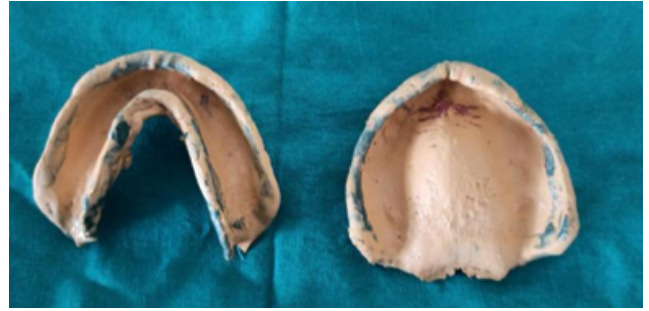


Fig. 4: Secondary impression

After making master casts, temporary base and occlusal rims were fabricated. Jaw relations were done same as in conventional dentures and then mounted on articulator and teeth arrangement was done.

After try in during wax-up the labial flange was removed from canine- to- canine region leaving two acrylic spikes extending anteriorly from distal sides (Figure 5).

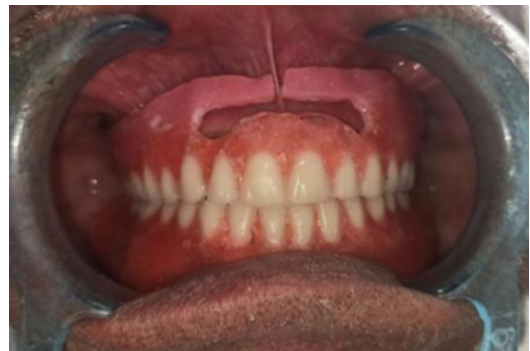

Fig. 5: Two acrylic spikes extending anteriorly from distal sides during try in.

Putty addition silicon impression material was placed on the labial flange and dewaxing was done (Figure 6)

Packing and curing of heat cure acrylic resin was done. After polishing the prong (flangeless) denture was delivered to the patient (Figure 7).

Follow up of the patient was done following 24 hours, one week and one month after post-insertion. Patient was having no complaints regarding the denture and completely satisfied with the prong denture (Figure 8). Post insertion instructions were given to the patient.

3. Discussion

The flangeless maxillary denture technique is a method to preview the aesthetic results, certain situations demand the same design to be incorporated in the final denture.^{8,9} These dentures have different names like wing denture, ridge grip, gum fit.^{10,11}

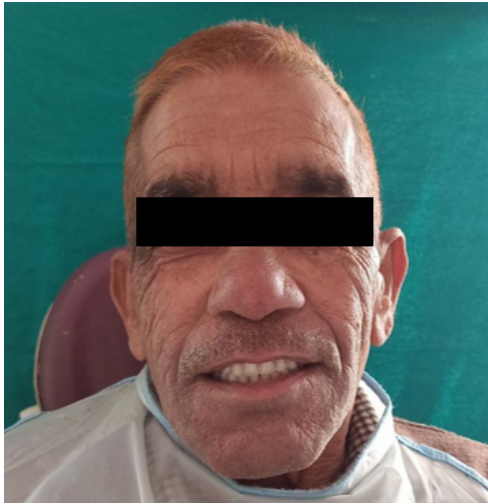

Fig. 8: Post insertion image

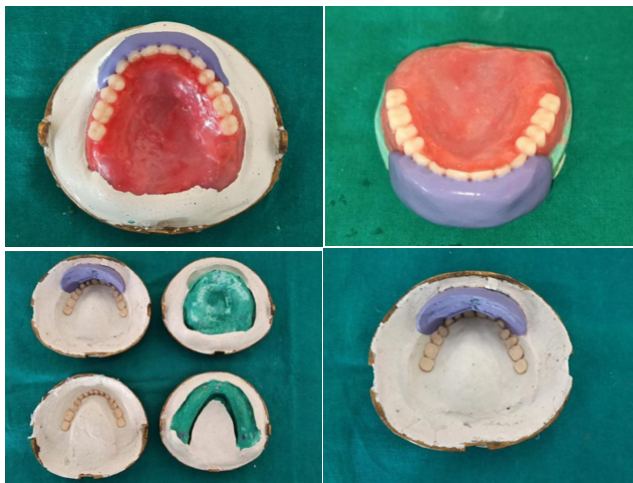

Fig. 6: Putty addition silicon impression material was placed on the labial flange.

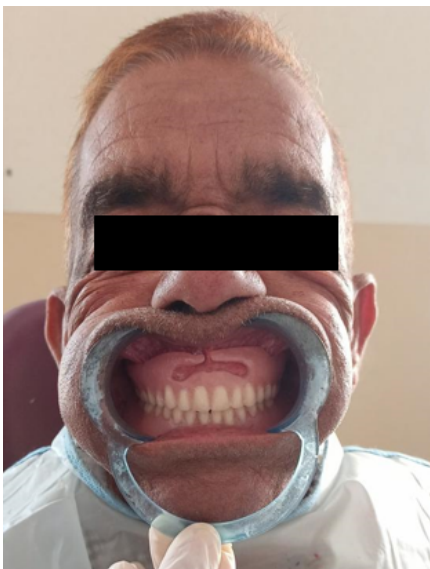

Fig. 7: Prong denture delivered

In some cases prominent modiolus is also altered, mainly medially (inwards and posteriorly). Upon combination with hypertonic maxillary lips, the vestibule space constantly shrinks unless the labial cortical plate does not undergo significant resorption.^{12,13} If a conventional denture would have been fabricated, it would add to severe labial fullness and an unaesthetic appearance. The excessive bulky labial flange would have also lead to interference with the phonetics.¹⁴

Another modification as given in the literature is “Wing denture”. Here the labial flange is sectioned in the labial frenum region and two wings appear from either side to allow space for the labial frenum.^{15,16}

4. Conclusion

A prosthodontist should attempt to make the complete denture as unique and customized as far as possible for each individual.

Flangeless dentures give a simple and easy alternative for patients, not opting for surgical options for the correction of over-contoured ridges. They are successful in giving the satisfactory aesthetics and better patient acceptance.¹⁷ The obliteration of labial vestibule impacts complete denture fabrication. Hypertonic maxillary lip and overactive modiolus obliterates the labial vestibule. Above two parameters should be included in routine patient data collection, while examining the complete edentulous patients.¹⁸

Our clinical report describes the fabrication of an economical, quick and easy method of fabrication of a prong denture for rehabilitation of proclined maxillary ridge with presence of labial undercut. Nonsurgical procedures can thus be utilized for the fabrication of the prosthesis as they are non-invasive, provides good acceptance, and ultimate satisfaction to the patient. The prong dentures are convenient in terms of insertion, removal and function for the edentulous patient.^{19,20}

5. Conflicts of Interest

All contributing authors declare no conflicts of interest.

6. Source of Funding

None.

References

1. Moaleem MA, Alkhayrat FM, Madkhali HA, Geathy IH, Qahhar M, Yaqoub A, et al. Subjective differences between dentists and patients about relative quality of metal ceramic restorations placed

- in the esthetic zone. *J Contemp Dent Pract.* 2017;18(2):112–6. doi:10.5005/jp-journals-10024-2000.
2. Boucher CO. Rehabilitation of the edentulous patient: fabrication of complete dentures. In: Zarb G, Bolender C, Carlsson G, editors. Boucher's prosthodontic treatment for edentulous patients 12th Edn. St Louis: Mosby; 2004. p. 209–72.
 3. Esposito SJ. Esthetics for denture patients. *J Prosthet Dent.* 1980;44(6):608–15. doi:10.1016/0022-3913(80)90456-4.
 4. Rahman S, Deep A, Mattoo KA. Bony exostoses on hard palate - Prosthetic inferences. *Arch Dent Oral Health.* 2019;2(2):1–3.
 5. Areej AG, Mattoo KA. Complete edentulous rehabilitation of a down's syndrome patient also being treated for schizophrenia. *J Med Sci Clin Res.* 2018;6(7):856–60. doi:10.18535/jmscr/v6i7.141.
 6. Ogle RE. Preprosthetic surgery. *Dent Clin North Am.* 1997;21(2):219–36.
 7. Jain AR. Ridge grip esthetic prosthesis: an alternative conventional removable partial denture- a case report. *Am J Oral Med Radiol.* 2015;2(1):44–6.
 8. Obwegeser H. Surgical preparation of the maxilla for prosthesis. *J Oral Surg Anesth Hosp Dent Serv.* 1964;22:127–34.
 9. Nandita K, N. Aras Meena A. Modified flange complete denture for labially inclined premaxilla. *Indian J Dent Advancements.* 2010;.
 10. Suganya R, Jain AR, Krishnan CJV, Chandran R. Ridge grip esthetic prosthesis: an alternative conventional removable partial denture: A case report. *Am J Oral Med Radiol.* 2015;2:44–6.
 11. Jeganathan S, Thean HP, Thong KT, Chan YC, Singh M. A clinically viable index for quantifying denture plaque. *Quintessence Int.* 1996;27(8):569–73.
 12. Sutton DN, Lewis BR, Patel M, Cawood JI. Changes in facial form relative to progressive atrophy of the edentulous jaws. *Int J Oral Maxillofac Surg.* 2004;33(7):676–82. doi:10.1016/S0901-5027(03)00132-2.
 13. Bidra AS. Three-dimensional esthetic analysis in treatment planning for implant-supported fixed prosthesis in the edentulous maxilla: Review of the esthetics literature. *J Esthet Restor Dent.* 2011;23(4):219–36. doi:10.1111/j.1708-8240.2011.00428.x.
 14. Krall E, Hayes C, Garcia R. How dentition status and masticatory function affect nutrient intake. *J Am Dent Assoc.* 1998;129(9):1261–9.
 15. Krajcicek D. Guides for natural facial appearance as related to complete denture. *J Prosthet Dent.* 1969;21(6):654–62. doi:10.1016/0022-3913(69)90014-6.
 16. Mittal R, Kapoor A, Mattoo KA. Gender differences in terms of recalling treatment instructions - an in vivo study. *J Med Sci Clin Res.* 2018;6(7):848–55. doi:0.18535/jmscr/v6i7.140.
 17. Hillerup S. Preprosthetic surgery in elderly. *J Prosthet Dent.* 1994;72(5):551–8.
 18. Glossary of prosthodontic terms. *J Prosthet Dent.* 2005;94(1):10–92. doi:10.1016/j.prosdent.2005.03.013.
 19. Manjreker NS. Flangeless Denture: a simple yet novel approach for management of severe labial undercuts in edentulous patients. *IOSR J Dent Med Sci.* 2017;16(1):44–6.
 20. Jagger DC, Harrison A. Complete dentures - the soft option. An update for general dental practice. *Br Dent J.* 1997;182(8):313–7.

Author biography

Neha Pathania, Post Graduate 2nd Year

Jenny Lalmalswami Sailo, Post Graduate 3rd Year

Sabat Un Noor, Post Graduate 1st Year

Archana Nagpal, Professor and HOD

Mamata Mahajan, Reader

Cite this article: Pathania N, Sailo JL, Noor SU, Nagpal A, Mahajan M. Prong maxillary complete denture for better facial aesthetic: A case report. *J Dent Spec* 2021;9(1):22-25.