



Original Research Article

Comparison of effectiveness of calcium hydroxide and MTA when used as an indirect pulp therapy (IPT) material- A clinical and radiological assessment

Divyashree R^{1,*}, Kirthi Raj¹¹Dept. of Pedodontics, Kirti Eye & Dental Hospital, Bengaluru, Karnataka, India

ARTICLE INFO

Article history:

Received 09-04-2020

Accepted 03-06-2020

Available online 21-07-2021

Keywords:

Dycal

MTA

Indirect pulp capping

Reparative dentine

Pulp vitality

ABSTRACT

Aim of the study: The present study assessed and compared the success of an IPT procedure both clinically and radiographically when Dycal and MTA were used as an IPT material on primary molars.

Materials and Methods : Children aged 4-9 years were screened and those who fulfilled the inclusion criteria were selected. Accordingly fifty children were divided into 2 groups with 25 patient in each group. Cavity preparation was done and the two test materials (Dycal and MTA) were placed at the base in their respective groups and restored with RMGIC. Post-operative radiograph was taken for baseline data. Patients were assessed at Subsequent at 1 and 6 months both clinically and radiographically.

Results: Both the test materials had formed a good biological seal, arrested further caries progression and did not cause any adverse pulpal reaction. However the amount of reparative dentin formed was highest in the Dycal group followed by MTA group.

Conclusion: Both the experimental materials Dycal and MTA showed reparative dentin formation at the end of 1 and 6 months and also formed a good biological seal and maintained vitality of the pulp which indicates both are good IPT material.

© This is an open access article distributed under the terms of the Creative Commons Attribution License (<https://creativecommons.org/licenses/by/4.0/>) which permits unrestricted use, distribution, and reproduction in any medium, provided the original author and source are credited.

1. Introduction

Indirect pulp capping has been described as a conservative alternative treatment of the dentin-pulp complex, for primary and permanent teeth, since 1859 by John Tomes. The ADA defines this procedure as a “Procedure in which the nearly exposed pulp is covered with a protective dressing to protect the pulp from additional injury and to promote healing and repair via formation of tertiary dentin.” It is a procedure in which the non-remineralizable tissue is removed and a thin layer of caries is left in the deepest sites of the cavity thereby avoiding the possibility of a pulp exposure.¹

Traditionally various materials have been used for Indirect Pulp therapy procedure like Calcium hydroxide, Corticosteroids, Bonding agents, Cyanoacrylates, MTA, Lasers etc. Historically, Calcium

hydroxide has been a gold standard for pulp capping.² The popularity of Calcium hydroxide and calcium oxide based materials for direct and indirect pulp capping is due to their ability to release hydroxyl and calcium ions upon dissolution.³ Many commercial products of calcium hydroxide are available in the market for Indirect Pulp treatment among which Dycal is the most preferred. Dycal is a self-setting radiopaque calcium hydroxide-based material employed in direct and indirect pulp capping procedures and as a liner under restorations, cements and other base materials.⁴

Unfortunately, this material has some disadvantages like solubility, degradation over time, tunnel defects through dentinal bridges under it, poor sealing properties and raise in the local pH with the formation of a necrotic layer at the material-pulp interface.⁵ There is a weaker chemical effect on the sub adjacent and apical tissue which results in a zone of coagulation necrosis.⁶ Considering these disadvantages of calcium hydroxide products the quest for better materials

* Corresponding author.

E-mail address: divyashree.rswamy@yahoo.in (Divyashree R).

continued.

Dr. Mahmoud Torabinejad in 1990's at the Loma Linda university developed Mineral Trioxide Aggregate (MTA) cement as a root end filling material. The major constituents of this material is dicalcium silicate, tricalcium silicate, and tricalcium aluminate & tetra calcium aluminoferrite & bismuth oxide. MTA exhibits calcified tissue-conductive activity and facilitate the differentiation of human Orofacial mesenchymal stem cells. It has the potential to facilitate mineralization process in human dental pulp which makes it successful to be used as an effective pulp capping agent.⁷

With the advent of technology and quest for newer material has prompted the clinicians to explore the remineralizing abilities of various other materials like Stem cells, Propolis, Bio dentine and Emdogain so on so forth.

However, there is a paucity in literature of studies to compare the effectiveness of these two test material when used as an IPT materials for primary teeth. Hence, this study is being undertaken to evaluate the clinical and radiographic success.

2. Aim

To compare the effectiveness of Calcium hydroxide and MTA when used as Indirect Pulp Capping (IPT) materials for primary teeth.

3. Objectives

1. To assess the reparative dentine formation of $\text{Ca}(\text{OH})_2$ and MTA when used as IPT material both clinically and radiographically.
2. To compare the reparative dentine formation of $\text{Ca}(\text{OH})_2$ and MTA when used as IPT material both clinically and radiographically.

4. Materials and Methods

4.1. Armamentarium

1. Disposable Surgeon's cap (Dispodent)
2. Mouth mask (Suraksha)
3. Sterile gloves (Dispodent)
4. Mouth mirror and Explorer.
5. Pair of tweezers
6. Cotton rolls
7. Single use syringe-2 ml (Uniolok)
8. Local Anesthesia - (Lignox 2 % - Lignocaine hydrochloride 2% with 1:80,000 adrenaline)
9. Rubber Dam (Hygienic-Dental Dam kit)
10. Saliva ejection tips
11. Spoon Excavator
12. Contra angle aerotor handpiece (NSK)
13. Round Diamond Dental Burs (Mani-No 2 & 4)
14. Calcium hydroxide (Dycal, Dentsply)
15. Ball ended condenser tip

16. MTA (Angelus)
17. Amalgam carrier
18. Resin Modified Glass Ionomer Cement (RMGIC)
19. Agate spatula
20. Articulating paper
21. PSP sensor plate
22. PSP scanner (Digora)
23. Position Indicating Device (XCP Holder)

4.2. Study design

The present study was a randomized controlled in vivo study between Dycal and MTA as indirect pulp capping agents in primary molars.

4.3. Source of data

The present in vivo study was conducted on 50 children in the age group of 4-9 years of both sexes, who visited the Department of Pedodontics and Preventive Dentistry

4.4. Sample selection

The sample size included 50 primary molars indicated for indirect pulp capping procedure. The study subjects were randomly divided into three groups of carrying 25 teeth each according to the indirect pulp capping agents used.

Group 1 - Dycal (25 teeth)

Group 2 - MTA (25 teeth)

4.5. Method of collection of data

The samples to each group were selected using random sampling technique.

5. Clinical

5.1. Inclusion criteria

1. History of tolerable dull intermittent pain, mild discomfort associated with eating, negative history of spontaneous extreme pain.
2. On clinical examination, large carious lesions involving either the occlusal or proximal surfaces, with normal appearances of gingiva.
3. Radiographic examination showing carious lesion involving more than $\frac{2}{3}$ ^{rd.} thickness of dentin approximating the pulp, normal lamina dura, normal periodontal ligament space, more than $\frac{2}{3}$ ^{rd.} of root present, no periapical changes, no pathologic external or internal resorption.

5.2. Exclusion criteria

1. History of sharp, penetrating pulpalgia indicating acute pulpal inflammation and necrosis, prolonged spontaneous pain at night.

2. Clinical examination showing presence of mobility of tooth, discoloration of tooth, negative reaction to electric pulp testing, sinus opening, or abscessed tooth.
3. Radiographic examination showing carious lesion with definite pulp exposure, interrupted or broken lamina dura, widened periodontal ligament space, periapical radiolucency, internal or external resorption.

5.3. Methodology and clinical procedure

Patients were screened initially to determine whether they met the study inclusion criteria and thus the qualified patients were enrolled in the study.

Informed parental and patient consent and ethical clearance was taken from the Institutional Ethical Committee.

Total of 50 subjects were divided into two group based on random sampling method:

5.4. Groups

Group I - 25 subjects (Dycal group)

Group II - 25 subjects (MTA group)

After screening profound administration of local anaesthesia using LIGNOX 2% (Lignocaine hydrochloride 2% with 1:80,000 adrenaline) was done and the tooth was isolated with rubber dam (Hygenic). The caries was removed either by a spoon excavator or round diamond dental bur (no 2) using a hand piece running at a slow speed & copious water irrigation leaving behind the affected dentin.

5.4.1. Group 1: Dycal group

Following caries removal, Calcium hydroxide (Dycal) was mixed with equal quantities of both the catalyst and the base paste to a homogenous mix according to the manufacturer's instructions and was applied to the base of the cavity using a ball ended condenser.

5.4.2. Group 2: MTA group

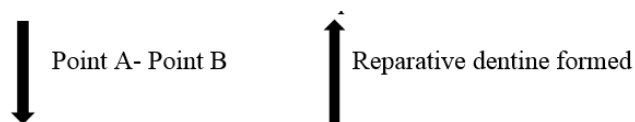
Following caries removal, MTA powder was mixed with sterile water for 30 seconds so as to get a sandy consistency according to the manufacturer's instructions and was placed on the floor of the cavity using an amalgam carrier. It was adapted using light pressure with moist cotton pellets.

Following the placement of the test materials the tooth was subsequently restored with RMGIC to ensure a proper seal in each case.

In all the two groups, after the completion of indirect pulp capping with respective agents, a baseline radiograph was made. Subsequently, at one, three and six months, the tooth was evaluated clinically and radiographically evaluated by taking x rays. Measurements of the digitized radiographs were performed at baseline, and was done at first, third and sixth months. The increase in dentin thickness

was measured using Corel Draw software (Version 17) keeping cement-enamel junction and the highest point on the floor of pulp chamber as reference points and the measurements were made till the base of the restoration. The amount of dentin deposited at each time interval was calculated by the difference in the values obtained from the baseline and follow up radiographs.

As the reparative dentine is formed the linear distance between Point A- Point B reduces which inversely reports that there is increase in the reparative dentine which is being formed.



5.5. Clinical and radiographic evaluation

Clinical and radiographic Evaluation was done at the end of 1st, 3rd and 6th months.

5.5.1. Criteria for clinical success

1. No pain
2. No sensitivity to percussion
3. No swelling and/or fistula
4. No pathologic tooth mobility
5. Retention of the restoration (Marginal integrity)

5.5.2. Criteria for radiographic success:

1. Formation of reparative dentine
2. No radiolucency in periapical or furcation area
3. No widening of periodontal ligament space
4. No external or internal resorption

5.6. Statistical analysis

The Statistical Analysis were done using SPSS v.22 software IBM., Corp. A descriptive analysis of the data is presented as frequency, mean, and standard deviation (SD).

One-way ANOVA test followed by Tukey's Post hoc Analysis is used to compare the mean thickness of the reparative dentin between the study groups at each time period.

Repeated measures of ANOVA will be used to compare the mean difference between different time intervals [1st Month & 6th Month] within the same study group. The level of significance will be set at P<0.05.

6. Results

The results of the present study were tabulated and analyzed under the following headings.

Anova test was done for intragroup comparison at different time intervals in Group 1. The table shows that

Table 1: Age and Gender Distribution among study subjects in 03 groups

Variables	Category	Group 1		Group 2		Group 3		P-Value
		Mean	SD	Mean	SD	Mean	SD	
Age	Mean & SD	6.9	1.4	7.6	1.3	7.4	1.1	0.13 ^a
	Range	5 - 9		5 - 9		5 - 9		
Gender		n	%	n	%	n	%	0.06 ^b
	Males	15	60%	8	32%	16	64%	
	Females	10	40%	17	68%	9	36%	

Table 2: The mean distance from point A- point B (in mm) between 02 study groups at different time intervals using One-way ANOVA Test

Time	Groups	N	Mean	SD	Min	Max	F	P-Value
Baseline	Group 1	25	0.4305	0.1006	0.226	0.609	2.275	0.11
	Group 2	25	0.4998	0.1408	0.318	0.793		
1 month	Group 1	25	0.3296	0.0905	0.129	0.457	12.743	<0.001*
	Group 2	25	0.4471	0.1005	0.301	0.672		
6 months	Group 1	25	0.2768	0.0892	0.115	0.436	9.085	<0.001*
	Group 2	25	0.3828	0.1365	0.170	0.657		

Table 3: Comparison of mean distance from point A- pointB(in mm) between different time intervals in Group 1 using Repeated measures of ANOVA test

Time	N	Mean	SD	Greenhouse Geisser	
				F	P-Value
Baseline	25	0.4305	0.1008	47.816	<0.001*
1 month	25	0.3296	0.0902		
6 months	25	0.2768	0.0895		

Group 1 showed there is a highly statistically significant difference (P- Value <0.001*) at different time interval, that is at the end of one and six months.

Anova test was done for intragroup comparison at different time intervals in Group 2. The table shows that Group 2 showed there is a highly statistically significant difference (P- Value <0.001*) at different time interval, that is at the end of one and six months.

One way ANOVA test was used to compare the mean reparative dentin thickness (in mm) among the experimental groups at different time intervals. There was highly statistically significant difference among the two experimental groups at the end of 1st month (P-Value 0.003*). There was no statistically significant difference among all the two experimental groups at the end of 1st month. There was highly statistically significant difference among all the experimental groups at the end of 6th month (P-Value <0.001*)

7. Discussion

The rationale for IPT is based on the observation that post mitotic odontoblasts can be induced to up-regulate their synthetic and secretory activities in response to reduced infectious challenge. This results in deposition of tertiary dentine formation which increases the distance between caries and pulp cells by deposition of peritubular dentin

which decreases the dentin permeability.⁸ The rate of reparative dentine formation is 1.4um/day after cavity preparation. The rate of reparative dentin formation is highest in the 1st month and then diminished with time, it continues upto a period of 9-12 months but at a slower rate.⁹

Since the introduction by Hermann in 1930, Ca(OH)₂-based materials have been widely used as therapeutic agents for Indirect Pulp Capping and other procedures. The benefits of Ca(OH)₂ include low thermal conductivity, an ability to act as a buffer against the zinc oxide cements commonly used in direct restorations, and the release of hydroxide and calcium ions upon dissolution. The hydroxide ions raise the local pH to approximately 12, thereby exerting antimicrobial and anti-inflammatory effects. The release of calcium enhances the activity of pyro phosphatase, which aids the maintenance of dentin mineralization and the formation of a dentin bridge.

Certain disadvantages of Ca(OH)₂ led to examine newer materials, such as mineral trioxide aggregate (MTA), which displays excellent potential in endodontic applications such as direct pulp capping. However, it has a slower setting time, initial looseness, poor handling characteristics, and is comparatively expensive.

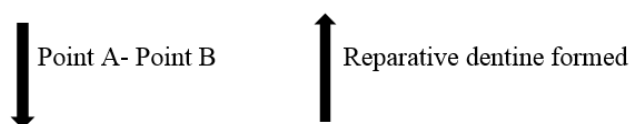
As the reparative dentine is formed the linear distance between Point A- Point B reduces which inversely reports that there is increase the reparative dentine which is being formed.

Table 4: Comparison of mean from point A- point B(in mm) between different time intervals in Group 2 using Repeated measures of ANOVA test

Time	N	Mean	SD	Greenhouse Geisser	
				F	P-Value
Baseline	25	0.4998	0.1405	17.947	<0.001*
1 month	25	0.4471	0.1368		
6 months	25	0.3828	0.1001		

Table 5: The mean Reparative dentin thickness (in mm) between 02 study groups at different time intervals using One-way ANOVA Test

Time	Groups	N	Mean	SD	Min	Max	F	P-Value
BL - 1m	Group 1	25	0.1008	0.1056	-0.100	0.380	6.179	0.003*
	Group 2	25	0.1048	0.0419	0.010	0.280		
BL - 6m	Group 1	25	0.1534	0.1061	-0.090	0.390	9.086	<0.001*
	Group 2	25	0.1166	0.0481	0.000	0.280		



The results of our study revealed that, the mean distance between point A- point B at the baseline in Dycal group was 0.4305 mm. On intra-group comparison of Dycal group the distance by the end of 1st month it was recorded as 0.3296 mm. By the end of 6 months the distance has reduced to 0.2768mm therefore the reparative dentine formed was around 0.1533mm by the end of 6 months from baseline.

An in vivo study was conducted by George et al evaluating the efficacy of Dycal as IPT material for a period of 6 months. By the end of 6 months the material showed deposition of reparative dentine about 0.097 mm and had 100% success rate. The study concluded that both clinically and radiographically Dycal has proven to be a good IPT material for primary teeth.¹⁰ In another study by of Leye Benoist et al, showed 0.085 mm of increase in dentin thickness over a period of 6 months.¹¹ These two studies were in accordance with our study.

Mechanism of Tertiary dentin deposition in response to calcium hydroxide is mediated via alkaline phosphatase enzyme, stimulated by hydroxyl ions at pH 10.2 and calcium-dependent pyro-phosphatase. Heithersay suggested that calcium ions reduce the permeability of capillaries so that less interstitial fluid is produced, thus calcium ions concentrate at the mineralization site. The mineral deposition is presumably by calcium derived from the blood supply of the dental pulp. This indicates that calcium hydroxide is an initiator rather than a substrate for Tertiary dentin deposition. Calcium hydroxide showed Tertiary dentin deposition in lesser number of specimens at 6 weeks, probably indicating that it requires longer time to respond to calcium hydroxide when used as IPT material.¹²

The mean distance between point A- point B at the baseline in MTA group was 0.4998mm. On intra-group comparison of MTA the mean distance at the end of 1st

month it was recorded as 0.4471 mm. By the end of 6 months the distance has reduced to 0.3828 mm therefore the amount of reparative dentine formed at the end of 6 months is around 0.116mm.

Leye Benoist et al¹¹ showed 0.121 mm of increase in dentin thickness over 6 months when MTA was used an IPT material for 30 primary molars for a period of 6 months. The values of dentinogenesis quoted by various authors in the above-mentioned studies are in par with the present study.

7.1. However the limitations of the study included

1. Sufficient (setting) time was not given between the placement of MTA and the access fill material which could have affected the reparative dentine formation with MTA.

7.2. Within the limitation of the study, the following conclusions were drawn:

1. Both the experimental materials Dycal and MTA showed reparative dentin formation at the end of 1 and 6 months.
2. Both the test material formed a good biological seal and maintained vitality of the pulp which indicates both are good IPT material.

8. Conflict of Interest

The authors declare that there are no conflicts of interest in this paper.

9. Source of Funding

This research did not receive any specific grant from funding agencies in the public, commercial, or not-for-profit sectors.

References

1. American Academy on Pediatric Dentistry Clinical Affairs Committee-Pulp Therapy subcommittee, American Academy on

- Pediatric Dentistry Council on Clinical Affairs. *Pediatr Dent*. 2008;30(7):170–4.
2. Qureshi A, Soujanya E, Nandakumar, Pratapkuma, Sambashivarao. Pratapkumar null, Sambashivarao null. Recent advances in pulp capping materials: an overview. *J Clin Diagn Res*. 2014;8(1):316–21. doi:10.7860/JCDR/2014/7719.3980.
 3. Mohammadi Z, Dummer P. Properties and applications of calcium hydroxide in endodontics and dental traumatology. *Int Endod J*. 2011;44(8):697–730. doi:10.1111/j.1365-2591.2011.01886.x.
 4. Shen Q, Sun J, Wu J, Liu C, Chen F. An in vitro investigation of the mechanical-chemical and biological properties of calcium phosphate/calcium silicate/bismutite cement for dental pulp capping. *J Biomed Mater Res B Appl Biomater*. 2010;94(1):141–8.
 5. Schuurs AHB, Gruythuysen RJM, Wesselink PR. Pulp capping with adhesive resin-based compositevs.calcium hydroxide: a review. *Dent Traumatol*. 2000;16(6):240–50. doi:10.1034/j.1600-9657.2000.016006240.x.
 6. Stanley HR. Pulp capping: Conserving the dental pulp-Can it be done? Is it worth it? . *Oral Surg Oral Med Oral Pathol*. 1989;68(5):628–39.
 7. Camilleri J, Ford TP. Mineral trioxide aggregate: a review of the constituents and biological properties of the material. *Int Endod J*. 2006;39(10):747–54. doi:10.1111/j.1365-2591.2006.01135.x.
 8. Bjørndal L, Larsen T, Thylstrup A. A Clinical and Microbiological Study of Deep Carious Lesions during Stepwise Excavation Using Long Treatment Intervals. *Caries Res*. 1997;31(6):411–7. doi:10.1159/000262431.
 9. Singhal M, Chaudhary CP, Anand R, Singh N, Sahni T. RECENT ADVANCEMENTS OF INDIRECT PULP CAPPING IN PRIMARY TEETH: A REVIEW. *J Adv Med Dent Sci Res*. 2015;3(5):5.
 10. Varma B, Kumaran P, Xavier AM, George V, Janardhanan SK. Clinical and radiographic evaluation of indirect pulp treatment with MTA and calcium hydroxide in primary teeth (in-vivo study). *J Adv Med Dent Sci Res*. 2015;33(2):104. doi:10.4103/0970-4388.155118.
 11. Benoist FL, Ndiaye FG, Kane AW, Benoist HM, Farge P. Evaluation of mineral trioxide aggregate (MTA) versus calcium hydroxide cement (Dycal®) in the formation of a dentine bridge: a randomised controlled trial. *Int Dent J*. 2012;62(1):33–9. doi:10.1111/j.1875-595x.2011.00084.x.
 12. Shah N, Korwar A, Sharma S, Logani A. Pulp response to high fluoride releasing glass ionomer, silver diamine fluoride, and calcium hydroxide used for indirect pulp treatment: An in-vivo comparative study. *Contemp Clin Dent*. 2015;6(3):288–92. doi:10.4103/0976-237x.161855.

Author biography

Divyashree R, Student

Kirthi Raj, Student

Cite this article: Divyashree R, Raj K. Comparison of effectiveness of calcium hydroxide and MTA when used as an indirect pulp therapy (IPT) material- A clinical and radiological assessment. *J Dent Spec* 2020;8(2):56-61.