



Original Research Article

Decoding the facial asymmetry

Abhinav Bhardwaj^{1,*}, Anil Miglani¹, Monika Gupta¹¹Dept. Of Orthodontics and Dentofacial Orthopaedics, I.T.S. Dental College Hospital & Research Centre, Greater Noida, Uttar Pradesh, India

ARTICLE INFO

Article history:

Received 07-10-2020

Accepted 17-10-2020

Available online 23-11-2020

Keywords:

Centric relation

Asymmetry

Deprogramming

ABSTRACT

Introduction: When degree of facial asymmetry is noticeable, it negatively affects facial and smile esthetics. It may due to discrepancies in size and position between cranial base and maxilla/ mandible. Asymmetry due to occlusal interference may result in functional shift of the mandible which usually poses a challenge. So diagnosis and functional examination are keys to an esthetic and stable outcome.

Objectives: This case report addresses the facial asymmetry in an adult patient who sought for improvement in facial appearance and occlusion.

Case description: A 26-year old male patient reported with chief complaint of noticeable facial asymmetry and irregularly positioned teeth. Clinical examination revealed mild facial asymmetry. Intraorally patient showed crowding, non-coincident dental midlines, anterior cross bite, missing 23 and root stump 46. Starting point in diagnosis and treatment of this case was establishing centric relation through guiding the mandible into centric relation rather than centric occlusion. During functional examination we observed discrepancy in CR-CO which was confirmed using PA-Ceph in centric rest position. Treatment was planned as deprogramming splint followed by fixed mechanotherapy. Post muscle deprogramming we were able to achieve “true” anatomic relationship of the mandible to the maxilla.

Conclusion: Thus, the present case report aims at addressing important aspect of functional examination to be considered by the orthodontist while reaching an accurate diagnosis and treatment plan in such patient’s with challenging asymmetry.

© This is an open access article distributed under the terms of the Creative Commons Attribution License (<https://creativecommons.org/licenses/by/4.0/>) which permits unrestricted use, distribution, and reproduction in any medium, provided the original author and source are credited.

1. Introduction

The term “asymmetry” is used to make reference to dissimilarity between homologous elements. Asymmetry of the face and dentition is a natural phenomenon. Facial asymmetry is defined as a difference in the size or shape of the sides of the face.¹ The face often presents with a mild degree of asymmetry, also known as relative symmetry or subclinical asymmetry. Minor facial asymmetry is common and can be observed in every individual.² Facial asymmetries can be classified as either developmental (agenesis, hypoplasia, or hyperplasia of the facial bones) or acquired (resulting from trauma, infection, or functional shifts).³ Functional shift due to CR-CO discrepancy is

challenging type of malocclusion for orthodontists. It is clinically characterized by facial asymmetry. There is a general agreement within the dental professional regarding achieving the ideal functional occlusion for our patients: centric relation. Centric relation (CR) can be termed as a musculoskeletal position which is anatomically determined and is repeatable as well as reproducible. On the other hand, centric occlusion (CO) or maximum intercuspation is a dental determined position. The mandible will shift (pathological or laterotrusion with secondary effects like abrasion) from CR to CO whenever the teeth make contact, if the dental occlusion is not stabilized in centric relation. Treating our patients in this position is one of our biggest challenge in orthodontics. This will provide long-term stability, improved functionality and esthetics, healthy

* Corresponding author.

E-mail address: abhistar356@gmail.com (A. Bhardwaj).

muscles and joints. Thus, the present case report aims at addressing important aspect of functional examination to be considered by the orthodontist while reaching an accurate diagnosis and treatment plan in such patient's with challenging disharmony.

1.1. Diagnosis and etiology

A 26 year old male patient reported to the Department of Orthodontics with the chief complaint of noticeable facial asymmetry and irregularly positioned teeth. Clinical examination revealed facial asymmetry with mandibular shift to the right side, straight profile (Figure 1). On manipulation to centric relation (CR), the interference was spotted on the lower anterior tooth region. To avoid this interference the patient habitually shifts the mandible to the right, distracting the condyles. Facial midline was not coinciding with dental midline which is shifted towards left. The lower midline was shifted approximately 3 mm to the right (Figure 2).

Intraorally the patient showed crowding, non-coincident dental midlines, and class I molar on left side and anterior cross bite, congenitally missing 23 and root stump in relation to 46 (Figure 3).

Cephalometric analysis (Table -1) showed skeletal a class III relation, horizontal growth pattern, right laterognathia, retroclined upper incisors and upper lip retrusion (Figures 4, 5 and 6).

1.2. Treatment objectives

Masseter and Temporalis are the key players in the action of mastication and in cases with CR-CO discrepancy the forces generated by the muscular activity changes. Thus muscle deprogramming can be used to induce a forced relaxation of the temporalis, masseter and pterygoid muscles allowing the temporomandibular joints to rest in a functionally comfortable position in the glenoid fossa. This functional asymmetry is reversible if caught in time and treated with bite plane therapy or permissive splint therapy. So muscle deprogramming to eliminating functional shift of mandible, correct CR-CO discrepancy and anterior cross bite was done in this patient. For most orthodontists, splint treatment prior to fixed appliance treatment would help to achieve accuracy of dental decompensation and long term stability by establishing a functional occlusion with healthy temporomandibular joints.

1.3. Treatment procedure and progress

Treatment began with full-time wearing of a deprogramming splint. The splint was made according to acentric bite registration. The dental casts were then mounted on a semi adjustable articulator (Figure 7). A full maxillary coverage splint with a flat occlusal plane touched every buccal cusp or incisal edge of the mandibular teeth

(Figures 8, 9 and 10). After deprogramming, the patient's face looked more symmetric than pre-treatment (Figure 11). The new mandibular position (Figure 12) was then retained by bite-blocks (Figure 13).



Fig. 1: Pre-treatment extra oral photographs

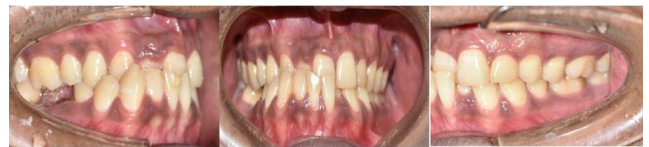

Fig. 2: Pre-treatment Intra oral photograph

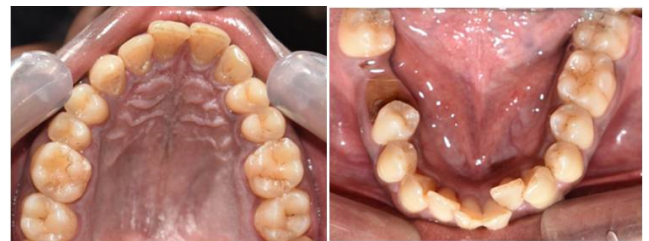

Fig. 3: Pre-treatment Intra oral photograph

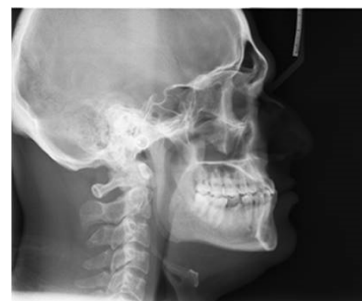

Fig. 4: Pre-treatment lateral cephalogram

2. Discussion

The face often presents with a mild degree of asymmetry, also known as relative symmetry or subclinical asymmetry.

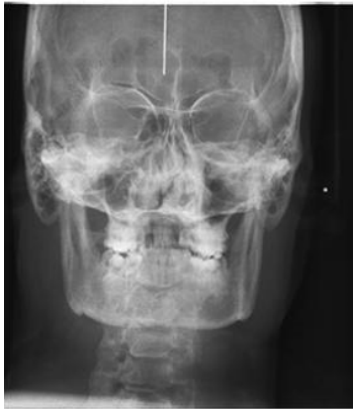

Fig. 5: Pre-treatment PA-Ceph



Fig. 8: Casts with maxillary splint

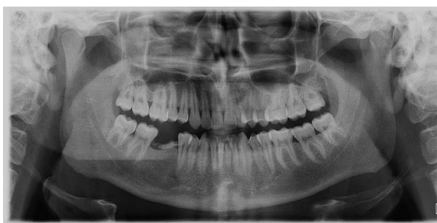

Fig. 6: Pre-treatment OPG

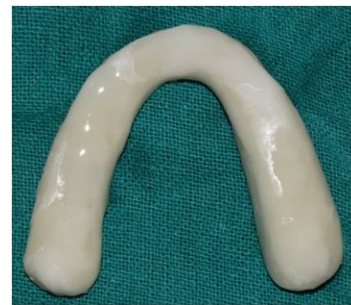

Fig. 9: Cold-cure acrylic maxillary splint



Fig. 7: Articulator mounted models

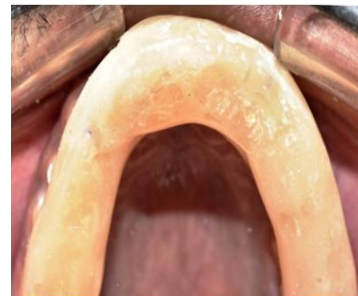

Fig. 10: Cemented maxillary splint

Minor facial asymmetry is common and can be observed in every individual. Facial asymmetries can be classified as either developmental (agenesis, hypoplasia, or hyperplasia of the facial bones) or acquired (resulting from trauma, infection, or functional shifts).⁴ Functional shift due to CR-CO discrepancy is challenging type of malocclusion for orthodontists. In present case facial asymmetry was due to functional shift. Patient had a CR-CO discrepancy resulting from the MFS which was caused by the discrepancy of the dental arch forms and the occlusal interferences. His mandible was forced to shift to the right to establish a workable occlusion; this suggested



Fig. 11: Extra oral post splint photograph

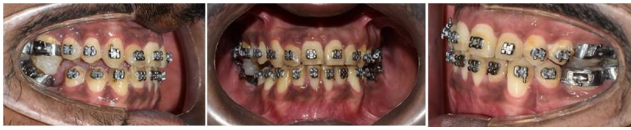

Fig. 12: Intra oral post splint photograph

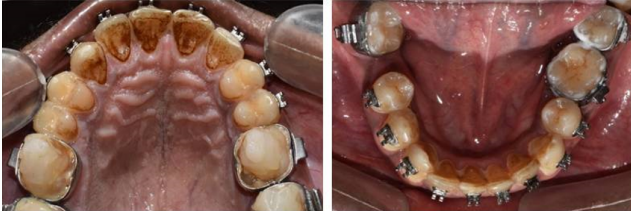

Fig. 13: Bracket placement and the adhesive bite-blocks

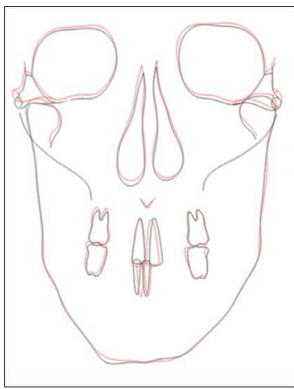


Fig. 14: Pre-post operative postero-anterior cephalometric superimposition

that the adaptive mandibular position and occlusion were established as compensation to the mandibular functional shift (MFS) and occlusal interference which resulted in skeletal asymmetry. Following the use of deprogramming splint which repositioned the laterally shifted mandible back to its physiologic position; which helped the mandibular midline to coordinate with the facial midline. The patient's style of opening became normal and stable functional occlusion was achieved with no occlusal interference. Similar studies by Wood et al. (2002)⁴ on the importance of the seated condylar position in orthodontic correction they found that fulltime wearing of the splint would eliminate the impact of dental interference and would allow physiologic condylar seating. McKee et al.⁵ in 2005 compared condylar positions achieved through bimanual manipulation to condylar positions achieved through masticatory muscle contraction against a deprogrammer splint which showed good stability, suggesting that the combination of splint and fixed appliance treatment is an effective method for treating MFS. Kusayama et al.,⁶ in 2003 compared the relationship between transverse dental anomalies and

skeletal asymmetry and stated that primary goal of treatment is to eliminate the asymmetry. If this remains during orthodontic treatment, the dental midline deviation and facial asymmetry would also remain while occluding. However, McKee (2005)⁵ evaluated articulated models in the seated condylar position from a deprogrammed population reported that condylar displacement may increase after splint treatment. According to Bryndahl et al.,⁷ at the habitual occlusal position, the patient is able to make more occlusal contacts but at the cost of the health of the TMJ and muscles of mastication. If left unattended the patient may end up in TMD with derangement of condyle disc assembly. The deprogramming splint given to the patient to deprogram the muscles from this distracted position and to move the condyle to a more optimal and stable position. So the objective should be to establish centric occlusion (CO) in CR position (CR = CO). The outcome of splint treatment in our case was satisfactory: the patient's face became symmetric, and the MFS was corrected. This meant that no intermaxillary elastics were needed to correct the midline discrepancy during fixed appliance treatment. According to McLaughlin et al.⁸ as long-term wearing of intermaxillary elastics might damage the TMJ, avoiding their use will benefit the stability of the newly acquired mandibular and condylar positions. However, the positions were not stable because there was only one contact point in the right canine region, and all teeth on the left side were contacting cusp to cusp. Therefore, we used an adhesive bite-block in the posterior area to hold this new mandibular position. For an inexperienced orthodontist, if the shifted mandible is not repositioned before fixed appliance treatment, the correction of maxillary arch form compensation will be difficult and inaccurate.

3. Conclusion

Facial and dental asymmetries are a difficult problem to treat which makes a comprehensive diagnosis based on precise and detailed information. In spite of the fact that in some cases with facial asymmetry orthognathic surgery may be indicated at the beginning of treatment, for considerable improvements in facial and dental esthetics but in our case careful functional examination helped us to successfully manage the facial asymmetry with Class III malocclusion with cross bite by deprogramming the muscles. Thus, the present case report aims at addressing important aspect of functional examination to be considered by the orthodontist while reaching an accurate diagnosis and treatment plan in such patient's with challenging asymmetry.

4. Source of Funding

None.

5. Conflict of Interest

None.

References

1. Bishara SE, Burkey PS, Kharouf JG. Dental and facial asymmetry: a review. *Angle Orthod.* 1994;64(2):89-98.
2. Peck S, Peck L, Kataja M. Skeletal asymmetry in esthetically pleasing faces. *Angle Orthod.* 1991;61(1):43-8.
3. Menlik AK. A cephalometric study of mandibular asymmetry in a longitudinally followed sample of growing children. *Am J Orthod Dentofac Orthop.* 1992;101(4):355-66.
4. Wood DP, Elliott RW. Reproducibility of the centric relation bites registration technique. *Angle Orthod.* 1994;64(3):211-20.
5. Bryndahl F, Eriksson L. Functions and dysfunctions of the masticator organ. Diagnosis and therapy. Vienna, Austria; 1990.
6. McKee JR. Comparing condylar positions achieved through bimanual manipulation to condylar positions achieved through masticatory muscle contraction against an anterior deprogrammer: A pilot study. *J Prosthet Dent.* 2005;94(4):389-93.
7. McLaughlin RP. Malocclusion and the temporomandibular joint- a historical perspective. *Angle Orthod.* 1988;58(2):185-91.
8. Kusayama M, Motohashi N, Kuroda T. Relationship between transverse dental anomalies and skeletal asymmetry. *Am J Orthod Dentofacial Orthop.* 2003;123(3):329-37.

Author biography

Abhinav Bhardwaj, PG Student

Anil Miglani, Professor & Head

Monika Gupta, PG Student

Cite this article: Bhardwaj A, Miglani A, Gupta M. Decoding the facial asymmetry. *J Dent Spec* 2020;8(1):13-17.