

Creating smiles- the holistic way!! – orthodontic- surgical correction of bimaxillary protrusion

Ashutosh Shetty¹, Priyanka Basu², Vivek Bhaskar³, U.S. Krishna Nayak⁴

ABSTRACT

¹Professor,

²Ex Post Graduate Student,

³Post Graduate Student,

⁴Principal and Dean, Head of

Department,

Department of Orthodontics and

Dentofacial Orthopaedics,

A.B. Shetty Memorial Institute of

Dental Sciences,

Mangalore

Often many patients cannot be treated by orthodontics alone, and need the combined efforts of orthodontics and orthognathic surgery. Such patients are treated in three phases- a phase of pre surgical orthodontics that involves basically decompensating the dentition, followed by the surgery, which is then finished with final detailing of the occlusion. This article is a case report of a skeletal bimaxillary protrusion patient, who was treated with bi- jaw surgery.

Keywords: Surgical Orthodontics, Bimaxillary protrusion, Bijaw surgery, Prosthetic rehabilitation.

Address for Correspondence:

Dr. Vivek Bhaskar

Post Graduate Student, Department of

Orthodontics and

Dentofacial Orthopaedics, A.B. Shetty

Memorial Institute of Dental Sciences,

Mangalore

Email: vivek.libra@gmail.com

Received: 24-10-2014

Accepted: 26-03-2015

INTRODUCTION

It has been estimated that the want towards facial normalcy is one of the main reasons patients ask for orthodontic treatment, which causes profound psycho social effects.¹ But often, it is found that just orthodontic treatment does not suffice to reach the optimum soft tissue goals for a patient, and that the aid of orthognathic surgery has to be taken. The dentition has been shown to compensate, so to speak, for the underlying skeletal malformation, which has to be decompensated before any sort of surgical alteration can be thought of following adequate decompensation, surgery is carried out, following which final finishing and detailing of the occlusion is done.²

Also, as in this case, many cases present to the orthodontist with compromised dentition, and appropriate prosthetic replacement has to be planned beforehand, keeping in mind the molar and canine relations, and ideal smile esthetics.³

CASE REPORT

A 22 year old male patient reported to us with a chief

complaint of forwardly placed upper front teeth. He had no significant medical history. He gave a history of extraction of a carious upper left pre molar.

On extra oral examination, he was seen to be brachycephalic, leptoprosopic with a convex profile, consciously competent lips, and a vertical growth pattern. (Fig 1 to 3)

On intra oral examination, he presented with a Class I canine and molar relationship bilaterally, missing 24, anterior open bite of 6mm and an overjet of 7mm. (Fig 4 to 8)

The pre- treatment lateral cephalogram (Fig 9) revealed a reduced nasolabial angle, retrognathic mandible, proclined upper and lower anteriors, and a vertical growth pattern (Table 1)

Using the above diagnostic information, the diagnosis was arrived to be Class II skeletal base with vertical growth pattern, anterior open bite with proclination, and protrusive lips.

The treatment plan was decided to be a non-extraction orthodontic- orthognathic surgical one. This included:

Pre surgical orthodontics:

- Non extraction Leveling and aligning

Surgical Plan:

- LeFort I Osteotomy with differential impaction.
- Mandibular advancement rotation (anticlockwise).
- Advancement genioplasty.

Access this article online	
Quick Response Code:	Website: www.its-jds.in
	DOI: 10.5958/2393-9834.2015.00018.2

Post Surgical Orthodontics

- Settling of occlusion

The presurgical phase started with bonding of MBT 0.022” prescription brackets. Initial levelling and aligning was achieved with sequential Ni Ti wires, till the final working wire of 19x 25 S.S was in place. This phase lasted for 8 months, following which the patient was posted for surgery. (Fig 10,11,12)

The surgeries done were LeFort I Osteotomy with differential impaction, Mandibular advancement rotation (anticlockwise) and Advancement genioplasty. The surgical phase involved overcorrection of the malocclusion into a class III pattern. Due to the mandibular anti clockwise rotation there was an apparent uprightening of the lower incisors. Also in case of maxilla due to differential impaction there was a decrease in SNA angle and an apparent increase in the maxillary anterior proclination. Following surgery, the patient was put on intermaxillary fixation for a period of 2 weeks. After this, settling elastics were prescribed for a month. Post debond, the patient was referred to the Department of Prosthodontics for replacement of the missing 24. The patient was put on clear thermoformed retainers immediately after debond, as well as, a new set after the prosthesis delivery, for a period of 12 months.

The entire treatment from pre surgical orthodontics to post debond prosthetic replacement lasted for a period of 17 months. The self- confidence and self-perception of the patient improved considerably, and the decided treatment plan resulted in satisfactory facial balance and esthetics, coupled with excellent occlusion. (Fig 13 to 20)

The post treatment cephalogram (Fig 21) (Table 1) showed drastic changes in the maxillary prognathism, lip balance, and incisor proclination, indicative of a successful treatment.

Table: 1

Cephalometric Values	Pre Treatment	Post Debond
SNA	83°	76°
SNB	76°	79°
WITS	5mm	2.5mm
N-A-Pg	16°	-9°
Upper Incisor to NA	23° / 6mm	36°/17mm
Lower Incisor to NB	45° / 19mm	38° / 15mm
Lower incisor to Mand. plane	110°	90°
Inter-incisal Angle	105°	109°
Nasolabial Angle	97°	105°
Upper lip to E line	6mm	-3mm
Lower lip to E line	12mm	-2mm
Upper lip to S line	9mm	1mm
Lower lip to Sline	15mm	3mm

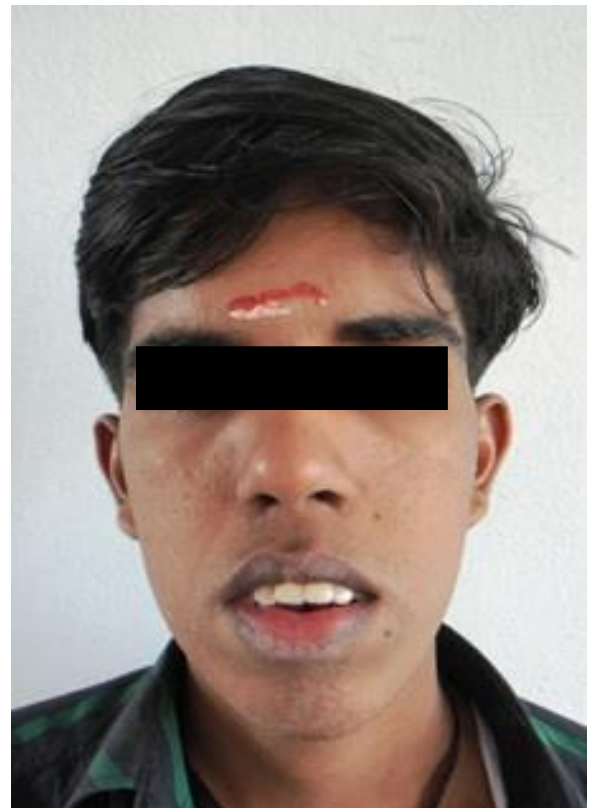

Fig. 1: Pre Treatment Extra Oral Images

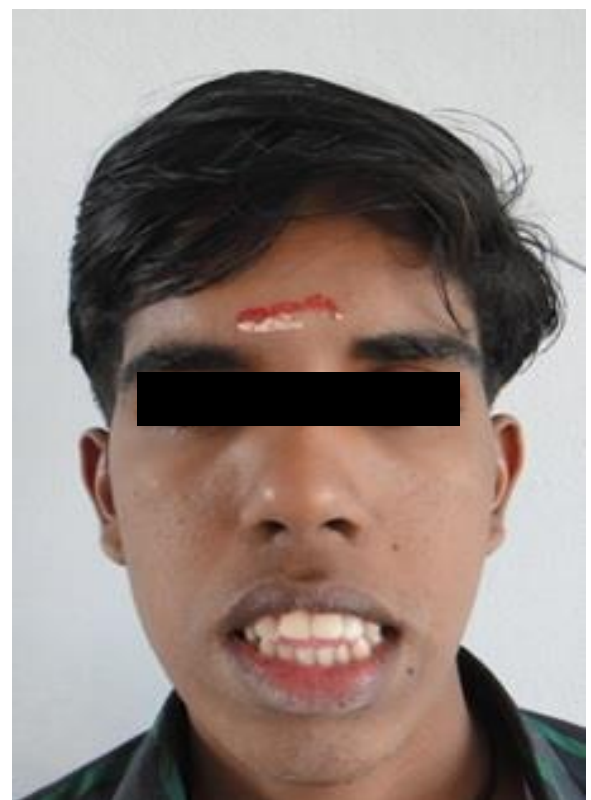

Fig. 2: Pre Treatment Extra Oral Images

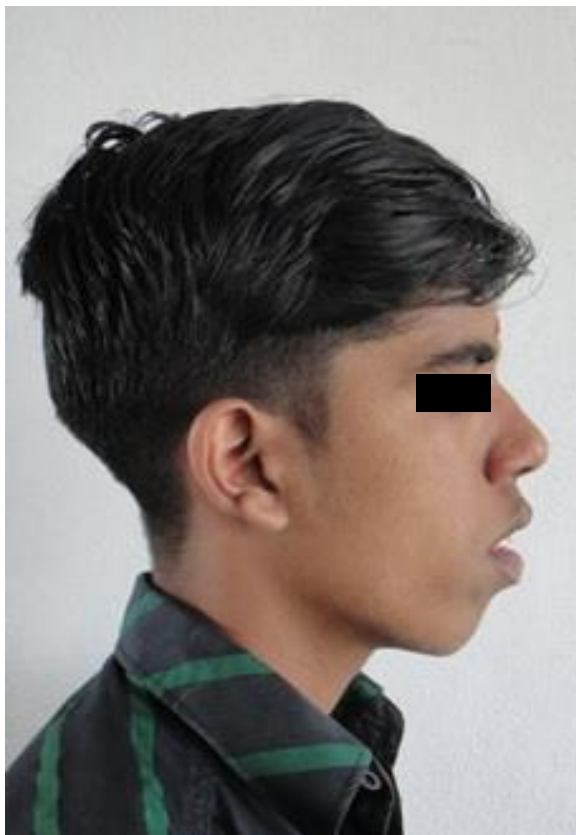

Fig. 3: Pre Treatment Extra Oral Images

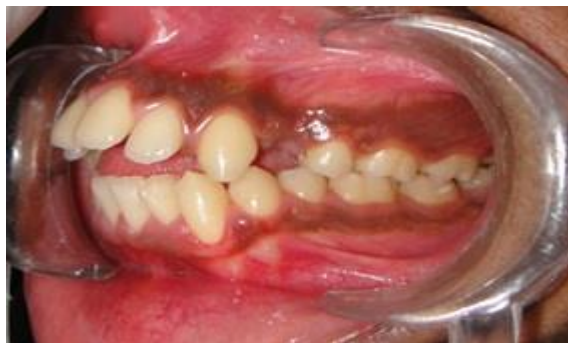

Fig. 6: Pre Treatment Intra Oral Images

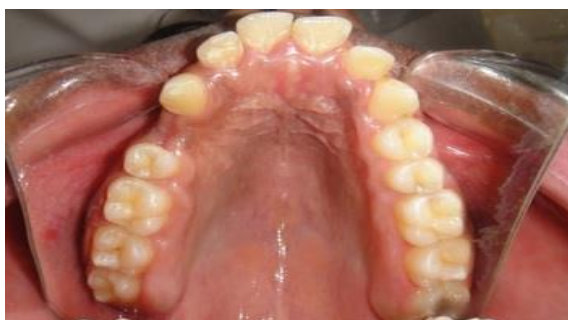

Fig. 7: Pre Treatment Intra Oral Images

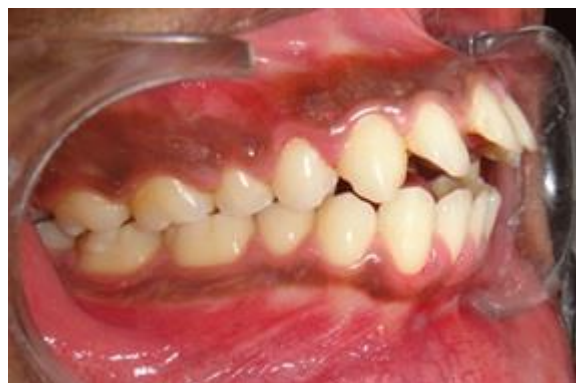

Fig. 4: Pre Treatment Intra Oral Images

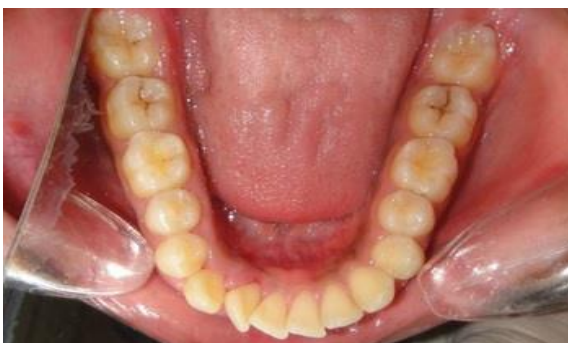

Fig. 8: Pre Treatment Intra Oral Images

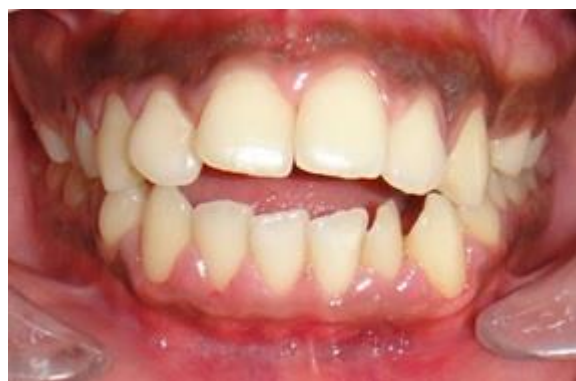

Fig. 5: Pre Treatment Intra Oral Images

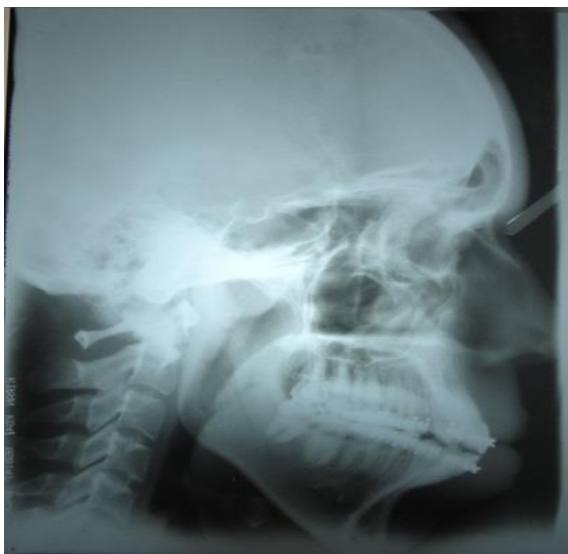

Fig. 9: Pre Treatment Lateral Cephalogram

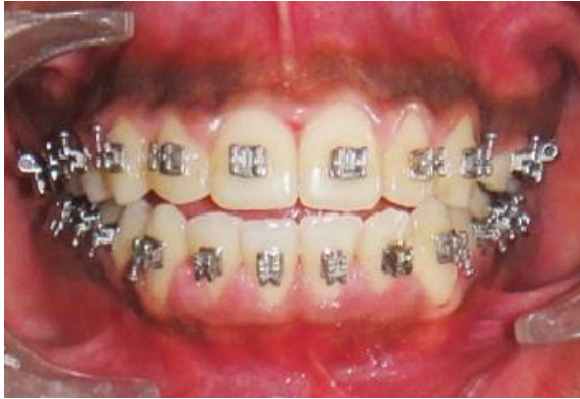

Fig. 10: Pre Surgical Images

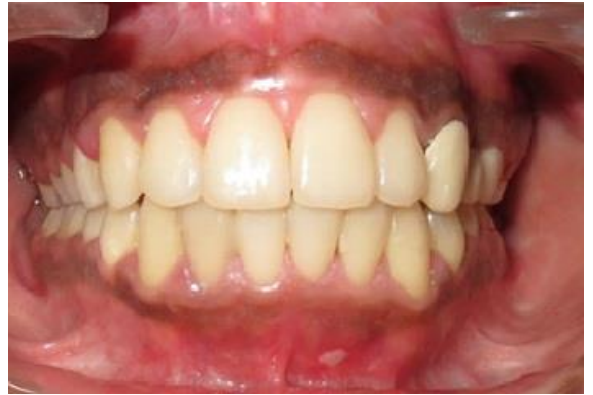

Fig. 14: Post Treatment Intra Oral Images

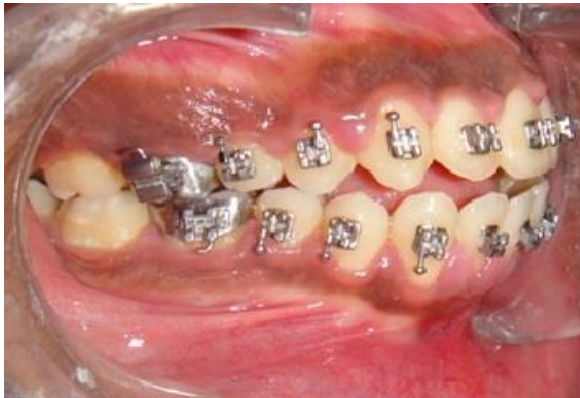

Fig. 11: Pre Surgical Images

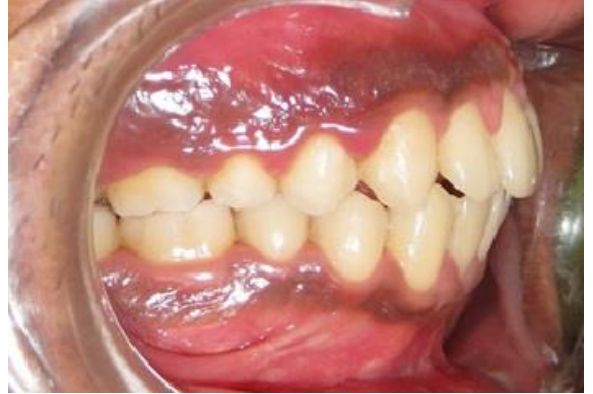

Fig. 15: Post Treatment Intra Oral Images

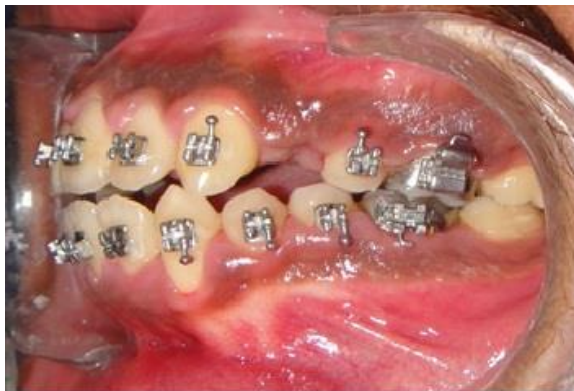

Fig. 12: Pre Surgical Images

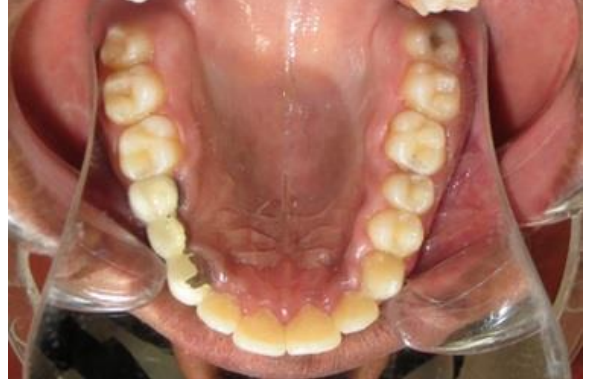

Fig. 16: Post Treatment Intra Oral Images

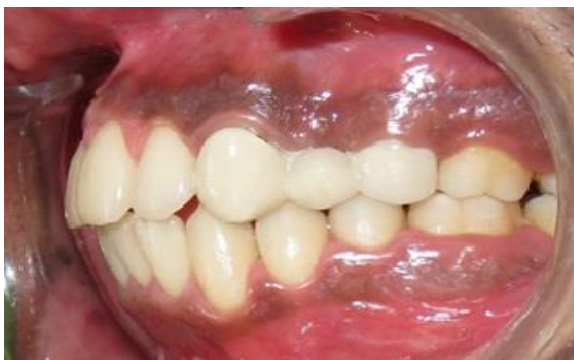

Fig. 13: Post Treatment Intra Oral Images

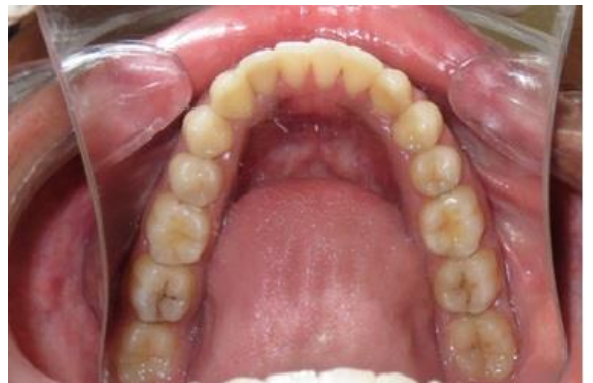

Fig. 17: Post Treatment Intra Oral Images

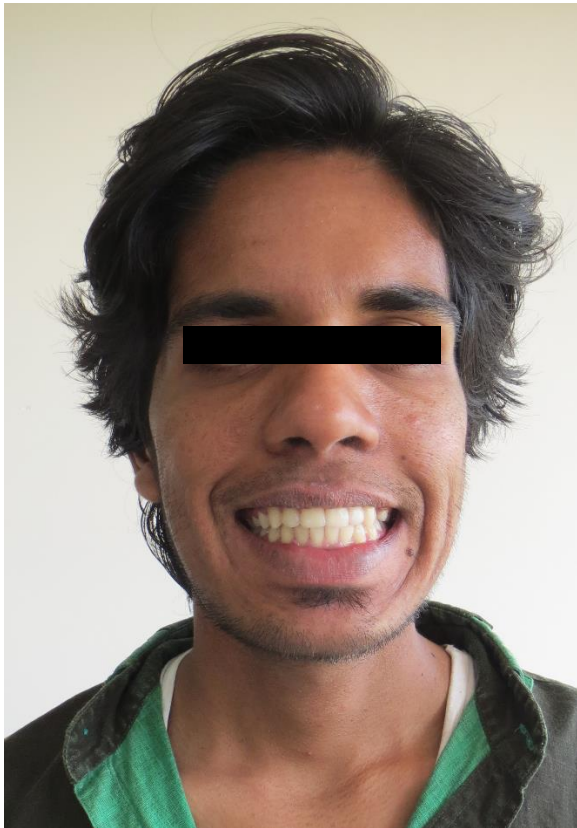


Fig. 19: Post Treatment Extra Oral Images

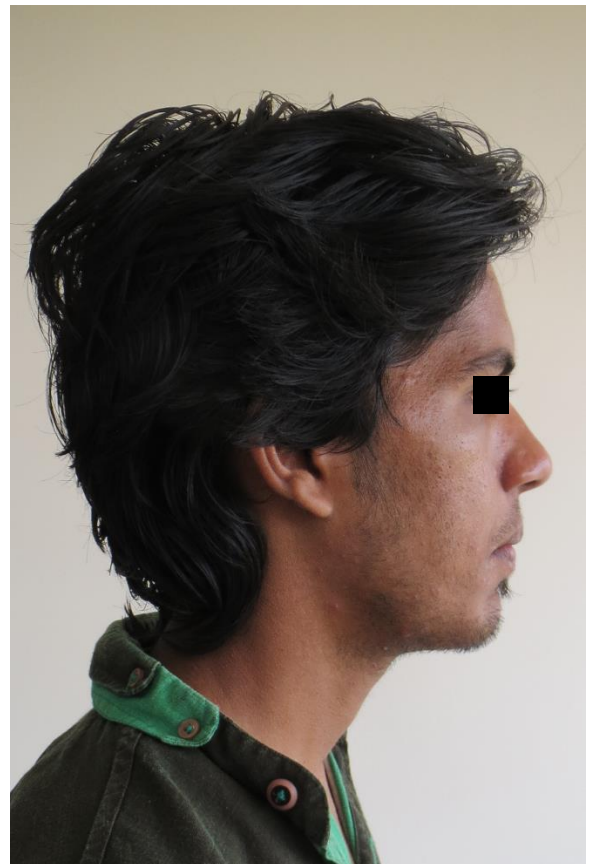

Fig. 21: Post Treatment Extra Oral Images



Fig. 20: Post Treatment Extra Oral Images

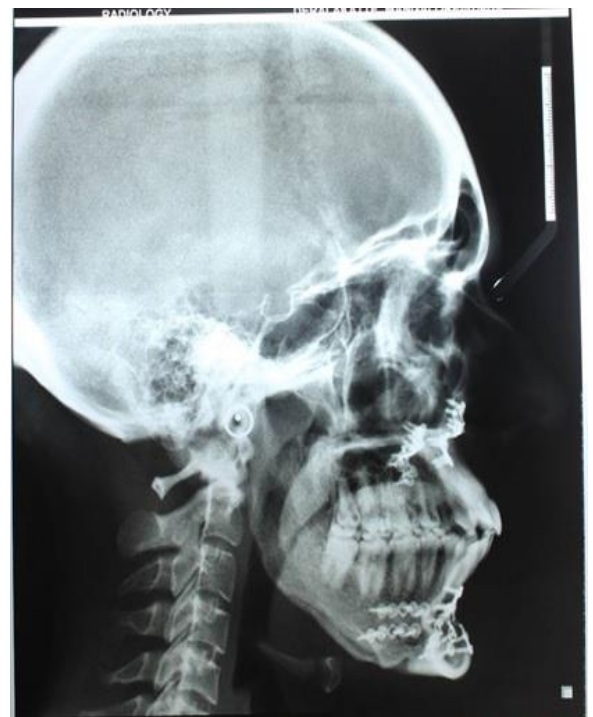

Fig. 22: Post Treatment Cephalogram

DISCUSSION

Taking into consideration the cephalometric variables, coupled with the clinical examination, it was clearly evident that the patient needed a surgical intervention to address his chief complaint. This particular patient was ready for surgery, but if not for surgery camouflage alternatives would have to be considering it as a bimaxillary protrusion case and treat with extraction of pre molars and intrusion of the maxillary posteriors, with accompanying auto rotation of the mandible. However, this would lead to compromised esthetics, and highly prone to relapse.^{4,5} As far as retention protocol was concerned, we felt that the best method would be one that covers the entire dentition, giving retention to all the teeth, and hence we gave the patient clear thermoformed retainers.⁶

CONCLUSION

In this case, i.e a bimaxillary protrusion, adequate non extraction pre surgical orthodontics, followed by bijaw surgery gave satisfactory results.

The change in the patient's self-esteem and self-image drastically improved, indicating the psychosocial impact of Orthodontic- Orthognathic Surgery.

REFERENCES

1. D Roberts-Harry, J Sandy. Orthodontics. Part 1: Who needs orthodontics? British Dental Journal 2003;195, 433.
2. Anwar N, Fida M. Evaluation of dentoalveolar compensation in skeletal class II malocclusion in a Pakistani University Hospital setting. J Coll Physicians Surg Pak. 2009;19:11-6
3. K. S. Senthil Kumar, Deepika, Triveni, P. Jayakumar. Management of a vertical maxillary excess in an adult patient by combined orthodontics and orthognathic surgery- a case report. J Ind Orthod Soc 2007;41:7-16.
4. Yuh-Jia Hsieh, Ellen Wen-Ching Ko, Yu-Fang Liao, Chung-Shing Huang. Correction of Severe Class II Division 1 malocclusion with Miniscrew Anchorage- A case report. J. Taiwan Assoc. Orthod. 2013;25:31-45.
5. Makoto Nishimura, Minayo Sannohe, Hiroshi Nagasaka, Kaoru Igarashi, Junji Sugawara. Extraction treatment with temporary skeletal anchorage devices to correct a Class II Division 2 malocclusion with excessive gingival display. American Journal of Orthodontics and Dentofacial Orthopedics. 2014; Volume 145, Issue 1, Pages 85-94.
6. GiampetroFarronato et al. Post-Surgical Orthodontic Treatment Planning: A case report with 20 year follow up. J Oral Maxillofac Res. 2011;2: e4.

How to cite this article: Shetty A, Basu P, Bhaskar B, Nayak USK. Creating smiles- the holistic way!! – orthodontic surgical correction of bimaxillary protrusion. J Dent Specialities, 2015;3(2):211-216.

Source of Support: NIL

Conflict of Interest: All authors report no conflict of interest related to this study.