

Odontogenic keratocyst of the angle and ramus of the mandible - a case report

Shaveta Garg¹, M.K Sunil², Ashwarya Trivedi³, Neetu Singla⁴

ABSTRACT

¹PG student,

²Prof. & Head,

³Reader,

⁴Sr. Lecturer,

Dept of Oral Medicine and Radiology
Guru Nanak Dev Dental College and
Research Institute, Sunam (Punjab)

Address for Correspondence:

Dr. Shaveta Garg

PG student, Dept. of Oral Medicine
and Radiology, Guru Nanak Dev
Dental College and Research Institute,
Sunam (Punjab)

Email: garg_shaveta33@yahoo.com

Received: 17/02/2015

Accepted: 05/06/2015

The Odontogenic Keratocyst (OKC), first described by Phillipson in 1956, has been reclassified as odontogenic neoplasm and has been renamed as Keratocystic Odontogenic Tumor (KCOT) as reported in WHO classification of head and neck tumors in 2005. Odontogenic keratocysts are benign intraosseous tumors of odontogenic origin that occur most commonly in the jaw. In particular, they have a predilection for the angle and ascending ramus of the mandible. The recurrent rate of odontogenic keratocyst is 25 – 30 percent. A case of odontogenic keratocyst in 60 years old patient is presented involving mandibular third molar ramus area which was recurred after 3 years.

Keywords: Keratocyst, Odontogenic, Molar, Ramus

INTRODUCTION

Tooth development involves complicated, multistep interactions between the oral epithelium and the underlying mesenchymal tissue. Ectopic teeth can arise when these tissue interactions during development are affected by developmental disturbances, iatrogenic activity, or pathological conditions, such as the presence of a tumor or a cyst.¹ Odontogenic keratocysts (OKC) have high recurrence rates, mitotic counts and epithelial turnover rates, and are the most aggressive of the odontogenic cysts in the oral cavity. In addition, unlike most cysts, usually thought to grow solely due to osmotic pressure, the epithelium in the OKC appears to have innate growth potential, which is consistent with a benign tumor.² Given these features, not observed in common cysts, such as radicular and dentigerous cysts, the World Health Organization reclassified OKC as a keratocystic odontogenic tumor (KCOT) in 2005. We chose the term OKC instead of KCOT in this report, because most of references yet contain the former term.¹

The clinical and radiographic features of OKC are unspecific: while some may be associated with pain, swelling, or drainage, most are asymptomatic, and radiography reveals a well-defined radiolucent area, which is also characteristic of dentigerous cysts,

radicular cysts, or residual cysts. Thus, while the clinical and radiographic features can often be highly suggestive, they are not diagnostic. This means that OKC is often misdiagnosed as an ordinary cyst and is therefore undertreated, resulting in unnecessary recurrences.^{2,3}

CASE REPORT

A 60 year old female patient reported to the department with chief complaint of swelling in the left lower back teeth region since 15 days. History of present illness revealed that the swelling was initially smaller in size but it gradually increased to present size. There was also the history of swelling in the same teeth region 3 years back for which she got surgery done with eventful extraction of teeth in left lower back teeth region. Now patient again noticed swelling 15 days back. There was no history of any trauma or any discharge. No history of any difficulty in chewing the food. Past medical history revealed that there was no systemic illness present. Personal history revealed that patient was vegetarian in diet and there was no history of any deleterious habit like smoking, tobacco or betel nut chewing, alcohol etc. Extraoral examination revealed that there was a diffuse swelling on left lower side of face i.e approx. 2.5 X 3 cm in size extended anteriorly from line joining left commissure of lip upto angle of mandible posteriorly. Superiorly it extended from ala tragus line inferiorly upto lower border of mandible. The colour of swelling was same as that of surrounding skin. On palpation it was soft to firm in consistency, non-tender, non-compressible, non-fluctuant and afebrile to touch. (Fig.1)

Access this article online

Quick Response Code:



Website:
www.its-jds.in

DOI:
10.5958/2393-9834.2015.00020.0

Intraoral examination revealed that there was obliteration of buccal vestibule wrt 35, 36 teeth region. Overlying surface was of same colour as that of surrounding mucosa. On palpation it was soft to firm in consistency, non-tender and no discharge was present (Fig. 2). Teeth were missing wrt 16,27,33,34,35,36,46 and generalized calculus & stains were present. On aspiration straw coloured fluid was present.

With the above clinical findings, provisional diagnosis of generalized chronic periodontitis and odontogenic keratocyst wrt 35, 36 was given with differential diagnosis of unicystic ameloblastoma.

Intraoral periapical radiograph (IOPA) was taken, which showed a radiolucency wrt 35, 36, 37 teeth region that extends anteriorly from 35 tooth region posteriorly upto mesial aspect of 37 tooth region. Superiorly it extends from alveolar ridge corresponding to 35, 36 teeth region and inferior limits are not appreciated (Fig. 3). Mandibular occlusal topographic radiograph was taken which revealed normal anatomic landmarks and missing teeth wrt 33, 34, 35, 36 (Fig. 4). OPG was taken which showed a well-defined radiolucency was present wrt left lower molar – ramus area which was oval in shape with well-defined corticated borders on its anterior aspect, superior aspect, inferior aspect and no posterior aspect not well appreciated. Internal septae was present giving it a multilocular appearance (Fig. 5) Radiographic diagnosis of odontogenic keratocyst was given with differential diagnosis of unicystic ameloblastoma, odontogenic myxoma, simple bone cyst.

After taking the informed consent of the patient marsupialization was done under local anesthesia. Histopathological specimen revealed 8-10 cell thick parakeratinized stratified squamous epithelium lining a thin fibrous connective tissue wall. The epithelial- connective tissue interface was flat. The luminal surface showed flattened parakeratotic epithelium which exhibited a corrugated appearance. The basal layer was composed of palisaded layer of cuboidal cells with hyperchromatic nucleus. At places the cyst epithelium was detached from underlying fibrous connective tissue wall (Fig. 6)

The overall features were suggestive of odontogenic keratocyst. So final diagnosis of odontogenic keratocyst wrt left lower molar – ramus area was given. The patient was followed up after one month and the healing was found to be satisfactory with no tendency for recurrence.

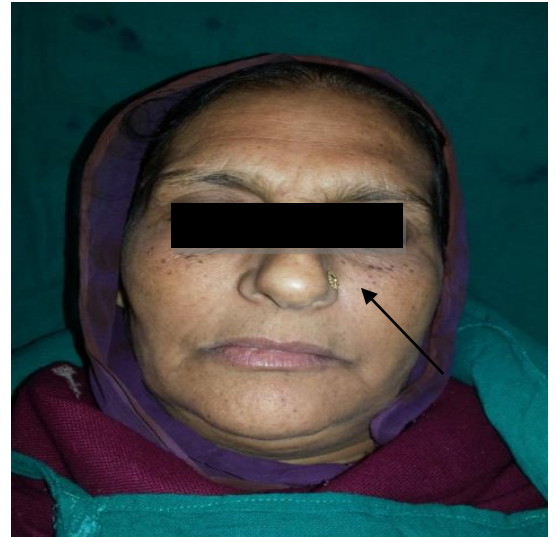

Fig. 1: Extraoral picture showing swelling on left lower side of face

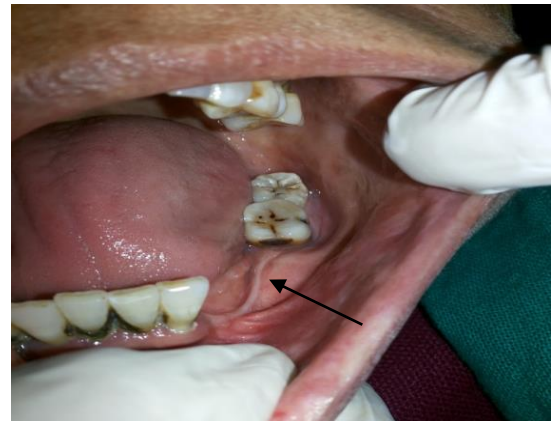

Fig. 2: Intraoral picture showing obliteration of vestibule wrt 35, 36 region

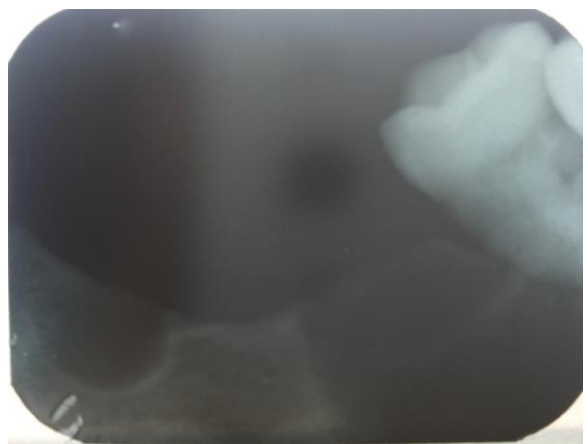


Fig. 3: IOPA wrt 35, 36, 37 which showed a radiolucency that extends anteriorly from 35 tooth region posteriorly upto mesial aspect of 37 tooth region

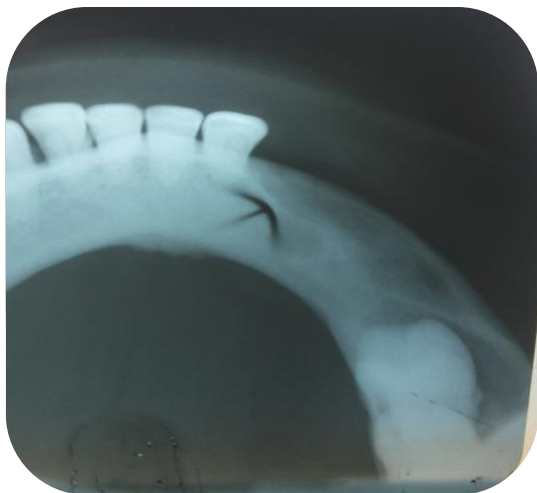


Fig. 4: Mandibular occlusal topographic radiograph which revealed normal anatomic landmarks and missing teeth 33,34,35,36

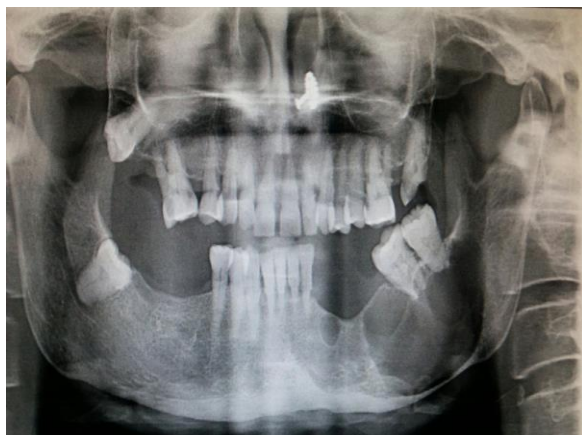

Fig. 5: OPG which showed a well-defined radiolucency was present wrt left lower molar – ramus area which was oval in shape with well-defined corticated borders and internal septae was present giving it a multilocular appearance

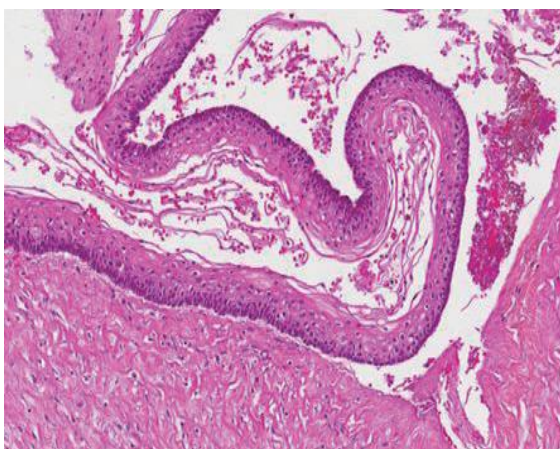


Fig. 6: Histopathological picture showing epithelial lining has a hyperchromatic and palisaded basal cell layer, is 8 to 10 cells thick, has a corrugated parakeratotic surface, and is detached from the connective tissues.

DISCUSSION

The odontogenic keratocyst (OKC) is a well-known pathologic lesion of the jaws derived from rests of the dental lamina. It represents approximately 10 percent of all jaw cysts and may occur in a wide age range of patients. About 70 percent or more cases involve the mandible, especially in the molar, angle and ramus regions.² The present case also involve mandibular molar - ramus area.

Symptoms such as pain, swelling and drainage may be present, especially with larger lesions. However, at least half of all lesions are discovered as incidental radiographic findings. Due to the propensity of OKCs to grow within the medullary bone, they have the potential to become extremely large without causing any clinical signs or symptoms.^{3,4} In the present case there was no pain and discharge was present.

Radiographically, the OKC presents as a well-defined radiolucency with thin corticated margins. The majority of these are unilocular, but larger lesions may be multilocular. Approximately 20-40 percent of OKCs are associated with an unerupted tooth and can be identical in appearance to a dentigerous cyst. Root resorption is relatively uncommon.⁵ The present case showed a well-defined radiolucency with thin corticated margins and internal septae was present giving it a multilocular appearance.

The histopathologic findings of the OKC are highly specific. Diagnostic features include a uniform cyst lining, hyperchromatic and palisaded basal cells, wavy parakeratin production and a flat interface between the epithelium and connective tissue wall which was similar in the present case. Importantly, these classic microscopic features are often completely lost when the cyst is inflamed, presenting an obvious diagnostic challenge which can lead to an incorrect diagnosis.⁶

If multiple OKCs are present in a patient, a diagnosis of nevoid basal cell carcinoma syndrome (NBCCS or Gorlin syndrome) should be suspected. NBCCS is an inherited genetic condition caused by mutation of the PTCH1 gene.⁶ Other manifestations of the syndrome include palmar and plantar pits, bifid ribs, calcified falx cerebri and multiple basal cell carcinomas of the skin. Unlike traditional basal cell carcinomas, the lesions associated with NBCCS tend to be less aggressive, hence the designation “nevoid,” or having biologic behavior more similar to a nevus.^{6,7}

Differential diagnosis include dentigerous cyst (in odontogenic keratocyst the cyst is connected to the tooth at a point apical to cemento-enamel junction), ameloblastoma (usually multilocular, no straw coloured fluid on aspiration), traumatic cyst (unilocular with scalloped margins, rarely show cortical expansion), giant cell granuloma (usually in anterior region of jaw), odontogenic myxoma.⁵

Unlike most other odontogenic cysts, OKCs have a striking tendency for recurrence (25-30 percent), with

most recurrences developing during the first 5-7 years after therapy. Unfortunately, no practical instruments or techniques are available to surgeons to help predict which lesions will recur and which will not. The recurrence of OKC, which is usual, is thought to be based on great mitotic activity and growth potential found in epithelium, furthermore other sources of recurrences such as remnants of dental lamina and epithelial islands have also been proposed. Suspected causes of recurrence are incomplete removal of the original cyst lining, growth of a new lesion from residual epithelial islands or genotypic variations between lesions.⁸ For these reasons, the treatment of OKCs continues to be controversial. The challenge for the treating clinician is to minimize both the risk of recurrence and patient morbidity. Each case should be managed individually, considering factors such as the age and health of the patient, size of the lesion and risk of damage to adjacent structures.^{5,8}

Marsupialization and decompression are conservative therapies generally used for large lesions in order to preserve bone, teeth and other vital structures, as well as reducing the possibility of pathologic fracture. They are particularly promising treatment modalities for OKCs in children or patients who are poor surgical candidates. Both procedures rely on the principle of reducing the osmotic pressure of the cyst by exposing it to the oral cavity. This results in bone formation at the periphery of the lesion and a gradual decrease in the size of the cyst. Marsupialization is a one-step, definitive procedure in which the cyst lining is directly sutured to the surrounding oral mucosa, with eventual total resolution.^{3,5}

Decompression is a two-step procedure involving the placement of a surgical drainage tube, followed by enucleation at a later date once the cyst has shrunk to a more manageable size. Exteriorization causes the nature of the cyst lining to evolve into one that is more similar to oral surface epithelium and therefore easier to remove in one piece. Probably the greatest disadvantage to marsupialization and decompression is that they require extensive cooperation from the patient and/or family members. The area must be irrigated with saline and chlorhexidine daily, usually for several months depending on the size of the original cyst. The recurrence rate for marsupialized lesions is approximately 40 percent.^{2,5}

Enucleation is the complete and intact removal of a lesion by surgically husking it from the surrounding tissues. Clinicians often report difficulty in enucleating OKCs due to their thin, friable epithelial lining and tendency to adhere to the surrounding bone (or soft tissues in the case of cortical perforation). Application of Carnoy's solution is another type of adjunctive therapy that destroys cyst remnants by means of chemical cautery. Enucleation

combined with adjunctive treatment decreases the potential for recurrence to 18 percent or less.⁷ Resection refers to the surgical removal of a section of the involved jaw. Marginal resections leave behind a rim of uninvolved bone, while a segmental resection removes an entire portion of the jaw without maintaining continuity.^{7,8}

CONCLUSION

In conclusion, a biopsy specimen examination and accurate clinical, radiographic, trans-surgical observation along with follow up are essential to avoid recurrence.

REFERENCES

1. Madras J, Lapointe H. Keratocystic Odontogenic Tumour: Reclassification of the Odontogenic Keratocyst from Cyst to Tumour. *J Can Dent Assoc* 2008;74:165-67.
2. Manor E, Kachko L, Puterman MB, Szabo G, Bodner L. Cystic Lesions of the Jaws – A Clinicopathological Study of 322 Cases and Review of the Literature. *Int J Med Sci*. 2012;9:20-26.
3. Zecha JA, Mendes RA, Lindeboom VB, Van der wall I. Recurrence rate of keratocystic odontogenic tumor after conservative surgical treatment without adjunctive therapies- A 35-year single institution experience. *Oral Oncol* 2010;46:740-42.
4. Boffano P, Ruga E, Gallezio C. Keratocystic odontogenic tumor (odontogenic keratocyst): preliminary retrospective review of epidemiologic, clinical, and radiologic features of 261 lesions from University of Turin. *J Oral Maxillofac Surg* 2010;68:2994-99.
5. Bland PS, Shiloah J, Rosebush MS. Odontogenic Keratocyst: A Case Report and Review of an Old Lesion with New Classification. *J Tenn Dent Assoc*. 2012;92:37-38.
6. Morgan TA, Burton CC, Qian F. A retrospective review of treatment of the odontogenic keratocyst. *J Oral Maxillofac Surg* 2005;63:635-39.
7. Gomes CC, Diniz MG, Gomez RS. Review of the molecular pathogenesis of the odontogenic keratocyst. *Oral Oncol* 2009;45:1011-14.
8. Almeida P Jr, Cardoso Lde C, Garcia IR Jr, Magro-Filho O, Luvizuto ER, Felipini RC. Conservative approach to the treatment of keratocystic odontogenic tumor. *J Dent Child (Chic)* 2010;77:135-39.

How to cite this article: Garg S, Sunil MK, Trivedi A, Singla N. Odontogenic keratocyst – a case report. *J Dent Specialities*, 2015;3(2):195-198.

Source of Support: NIL

Conflict of Interest: All authors report no conflict of interest related to this study.