

## Incidental finding of dentigerous cyst - a case report

Pulivarthi Sushma<sup>1</sup>, Sowbhagya M.B<sup>2</sup>, Balaji P<sup>3</sup>, Mahesh Kumar T.S<sup>4</sup>

### ABSTRACT

<sup>1</sup>Post Graduate Student, <sup>2</sup>Reader, <sup>3</sup>Head and prof, <sup>4</sup>Senior lecturer, Department of Oral Medicine and Radiology, Rajarajeswari Dental College and Hospital, Bangalore, Karnataka, India.

#### Address for Correspondence:

Dr. Pulivarthi Sushma  
Post Graduate Student  
Department of Oral Medicine and Radiology, Rajarajeswari Dental College and Hospital, Bangalore, Karnataka, India  
Email:

Received: 19/01/2015

Accepted: 20/05/2015

In the jaws, the most common type of developmental odontogenic cyst is dentigerous cyst, mostly affecting the impacted mandibular third molars and permanent maxillary canines. They are often noted as an incidental finding on radiographs as unilocular radiolucency with well-defined sclerotic border which encircles the crown of an unerupted tooth as most of these dentigerous cysts are clinically asymptomatic. Long standing cases of dentigerous cysts can progress to either ameloblastoma or squamous cell carcinoma or mucoepidermoid carcinoma. Henceforth, an early clinical and radiographic detection of the cyst plays a vital role so that apt treatment modalities can be carried out which will prevent or decrease the morbidity. With this above background, we hereby report an enticing case of dentigerous cyst which was incidentally observed in conventional radiographs and to evaluate further extension and nature of lesion, a conebeam computed tomography (CBCT) of jaw was taken.

**Key words:** Dentigerous cyst, Impacted mandibular third molars, Incidental finding, Cone beam computed tomography

### INTRODUCTION

In the jaws, the most common type of developmental odontogenic cyst is dentigerous cyst and it encompasses for about 20-24% of all epithelium-lined cysts of the jaws.<sup>1,2,3</sup> In the general population their incidence has been estimated at 1.44 cysts for every 100 unerupted teeth.<sup>4</sup> Dentigerous cysts occur in a wide range of age group with a peak frequency of 2nd to 4th decades of life.<sup>5</sup> The exact etiopathogenesis dentigerous cysts remain unknown, but most of the authors suggest a developmental origin from the tooth follicle.<sup>6</sup> They are often noted as an incidental finding on radiographs as unilocular radiolucency with well-defined sclerotic border which encircles the crown of an unerupted tooth as most of the dentigerous cysts are clinically asymptomatic. Diagnosis of a dentigerous cyst is straight forward in majority of the cases, but radiographically a 'typical' dentigerous cyst should be differentiated from a keratocystic odontogenic tumour (KCOT) [an odontogenic keratocyst] and unicystic ameloblastoma.<sup>7</sup> Dentigerous cysts over a period of time can progress to ameloblastoma or squamous cell carcinoma or mucoepidermoid carcinoma.<sup>8,9,10,11</sup> Therefore, an early clinical and radiographic recognition of the cyst plays a vital role

so that apt treatment modalities can be carried out which will prevent or decrease the morbidity.

### CASE REPORT

A middle aged female patient (30 years) reported with a chief complaint of pain in the lower front tooth region since one month to the department of oral medicine and radiology. Pain was insidious in onset, mild, intermittent and dull aching type. On examination all vital signs were within normal limits and no gross asymmetry of the face was noted. On intraoral examination gingival recession; gingival bleeding on probing and periodontal pocket was present in relation to 31 and 41 and hard tissue examination revealed no abnormality. Based on history and clinical findings a working diagnosis of chronic generalized gingivitis with localized periodontitis in relation to 31, 41 was made and subsequently patient was subjected to routine radiographic investigations.

Intraoral periapical radiograph revealed alveolar crestal bone loss in relation to 31 and 41. Digital panoramic radiograph revealed presence of well-defined radiolucency with sclerotic border surrounding crown of the unerupted tooth in relation to 38 at cemento-enamel junction level. The radiolucency appeared oval in shape extending antero-posteriorly from distal root of 36 to the crown of 38 and supero-inferiorly extending from 5mm below the alveolar crest in relation to 37 till lower border of mandible. Based on these imaging findings, a radiographic diagnosis of dentigerous cyst in relation to 38 was given and differential diagnosis of unicystic ameloblastoma and keratocystic odontogenic tumor were considered.

Access this article online	
Quick Response Code:	Website: <a href="http://www.its-jds.in">www.its-jds.in</a>
	DOI: 10.5958/2393-9834.2015.00012.1

Based on radiographic diagnosis which was obtained through preliminary radiological examination patient was subjected to CBCT of jaw to evaluate further extension and nature of lesion of mandibular left third molar region. Additional finding revealed lingual expansion with severe thinning and perforation of the lingual cortical plate. The buccal cortex appeared intact with mild expansion. The mandibular canal outlines were lost along the lesion with the canal displaced inferiorly along the mandibular base. No evidence of root resorption was noted in relation to distal root tip of 36 and the roots of 37 appeared within the lesion. The CBCT findings were suggestive of a dentigerous cyst in relation to 38. All the parameters were within normal limits on routine hematological investigations. After obtaining patient's consent the cyst was treated by surgical enucleation along with the removal of impacted tooth under local anesthesia and specimen was subjected to histopathological examination. H & E section revealed a dense connective tissue stroma with proliferating fibroblasts, numerous blood vessels lined by endothelial cells and few inflammatory cell infiltrate. We arrived at final diagnosis of dentigerous cyst with all the radiographic and histopathological findings.

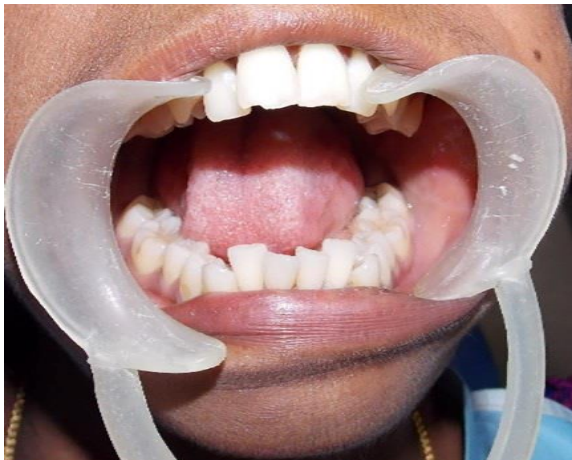

Fig 1: Intraoral view

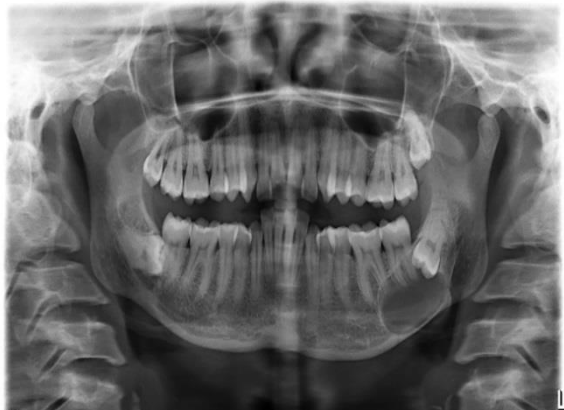

Fig. 2: Orthopantomogram (Pre-operative)

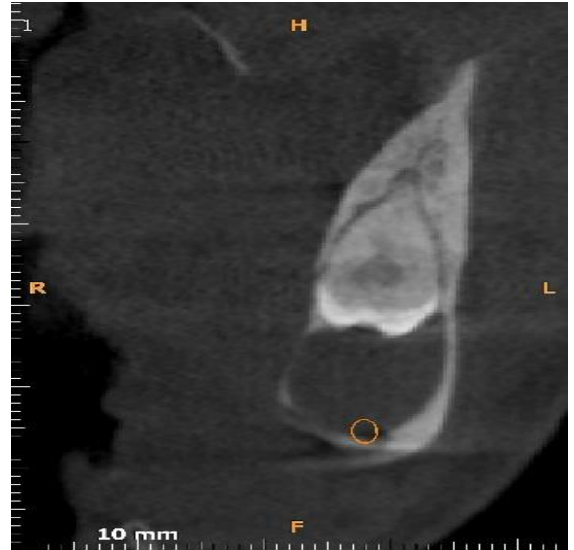

Fig. 3(a);

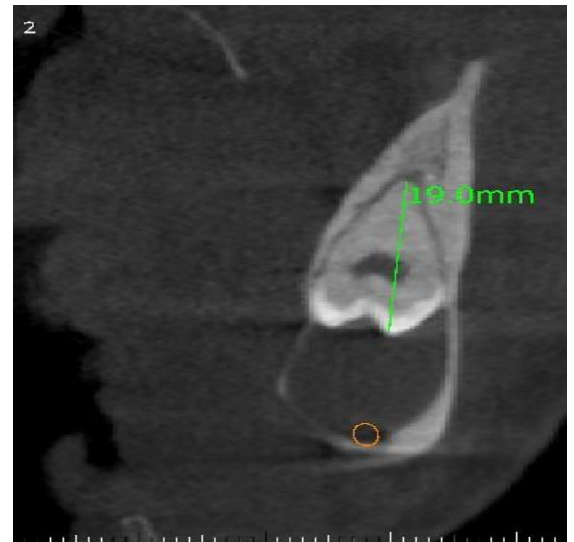


Fig. 3(b);

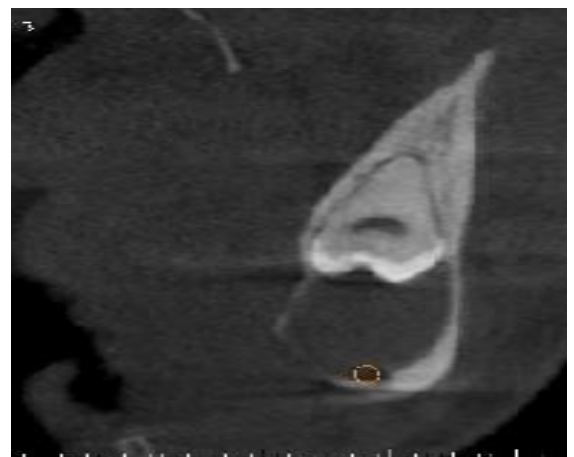


Fig. 3(c)

Fig. 3(a); 3(B); 3(C): CBCT- Cross Section along the Long Axis of 38 – Fused and Conical Root

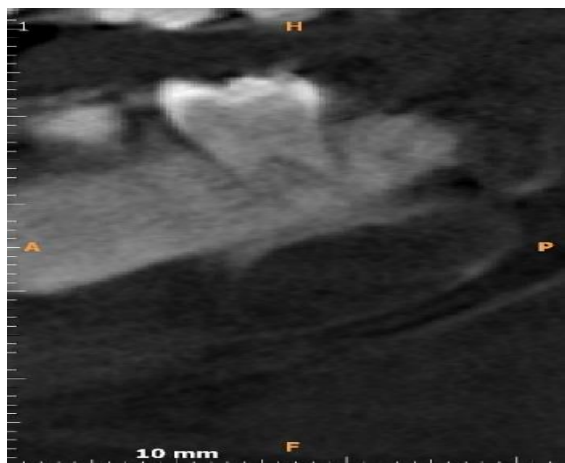

Fig. 4(a)

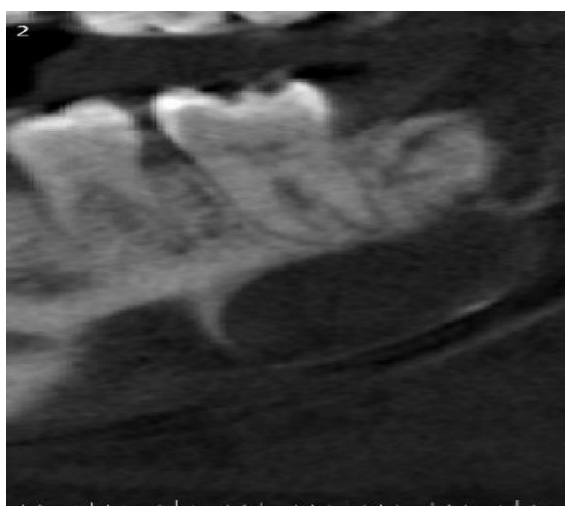


Fig. 4(b)

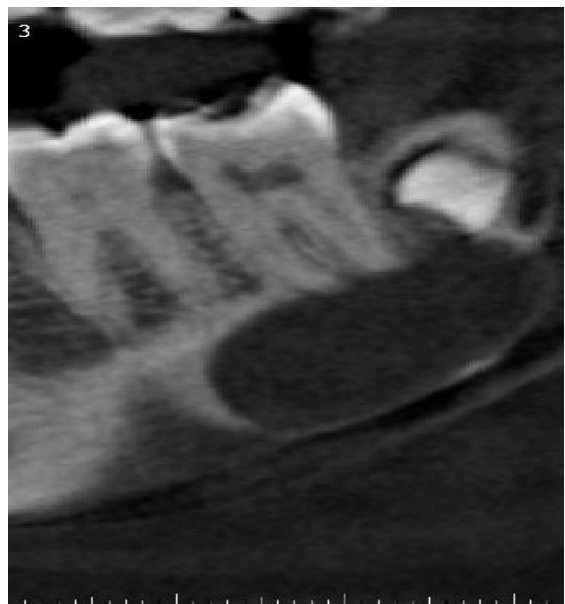

Fig. 4(c)

Fig 4(a); 4(b); 4(c): CBCT- Sections along 36, 37 Reveal Intact Root with No Evidence of Resorption

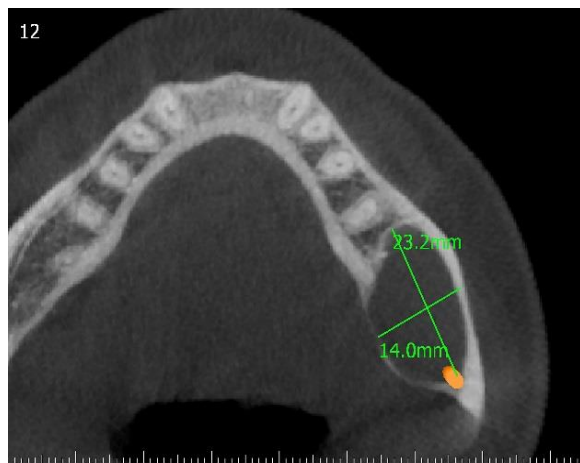


Fig. 5: CBCT- Axial Section

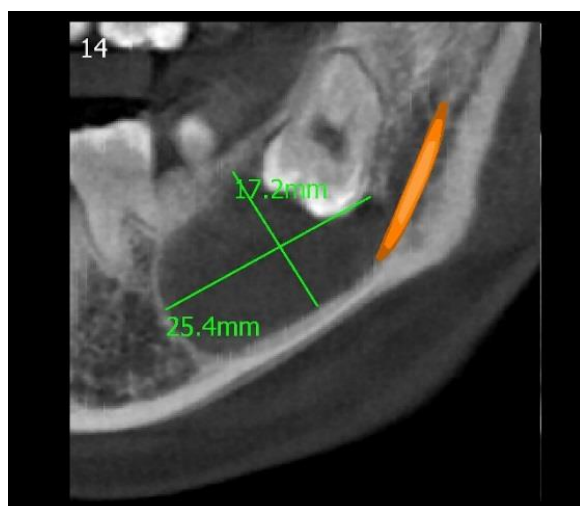


Fig. 6: CBCT- Bucco-Lingual Section

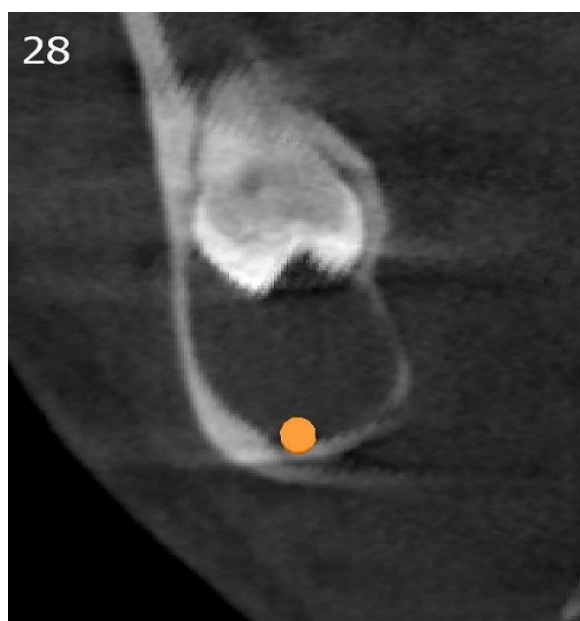
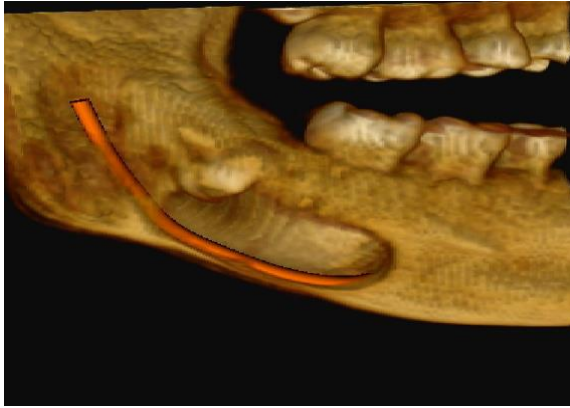
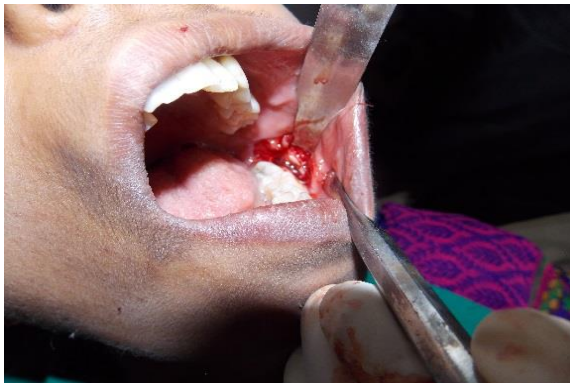

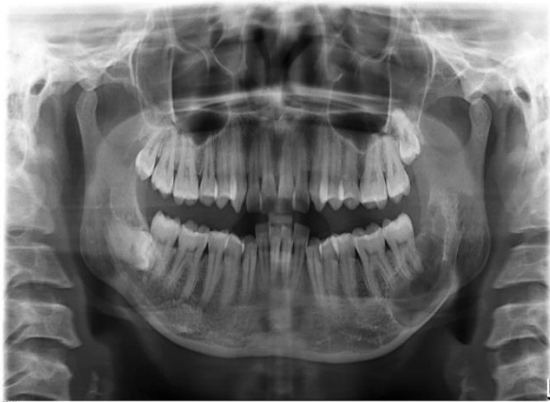Fig. 7: CBCT- Cross Section of 38



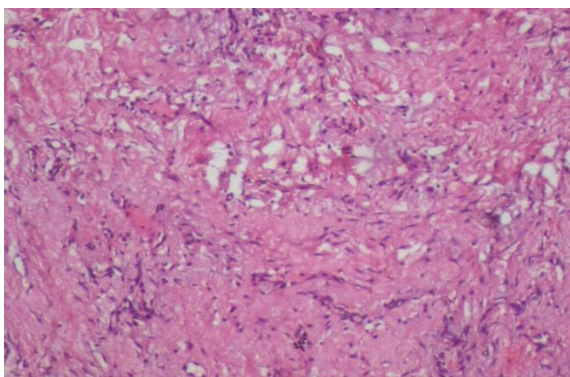
**Fig. 8: CBCT- 3 D reconstruction**



**Fig. 9: Surgical enucleation**



**Fig. 10: Orthopantomogram (Post-operative)**



**Fig. 11: Photomicrograph 4X**

## DISCUSSION

In the jaws, the most common type of developmental odontogenic cyst is dentigerous cyst and it encompasses for about 20-24% of all epithelium-lined cysts of the jaws.<sup>1,2,3</sup> Worldwide, incidence has been estimated at 1.44 cysts for every 100 unerupted teeth.<sup>4</sup> The exact etiopathogenesis of dentigerous cysts remain unknown, but most of the authors suggest a developmental origin from the tooth follicle<sup>6</sup>. The development of dentigerous cyst is due to fluid accumulation between the epithelium and the crown of an unerupted tooth.<sup>2,3,12</sup>

Dentigerous cysts occur in an assorted range of age group with a peak frequency of 2<sup>nd</sup> to 4<sup>th</sup> decades of life and in the current case it occurred in the 3<sup>rd</sup> decade.<sup>5</sup> Generally mandibular third molars are the most frequently affected, which was seen in our case, followed by the maxillary canine, mandibular second premolar and maxillary third molar.<sup>5</sup> Most of these follicular cysts are asymptomatic consequently they are often noted as an incidental finding on radiographs as in the present case.<sup>7</sup>

Radiographically it may show unilocular radiolucency in association with the crowns of unerupted teeth, having a well-defined sclerotic margins as seen in our case. Trabeculations are seldom seen and may give a false impression of multilocularity. Dentigerous cyst show three different types of radiological variations; which are as follows: central, lateral and circumferential type. The crown is enveloped symmetrically in central variety. The lateral type of dentigerous cyst is a radiographic appearance as a result of dilatation of the follicle on one aspect of the crown. Ultimately in circumferential dentigerous cyst entire tooth appears to be enveloped by cyst. Present case showed central variety of dentigerous cyst.<sup>13</sup>

The differential diagnosis may also include keratocystic odontogenic tumour and unicystic ameloblastoma. A keratocystic odontogenic tumor is less likely to resorb teeth which may attach farther apically on the root instead at the cemento-enamel junction. Significantly KCOT does not expand the bone to the same degree as a dentigerous cyst. It is a challenge to differentiate dentigerous cyst from a small unicystic ameloblastoma if there are no internal structure. There may be evidence of one or several locules although these are few and tend to remain faint or poorly calcified. Unicystic ameloblastoma may show knife edge pattern of root resorption of the apical one third of the adjacent erupted second or first molar. On axial CT scans, most of the dentigerous cysts typically expand in only one direction, usually buccal cortical plate because bone is thinner at this site. With more extensive ameloblastomatous change, expansion may be toward buccal as well as lingual

cortical plates and small locules at the margin of the lesion are suggestive of ameloblastomatous change.<sup>14</sup>

Many dentigerous cysts show evidence of acute and chronic inflammation in their walls. Moreover, the passage of desquamated epithelial cells and inflammatory cells into the cyst cavity may contribute to increased intracystic osmotic tension and thus leads to further expansion of the cyst. As the cyst expands, there may be some compensatory epithelial proliferation to cover the greater surface area of connective tissue according to Browne (1975). Moreover, Stenman et al (1986) also have shown that dentigerous cyst epithelium has little capacity for invitro growth which are also found in our case.<sup>13</sup>

The main treatment modality for dentigerous cyst is enucleation and also removal of the associated tooth which was done in our case. Marsupialization is performed in case of large dentigerous cysts to avoid neurosensory dysfunction and pathological fracture. Untreated dentigerous cysts can evolve into ameloblastoma or squamous cell carcinoma or mucoepidermoid carcinoma.<sup>8,9,10,11</sup> Many of these dentigerous cyst can attain substantial size without any notice to the patient hence, an early intervention in terms of clinical and radiographic detection of the cyst plays a vital role to implement appropriate treatment strategies thereby, to prevent or decrease morbidity.

## REFERENCES:

1. Benn A, Altini M. Dentigerous cysts of inflammatory origin. A clinicopathologic study. *Oral Surg Oral Med Oral Pathol* 1996;81:203-09.
2. Da Silva TA, De Sa AC, Zardo M, Consolaro A, Lara VS. Inflammatory follicular cyst associated with an endodontically treated primary molar: A case report. *ASDC J Dent Child* 2002;69:271-74.
3. Shaw W, Smith M, Hill F. Inflammatory follicular cyst. *ASDC J Dent Child* 1980;47:97-101.
4. Mourshed F. A roentgenographic study of dentigerous cysts. *Oral Surg Oral Med Oral Pathol* 1964;18:466-73.
5. Neville BW, Damm DD, Allen CM, Bouquot JE. *Oral and Maxillofacial Pathology*. 3<sup>rd</sup> ed. Philadelphia, W.B.Saunders; 1995:493-540.
6. Regezi JA, Sciubba JJ, Jordan RCK. *Oral Pathology: clinical pathologic correlations*. 4<sup>th</sup> ed, WB Saunders;2003:241-54.
7. Satya Bhushan SNVV, Rao NM, Navatha M, Kumar BK. Ameloblastoma Arising from A Dentigerous Cyst- A Case Report. *J Clin Diagn Res*. 2014; 8: ZD23-25.
8. Banderas JA, Gonzalez MA, Ramirez F, Arroyo A. Bilateral mucous cell containing dentigerous cysts of mandibular third molars: Report of an unusual case. *Arch of Med Res*, 1996;27:327-29.
9. Johnson LM, Sapp JP, McIntire DN. Squamous cell carcinoma arising in a dentigerous cyst. *J Oral Maxillofac Surg*. 1994;52:987-90.
10. Eversole LR, Sabes WR, Rovin S. Aggressive growth and neoplastic potential of odontogenic cysts. With

- special reference to central epidermoid and mucoepidermoid carcinomas. *Cancer*. 1975;35:270-82.
11. Leider AS, Eversole LR, Barkin ME. Cystic ameloblastoma. *Oral Surg Oral Med Oral Pathol*. 1985; 60:624-30.
  12. Ko KSC, Dover DG, Jordan RCK. Bilateral Dentigerous Cysts - Report of an Unusual Case and Review of the Literature. *J Can Dent Assoc*. 1999;65: 49-51.
  13. Shear M, Speight P. *Cysts of the Oral and Maxillofacial Regions*. 4<sup>th</sup> ed. Australia: Blackwell Munksgaard. 2007;p65.
  14. Stuart C. White, Michael J, Pharoah. *Oral radiology: principles and interpretation*. 6<sup>th</sup>ed. New Delhi. Mosby. 2004;p368.

**How to cite this article:** Sushma P, Sowbhagya MB, Balaji P, Mahesh Kumar TS. Incidental finding of dentigerous cyst - a case report. *J Dent Specialities*,2015;3(2):183-187.

**Source of Support:** NIL

**Conflict of Interest:** All authors report no conflict of interest related to this study.