

# Computed tomography scan evaluation of adequacy for reduction of zygomatic arch fracture using Gillie's temporal approach

Rajratna Manikrao Sonone<sup>1</sup>, Sanjeev Kumar<sup>2</sup>, Pankaj Kukreja<sup>3</sup>, Anuja Agarwal<sup>4</sup>, Alok Bhatnagar<sup>5</sup>, Vidhi Chhabra<sup>6</sup>

## ABSTRACT

<sup>1</sup>PG Student,

<sup>2</sup>Professor and Head,

<sup>3</sup>Associate Professor

<sup>4</sup>Professor

<sup>5,6</sup>Senior Lecturer

Department of Oral and Maxillofacial Surgery,  
ITS-CDSR, Muradnagar, Ghaziabad

### Address for Correspondence:

Dr. Rajratna Manikrao Sonone,  
PG Student, Dept. of Oral and Maxillofacial Surgery, I.T.S-Centre for Dental Studies & Research, Ghaziabad  
E-mail: dr.rajratmams@gmail.com

Received: 24-10-2014

Accepted: 26-03-2015

**Aim:** The zygomatic bone is the key component of the structural facial aesthetics as it constitutes the prominence of the cheek bone. Also, the most frequent clinical findings in zygomatic arch fracture includes limitation of jaw movement and flattening of cheek. So it is necessary to elevate the arch precisely. Therefore, a prospective study was conducted to evaluate adequacy for reduction of zygomatic arch fracture using Gillie's temporal approach with the help of pre-operative and post-operative CT scan.

**Materials & methods:** 4 patients, who received surgical treatment of zygomatico-maxillary complex (ZMC) fractures at the Department of Oral and Maxillofacial Surgery were examined for displacement of zygomatic arch pre-operatively with CT scan then re-evaluated the same site post-operatively.

**Results:** The pre-operative mean displacement at the zygomatic arch, in millimetres (mm), was M = 2.8, SD = 3.011. After reduction, the post-operative displacement was M = 0.4, SD = 0.699. The percentage of reduction was M = 85, SD = 24.15.

**Conclusion:** Gillie's temporal approach for zygomatic arch fracture reduction is precisely considerable due to its simple and effective method and cosmetically more acceptable.

**Keywords:** Zygomatic fractures, Zygomatico-maxillary complex, Fracture

## INTRODUCTION

Face being the most important part of aesthetic concern in the human body is prone for fractures due to road traffic accidents, physical assaults, sports injuries, industrial accidents and so on. Zygomatic fracture management was revolutionized with the advent of internal fixation with wires in 1942. In 1978, Champy's et al proposed the adaptation osteosynthesis with plate and screw fixation. In the early part of twentieth century, different approaches to the zygomatic bone were established and reduction of the fracture without fixation was described.<sup>1</sup>

Gillie's temporal approach was first reported in 1927 by Gillie, Kilner and Stone. It was frequently used because of the short duration of general anaesthesia and minimal morbidity. The advantages of this closed approach are short duration of anaesthesia, decreased possibility of facial nerve damage, decreased indirect trauma to the globe, absence of visible scar.<sup>2</sup>

## MATERIALS & METHODS

This study was conducted in the Department of Oral and Maxillofacial Surgery at I.T.S. Centre for Dental Studies and Research, Muradnagar, Ghaziabad,

Uttar Pradesh. The study was undertaken for a period of one year and six months i.e. from October 2012 till April 2014. Patients with only Zygomatico maxillary fractures were included. All the cases were treated under general anaesthesia. Pre anaesthetic concern, neurology and ophthalmology opinions were obtained for all the cases. Following inclusion and exclusion criteria was followed:

### Inclusion criteria:

1. Fracture through anterior orbital rim and orbital floor,
2. Postero-lateral wall of maxillary sinus,
3. Zygomatic arch,
4. Zygomatico frontal suture.

### Exclusion criteria:

1. Undisplaced ZMC fractures
2. Comminuted ZMC fractures
3. Medically compromised patients who could not be operated under General Anesthesia. (ASA III and above) as described by the American Society of Anesthesiologists' (ASA) classification of Physical Health, 2011.<sup>3</sup>

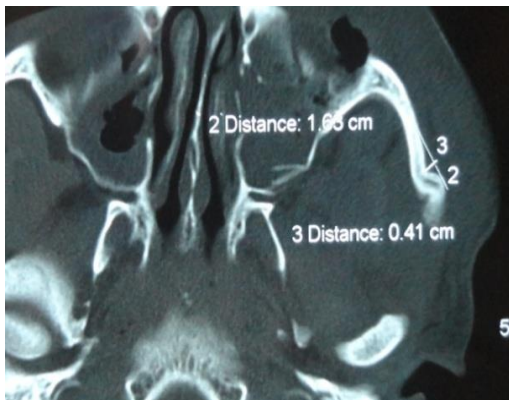
All the patients were sent for pre-operative computed tomography examination which included axial, coronal and sagittal sections with 2 mm slice thickness. A single 3<sup>rd</sup> generation CT machine was used throughout the study for all the radiographic examinations, which had an aperture of 70 centimetres, maximum scan view of 50 centimetres,

Access this article online	
Quick Response Code:	Website: <a href="http://www.its-jds.in">www.its-jds.in</a>
	DOI: 10.5958/2393-9834.2015.00006.6

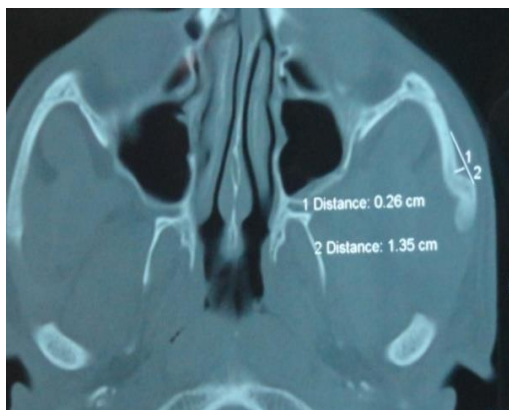
generator power rating of 40 kilowatt and an Ultra Fast Ceramic (UFC) detector

**Gillie’s temporal approach**

After intubation, identification of superficial temporal artery was done, surface markings were carried out with the help of surgical marking pen on temporal region according to Gillie’s technique which describes a temporal incision 2 cm in length, made 2.5 cm superior and anterior to the helix, within the hairline. After local infiltration, short oblique incision was made in the temporal area with the help of 15 numbers B.P. blade above the middle of the zygomatic arch.<sup>4</sup> The incision was dependent to the temporalis fascia and the margins were somewhat undermined. The fascia was incised, taking care not to damage underlying muscle. A suitable instrument, like a Rowe zygomatic arch elevator or a strong periosteal elevator was inserted under the fascia and advanced towards and under the displaced bone fragment to reduce the displaced arch (Figure-15). An audible click and fullness of the cheek together with palpation for normal contour of the zygomatic bone gave an idea about the adequacy of the reduction. The wound was closed in two layers: fascia with Vicryl, and skin with Prolene.<sup>5,6</sup>



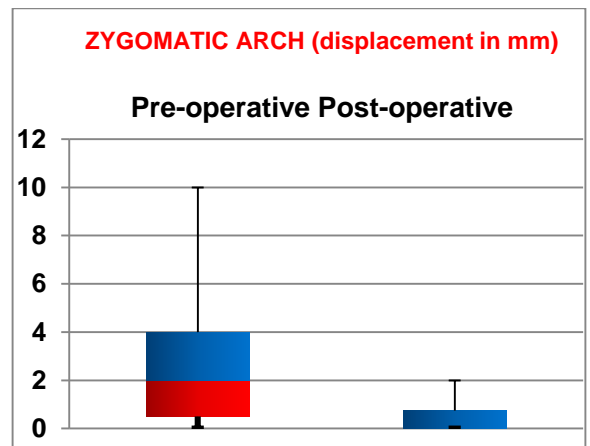
**Fig. 1: Pre-operative CT scan of left zygomatic arch fracture**



**Fig. 2: Post-operative CT scan of left zygomatic arch fracture**

**RESULTS**

The pre-operative mean displacement at the zygomatic arch, in millimetres (mm), was M = 2.8, SD = 3.011, SE = 0.952, MIN = 0 mm, Q1 = 0.5, MED = 2, Q3 = 4, and MAX = 10. After reduction, the post-operative displacement was M = 0.4, SD = 0.699, SE = 0.221, MIN = 0 mm, Q1 = 0, MED = 0, Q3 = 0.75, and MAX = 2. The percentage of reduction was M = 85, SD = 24.15, SE = 7.637, MIN = 50, Q1 = 62.5, MED = 100, Q3 = 100, and MAX = 100. Upon comparison between the two by Wilcoxon Signed-ranks test (two-tailed), it was found that reduction achieved was statistically significant ( $p < 0.05$ ),  $Z = -2.379$ ,  $p = 0.17$ , indicating that the current technique followed gives adequate reduction and fixation of the fracture at the zygomatic arch.



**Fig. 3: Pre-operative and post-operative CT displacement in mm zygomatic arch**

**DISCUSSION**

Zygomatic arch is formed by the temporal process of zygoma and the zygomatic process of temporal bone. The masseter muscle consisting of three superimposed layers which blend anteriorly gains attachment from zygoma and the zygomatic arch. The superficial layer arises from the maxillary process of zygomatic bone and from the anterior two-third of the lower border of the zygomatic arch.<sup>7</sup> The middle layer arises from the deep surface of the anterior two-third of the zygomatic arch. The deep layer arises from the deep surface of the arch. Contraction of this muscle is often implicated as the primary cause of post reduction displacement of the zygoma. Due to the attachment of the temporalis fascia along the superior aspect of the arch, internal fixation is unnecessary even in mildly displaced fractures as the fascia will immobilize the fragments effectively.<sup>7,8</sup>

The transoral (Keen’s) approach provides the most direct access to the zygomatic arch. It allows for an intraoral incision, and therefore does not have the risk of scar alopecia that will result from a temporal (Gillie’s) approach. However, they may result in increased rates of infection by introducing oral flora

into the infratemporal fossa. Gilles *et al.* described the temporal fossa approach in 1927, and this became a very popular method for the treatment of isolated arch fractures<sup>3</sup>. This procedure has advantages in that it leaves no facial scars and is simple to perform. The temporal (Gillie's) approach which is open approach can be considered for the reduction of the zygomatic arch.<sup>8</sup>

The fracture of the zygomatic arch bone can result in restricted mouth opening due to impingement on the coronoid process. Disruption of the zygomatic position also carries psychological, aesthetic and functional significance, causing impairment of ocular and mandibular function. Therefore, for both cosmetic and functional reasons, it is mandatory that zygomatic bone injury is properly diagnosed and adequately managed. Kaastad E, Freng A who also used Gillie's temporal approach and found satisfactory results.<sup>9</sup> Gillie's approach was also the principle technique of reduction used by Balle V et al which is in accordance with our study.<sup>10</sup> Kamath RA et al also used Gillie's procedure for reduction and proved it to be successful for adequate reduction and fixation of ZMC fractures.<sup>11</sup>

The slice thickness of 2mm was kept during CT scanning for every case both pre and post-operative CT scanning. This is in accordance with study done by Zilka A and Chales JS et al who recommended thin slices (2-3mm) because that would decrease the time of scanning and the risk of radiation.<sup>12,13</sup> Cheon SJ et al have stated that Gillie's approach is a promising method as it gives relatively acceptable post-operative facial symmetry and a decrease in the temporal protrusion.<sup>14</sup> The probable reason for good reduction at zygomatic arch region other than the regions involved in zygomatico-maxillary complex fracture is that it has certain advantages, such as direct elevation of the arch with the help of elevator and confirmation of reduction with tactile sensation. Till date Gillie's approach holds the best procedure for the elevation of fractured zygomatic arch.

## CONCLUSION

Thus, we conclude that Gillie's approach for zygomatic arch fracture reduction is precisely considerable due to its simple and effective method and cosmetically more acceptable and CT scan evaluation provides us the vision of best reduction achieved.

## REFERENCES

1. Priya S, Ebenezer V, Balakrishnan R. Versatility of Gillie's temporal approach in the management of ZMC fractures. *Biomed Pharma J* 2014;7:253-6.
2. Gillies HD, Kilner TP, Stone D. Fractures of the malar-zygomatic compound with a description of a new X-ray position. *Br J Surg.* 1927;14:651-3.

3. Daabiss M. American Society of Anesthesiologists physical status classification, *Indian J Anaesth.* 2011;55:111-15.
4. Adam AA, Zhi L, Bing LZ, Zhong Xing WU. Evaluation of treatment of zygomatic bone and zygomatic arch fractures: a retrospective study of 10 years. *J Maxillofac Oral Surg.* 2012;11:171-76.
5. Gillies H D, Kilner T P and Stone D. Fractures of the malar-zygomatic compound with a description of a new X-ray position. *Br J Surg.* 1927;14:651-54.
6. Swanson E, Vercler C, Yaremchuk MJ, Gordon CR. Modified Gillies approach for zygomatic arch fracture reduction in the setting of bicoronal exposure. *J Craniofac Surg.* 2012;23:859-62.
7. Carter TG, Bagheri S, Dierks EJ. Towel Clip Reduction of the Depressed Zygomatic Arch Fracture. *J Oral Maxillofac Surg.* 2005; 63:1244-6.
8. Czerwinski M, Ma S and Williams HB. Zygomatic Arch Deformation: An Anatomic and Clinical Study. *J Oral Maxillofac Surg.* 2008;66:2322-9.
9. Kaastad E, Freng A. Zygomatico-maxillary fractures. Late results after traction-hook reduction. *J Craniomaxillofac Surg.* 1989;17:210-4.
10. Balle V, Christensen PH, Greisen O, Jørgensen PS. Treatment of zygomatic fractures: a follow-up study of 105 patients. *Clin Otolaryngol Allied Sci.* 1982;7:411-16.
11. Kamath RA, Bharani S, Hammannavar R, Ingle SP, Shah AG. Maxillofacial trauma in central karnataka, India: an outcome of 95 cases in a regional trauma care centre. *Craniomaxillofac Trauma Reconstr.* 2012;5:197-04.
12. Zilka A. Computed tomography in facial trauma. *Radiology.* 1982;144:545-8.
13. Chales JS, Terry SB. Normal CT anatomy of the paranasal sinuses. *Radiol Clin North Am.* 1989; 22:107-18.
14. Cheon JS, Seo BN, Yang JY, Son KM. Clinical Follow-up on Sagittal Fracture at the Temporal Root of the Zygomatic Arch: Does It Need Open Reduction? *Arch Plast Surg.* 2013;40:546-52.

**How to cite this article:** Sonone RM, Kumar S, Kukreja P, Agarwal A, Bhatnagar A, Chhabra V. Computed tomography scan evaluation of adequacy for reduction of zygomatic arch fracture using gillie's temporal approach. *J Dent Specialities*, 2015;3(2):156-158.

**Source of Support:** NIL

**Conflict of Interest:** All authors report no conflict of interest related to this study.