

## Management of intra alveolar root fracture in primary incisor: A conservative approach and review of literature

Richa<sup>1,\*</sup>, Neeraj Kumar<sup>2</sup>

<sup>1</sup>Tutor, ESIC Dental College & Hospital, Rohini, New Delhi, India, <sup>2</sup>Senior Resident, Dept. of Pedodontics & Preventive Dentistry, Oral Health Sciences Centre, PGIMER, Chandigarh, Punjab, India

**\*Corresponding Author:**

Email: dr.richamamc2006@gmail.com

### Abstract

Dental traumatic injuries in primary teeth are common in younger children. Root fractures in deciduous teeth are considered as a rare entity among all the dental traumatic injuries. These cases highlight the conservative management of intra alveolar root fracture in primary anterior teeth which were stabilized with multi-flex wire using composite resin. Patients were followed till the eruption of permanent successors. During follow ups, the patients were asymptomatic, roots of the deciduous teeth showed normal physiologic resorption and permanent teeth erupted in their normal position without any developmental defects related to the permanent teeth.

**Keywords:** Root fracture, Primary incisors, Traumatic injuries, Splinting, Developmental defect

### Introduction

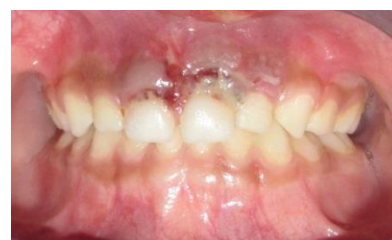Root fractures are the dental traumatic injuries involving the dentin, cementum, and pulp which may affect both primary and permanent teeth. In the permanent dentition, 0.5–7% of the dental traumatic injuries were reported as root fractures and in primary dentition, 2–4% root fractures were reported.<sup>(1)</sup> The peak prevalence of root fractures in primary dentition occurs at 3–4 years of age.<sup>(2)</sup> Management of root fracture depends on various factors like the time for the exfoliation of the deciduous tooth, child's ability to cope with the emergency situation and occlusion of the dentition.<sup>(3)</sup>

The present cases highlight the conservative management of intra alveolar root-fracture of maxillary primary central incisor with semi rigid wire composite splint till the eruption of permanent successors along with review of literature.

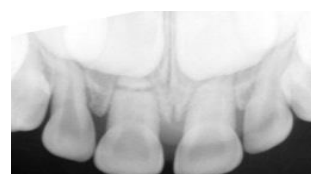### Case 1

A 4 year old boy reported to the Unit of Pediatric Dentistry, PGIMER with the pain and mobility in the upper front teeth following an accidental trauma while playing 2 hours back. Extra oral examination revealed swelling and bleeding from the upper lip. Intra oral examination revealed extrusive luxation of 61 by 1 mm compared to the right maxillary central incisor (Fig. 1) and grade II mobility in both the primary central incisors. Radiographic examination revealed a radiolucent line in the apical third of right maxillary central incisor and permanent tooth bud was in Nolla's stage 5 (crown almost completed) (Fig. 2). Based on the radiographic and clinical findings, diagnosis of horizontal root fracture in right maxillary primary central incisor and extrusion of the left primary maxillary central incisor was made. Because of the parent's concern about the loss of the primary incisors

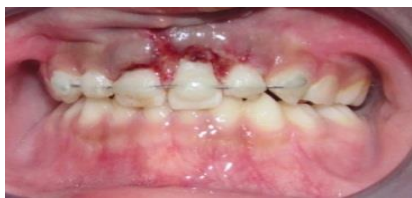at an early age, it was decided to preserve the tooth rather than the extraction of the offending tooth. The blood clot was debrided with normal saline, the maxillary primary central incisors were repositioned and stabilized with semi rigid wire-composite splint. (Fig. 3) The patient was instructed to take soft diet for 2-3 weeks and oral hygiene instructions were given. Analgesic syrup was prescribed as and when required. After 4 weeks, swelling subsided with Grade I mobility in the affected teeth. After 2 months, when the mobility was reduced, the splint was removed. The permanent successors were regularly evaluated to observe any developmental defects. After 24 months follow up, the patient was clinically asymptomatic and radiographic examination showed normal physiologic resorption of both the teeth. (Fig. 4) After 36 months follow up, normal eruption of permanent successors was observed with no complications. (Fig. 5)



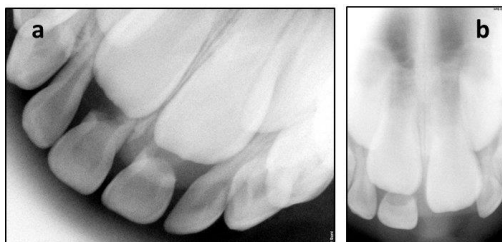
**Fig. 1: Preoperative photographs showing traumatized primary central incisors**



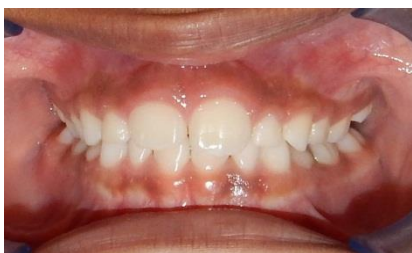**Fig. 2: IOPAR of 51, 61 showing root fracture**



**Fig. 3: Primary central incisors stabilized with semi rigid splint using composite resin**



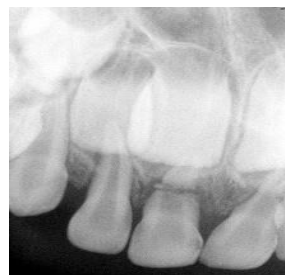**Fig. 4: IOPA of 51, 61 showing normal physiologic root resorption after (a) 18 months and (b) 30 months with no developmental defects**



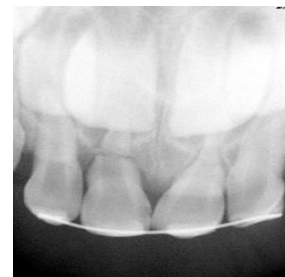**Fig. 5: Permanent successors erupting in normal position after 36 months**

#### Case 2

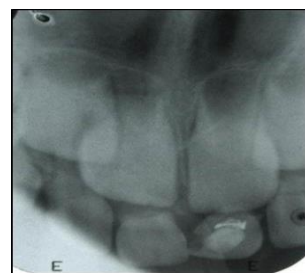
A 4 year old boy reported to the Unit of Pediatric dentistry with the pain in upper front teeth following an accidental trauma while playing 4 hours back. Extra oral examination revealed bleeding from the upper lip. Intra oral examination revealed Class II mobility in primary incisor, 51. On radiographic examination, there was a radiolucent line in the apical third of right maxillary central incisor and the permanent tooth bud was in Nolla's stage 5 (Fig. 6). Based on the radiographic and clinical findings, a diagnosis of horizontal root fracture in 51 was made. The maxillary primary central incisors were stabilized followed by repositioning with semi-rigid wire composite splint. (Fig. 7) The patient was instructed to take soft diet for 2-3 weeks and oral hygiene instructions were given. Analgesic syrup was prescribed as & when required. After 4 weeks, when the mobility has reduced, the splint was removed. The permanent successors were also followed up regularly to observe any developmental defects. The tooth 61 was symptomatic, root canal was opened and Metapex (Biomed, Korea) was placed and sealed with GIC (GC Fuji II). After 24 months follow up, the patient was clinically asymptomatic and radiographic examination showed normal physiologic resorption of 51. (Fig. 8)



**Fig. 6: Preoperative radiograph showing root fracture w.r.t. 51**



**Fig. 7: IOPAR showing splinting with semi rigid wire using composite resin**



**Fig. 8: IOPAR showing physiologic root resorption of 51, 61 after 24 months of follow up**

#### Discussion

The root fracture is a rare injury in the primary and permanent dentition among the dental traumatic injuries. In the primary dentition, root fracture is not a common phenomena and most frequently occurs at the age of 3–4 years when the physiologic root resorption has begun, thereby weakening the root and also the resiliency of the surrounding bone makes the primary teeth more vulnerable to displacement injuries.<sup>(3)</sup> The most common etiology for the dental traumatic injuries among younger children is lack of motor coordination between 1-3 years, fall while playing during sports activity followed by motor vehicle accident among 3 year or older. Upper anterior teeth were found to be most commonly traumatized teeth. In the present cases also root fracture occurs due to the fall while playing.<sup>(4)</sup>

The primary objective of treatment in the deciduous dentition is to allay fear and anxiety in both the children and parents, provide comfort to the patient and to prevent damage to succedaneous tooth.

According to IADT guidelines, the treatment protocol of intra alveolar root fracture occurred is to

extract the coronal fragment if it is mobile and leave the apical fragment intact. If the coronal fragment is stable and the patient cooperates, a semi rigid wire splinting may be indicated. If we follow these guidelines, most of the root fractured incisors would be extracted.<sup>(5)</sup> Xin Liu et al managed the root fractures in primary teeth using orthodontic brackets.<sup>(6)</sup> The disadvantage with orthodontic brackets are that orthodontic wires are

never passive and generate forces, which may result in tipping of teeth, since the force developed by these wires is higher.<sup>(7)</sup> Jang et al stabilized the tooth with the composite wire splint and followed till the eruption of permanent successor.<sup>(8)</sup> Endodontic treatment was performed in one of the cases. All the reported cases of intra alveolar root fracture are tabulated with the treatment modality opted for the case. (Table 1)

**Table 1: Review of the cases of root fractures of primary anterior teeth and its management in the literature**

Author, Year	Age/Sex	Trauma	Tooth affected	Treatment	Follow up
Xin Liu et al, 2012 <sup>(6)</sup>	3.5/F	Fall at school (16 hours back)	51- Horizontal root fracture (apical third) 61- Horizontal root fracture (middle third) with extrusion	Splinting with orthodontic brackets for 3 months	2.5 years- Permanent successor erupted
Jang JH et al, 2013 <sup>(8)</sup> Case 1	4/M	Fall while playing	51- Horizontal root fracture (apical third)	Splinting with resin wire splint for 8 weeks	30 months - Permanent successors erupted with no pathologic lesion
Case 2	3.5/M	Fall at home	51,61- Horizontal root fracture (middle third)	Splinting with resin wire splint for 4 weeks	16 months - Permanent successors with no pathologic lesion
Gadicherla P et al, 2016 <sup>(9)</sup>	3.5/F	Fall while playing (2 days back)	51- Horizontal root fracture (apical third) 61- Complicated crown root fracture	51- Kept under observation 61- Pulpectomy with restoration	4 months- asymptomatic
(Present Case-1)	4/M	Fall while playing (2 hours back)	51- Horizontal root fracture (apical third)	Splinting with resin wire splint for 8 weeks	3 years follow up- permanent successor erupted with no developmental anomaly
(Case-2)	4/M	Fall while playing (4 hours back)	51- horizontal root fracture (middle third)	Splinting with resin wire splint for 4 weeks	2 years follow up showing normal physiologic root resorption

The treatment of the root fracture in children usually depends on the child cooperation level and the amount of tooth structure lost due to trauma. Extraction of tooth at an early age not only affects the aesthetic, speech problems, psychological impact, but also affects the quality of life of the children. In contrast, the conservative management of primary teeth offers various advantages such as aesthetics, maintains the functions like mastication and prevent psychological trauma to the parents and children. Thus, in the present cases, root fracture with the mobility in the coronal fragment was conservatively managed with semi-rigid splinting using multi-flex wire with composite. Thus, a conservative approach was adopted to maintain the teeth till the eruption of permanent successors.

In cases of intra alveolar root fracture, regular radiographic follow-up is required to rule out the potential risk for permanent successors to be malformed due to position of the permanent tooth germ close to the roots of the primary teeth.<sup>(5)</sup> Depending on the type, severity of the injury and the developmental stage of the permanent tooth, a prevalence of 12-69% of the developmental anomalies were found among the permanent teeth.<sup>(2)</sup> Flores MT et al also reported 23 % developmental disturbances in 225 traumatized primary teeth with highest prevalence associated with the intrusive injuries.<sup>(10)</sup> In the present cases, follow up examination revealed normal eruption of succedaneous teeth with no developmental disturbances (color changes, gingival recession, pulp necrosis, pulp canal obliteration, peri-apical lesion, displacement of

succedaneous teeth, disturbances in the eruption, dilaceration and pathological root resorption) of the permanent teeth. Thus, the present conservative approach proved to be favorable for primary teeth with root fracture as it maintained the primary tooth in the arch without affecting the succedaneous tooth.

### Conclusions

Root fracture in the primary dentition is a rare entity which could be managed conservatively till the eruption of succedaneous teeth to prevent psychological trauma to both patient and parents. Semi rigid splinting could be a conservative method in root fracture to prevent extraction at an early age. These cases should be followed radiographically and clinically till the eruption of permanent successors.

### References

1. Andreasen JO, Andreasen FM. Essentials of traumatic injuries to the teeth. Copenhagen: Munksgaard; 1990. p168.
2. Poi WR, Manfrin TM, Holland R, Sonoda CK. Repair characteristics of horizontal root fractures: a case report. *Dent Traumatol* 2002;18:98-102.
3. Dental Trauma Guidelines- Revised 2012. International Association of Dental Traumatology
4. Andreasen JO, Bakland KL, Matras RC, Andreasen FM. Traumatic intrusion of permanent teeth. Part1. An epidemiological study of 216 intruded permanent teeth. *Dent Traumatol* 2006;22(2):83-9.
5. Malmgren B, Andreason J, Flores MT. Guidelines for the management of traumatic dental Injuries in the primary dentition. *Dent Traumatol* 2012;28:174-82.
6. Liu X, Huang J, Bai Y, Wang X, Baker A, Chen F, et al. Conservation of root-fractured primary teeth: Report of a case. *Dent Traumatol* 2013;29(6):498-501.
7. Oikarinen K. Tooth splinting: A review of literature and considerations of the versatility of a wire-composite splint. *Endod Dent Traumatol* 1990;6(6):237-50.
8. Jang JH, Park JH, Kim KC. Conservative treatment of intra alveolar root fracture of primary incisors using resin wire splint: Case report. *J. Korean Acad Pediatr Dent* 2013;40(1):53-9.
9. Gadicherla P, Devi M.M. Root fracture in primary teeth. *J Dent Oro Facial Res* 2016;12(1):33-5.
10. Flores MT. Traumatic injuries in the primary dentition. *Dent Traumatol* 2002;18:287-98.