

Association of kissing odontome and molar - A case report

Rupam Singha¹, Biyas Bhowmik^{2,*}, Soumyabrata Sarkar³, Ishita Banerjee⁴, Subhadeep Maity⁵, Anirban Maji⁶

^{1,2,4,5}Senior Lecturer, ³Reader, ⁶PG Student, Dept. of Oral Medicine & Radiology, Haldia Institute of Dental Sciences & Research, Haldia, West Bengal, India

***Corresponding Author:**

Email: biyas6bhowmik@gmail.com

Abstract

Odontomas are the benign odontogenic tumors, usually asymptomatic and discovered incidentally during routine radiologic investigations, but sooner when infected. Complex odontomas are irregular calcified masses of dental tissues, with a disorderly arrangement, that bear no morphologic similarity to teeth. We report a case of infected unerupted complex odontoma in the posterior mandible of an adult patient with clinical and radiologic features.

Keywords: Odontome, Odontogenic tumors, Complex, Compound

Introduction

The term “odontome” refers to any tumour of odontogenic origin. An odontoma is a mixed tumor composed of both epithelial and mesenchymal cells, which exhibit complete differentiation resulting in functional ameloblasts and odontoblasts, which in turn form enamel and dentin respectively. The enamel and dentin are subsequently laid down in an abnormal pattern due to the failure of organization of the odontogenic cells to reach a normal state of morphodifferentiation.⁽¹⁾ First described by Paul Broca in 1967, now odontomas are considered as hamartomas rather than true neoplasms, composed of mature enamel, dentin, cementum and pulp tissues.⁽²⁾

Worth classified odontomes according to ectodermal origin (Enameloma), mesodermal origin (dentinoma, cementoma), mixed origin (complex composite odontome, compound composite odontome, geminated odontome, dilated odontome, including dens in dente).⁽³⁾

The WHO Histologic Typing of Odontogenic Tumours, second edition, classifies odontomas into complex composite, compound composite, and ameloblastic odontoma. Complex odontomas, represent dental tissues that are well formed, but exhibit an amorphous and less orderly arrangement. Compound odontomas, represent dental tissues that are normal, arranged in an orderly pattern, but their size and conformation are altered, giving rise to multiple small teeth-like elements called “denticles”. Adding to these types, Ameloblastic odontoma or odontoameloblastoma is another rare tumor, consisting of a mixture of enamel, dentin, cementum, and dentinoid and osteoid material and dental papilla, held within the stromal connective tissue. Thus, it is characterized by the concomitant occurrence of ameloblastoma and composite odontoma within a single entity.^(1,4) Recently, a “hybrid” type of odontogenic neoplasm, histologically identical to other odontogenic tumors such as ameloblastoma, adenomatoid odontogenic tumor

(AOT), ameloblastic fibroma (AF), and ameloblastic fibro-odontoma (AFO) has been proposed.⁽⁵⁾

According to their clinical presentation, odontomas have also been classified as central, peripheral and erupted odontoma. The central/intraosseous odontomas are common (51%), occurring in anterior maxilla (compound odontoma) followed by mandibular molar region (complex odontoma). Extraosseous peripheral complex odontomas occur uncommonly in the maxillary sinus, while the compound type is seen in the gingiva. The erupted odontoma is the one which is present coronal to an erupting or impacted tooth or its superficial location in the bone may have enabled its eruption into the oral cavity.⁽⁶⁾ Odontomas constitute 22% of all odontogenic tumors, wherein the complex composite entity accounts for 5-30% of all odontomes. The most uncommon type of odontome is ameloblastic odontoma followed by the complex composite and compound composite respectively.^(1,5)

Case Report

An 18-year old male patient reported to Department of Oral Medicine and Radiology, Haldia Institute of Dental Sciences & Research, Haldia, West Bengal with the chief complaint of a painful swelling in left lower jaw since 5 months. There had been multiple episodes of pain and swelling in relation to the same region in the preceding months that were subsequently relieved on medication. Patient’s personal, medical and dental history were non-contributory. The patient was conscious, co-operative with normal gait and vital signs. Extraoral examination revealed mild facial asymmetry on the left without any palpable lymph node. On intraoral examination, an apparent absence of left mandibular second molar (37) was noted, along with a breach in the corresponding alveolar mucosa.

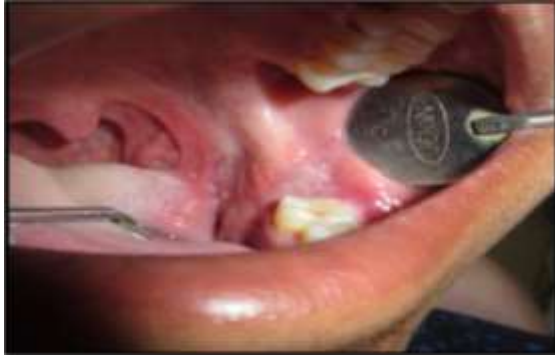
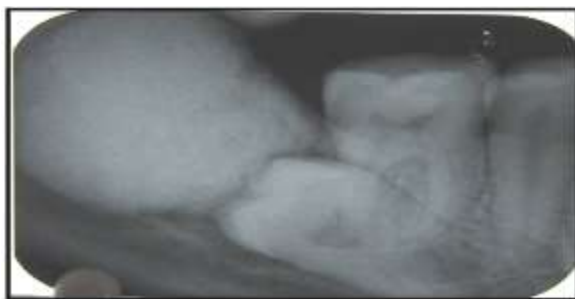
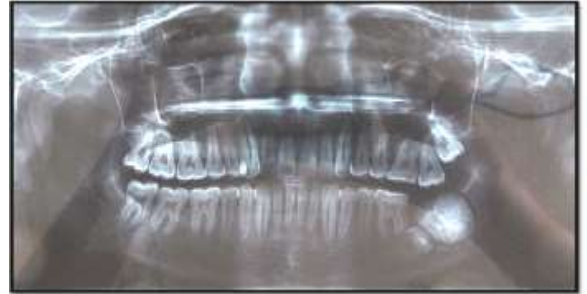Fig. 1: Absence of left mandibular second molar (37) with tearing of overlying alveolar mucosa distal to left mandibular first molar.

A swelling, with normal overlying mucosa, measuring approximately 1cm x 0.5cm in dimension, was present on the buccal aspect of left posterior mandibular region, with obliteration of the buccal vestibule and expansion of buccal cortical plates. It was hard and tender on palpation. (Fig. 1) No bleeding and pus discharge was elicited during palpation. Based on history and clinical features, a provisional diagnosis of infected dentigerous cyst was suggested in relation to left mandibular second molar, with a differential diagnosis of odontoma and unicystic (mural) ameloblastoma. The IOPAR revealed a well-defined, radiopaque mass with irregular borders, attached to the coronal aspect of a completely impacted (horizontal impaction) left mandibular second molar, the occlusal surface of which was attached with the mesial surface of the calcified mass. The radiopaque mass was uniform with the density greater than that of bone, and equivalent to that of teeth. Lower border of the mass was circumscribed by a thin, irregular radiolucent halo. Panoramic radiograph showed a uniformly dense, rounded radiopacity (approximately 3 cm x 2.5 cm in dimension), distal to horizontally impacted left mandibular second molar. Radiopaque area was amorphous, circumscribed by a thin, irregular radiolucent border. (Fig. 2)



a



b

Fig. 2: A. IOPAR shows an irregular, well-defined, radiopaque mass attached to the coronal aspect of impacted left mandibular second molar. B. Panoramic radiograph showed a rounded radiopacity, in association with unerupted left mandibular second molar. The dense radiopaque area was amorphous, and circumscribed by a thin, irregular radiolucent boundary.

The patient was treated by excision of the lesion, done conservatively, using an intraoral approach, in order to preserve the periosteum and mandibular basal cortical bone, which was quite thin. During surgery, the odontome along with impacted left mandibular second molar, which exhibited no apparent changes in shape and size, were removed. (Fig. 3) The surgical cavity was totally smoothed and the mucoperiosteal flap was closed with interrupted sutures. Histopathologic examination revealed irregularly arranged tubular dentin, cementum and pulp tissue embedded within loose fibrous connective tissue. (Fig. 4) Hence, based on the clinical, radiological, and histopathologic investigations, the final diagnosis of infected complex odontome was confirmed. One year follow-up showed that the bone healing was uneventful.

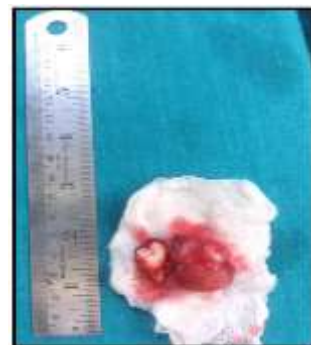

Fig. 3: Surgically removed odontome, “kissing” the coronal aspect of impacted left mandibular second molar

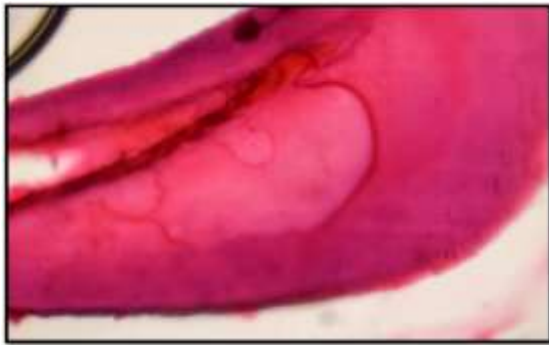


Fig. 4: Sheets of tubular dentine and pulp, bounded peripherally by cementum

Discussion

WHO has classified odontomas as benign mixed odontogenic tumors that frequently lead to impaction, delayed eruption of permanent teeth, malposition, or tooth malformation.⁽⁶⁾ Clinical presentation might be asymptomatic or the odontoma might be associated with pain, expansion of cortical plates, tooth displacement, lip numbness, swelling, and devitalization of adjacent tooth.^(1,2)

The etiology of odontome is idiopathic, however, it has been attributed to local trauma, inflammation and/or infection, hereditary anomalies (Gardner's syndrome, Hermann's syndrome), odontoblastic hyperactivity, or genetic mutation.⁽⁷⁾

Occurrence of complex odontomas peak in the second and third decade of life, with a male predilection ratio of 1.5:1. Further, most of them are located in the mandibular molar region followed by anterior maxilla. Complex odontomas occur less commonly than the compound variety in the ratio of 1:2.⁽⁶⁾ Peripheral complex odontomas have been reported in the maxillary sinus, subcondylar regions, and floor of the mouth.^(8,9)

These hamartomas are incidental findings on radiographs, appearing as amorphous radio-opaque masses, surrounded by a fine radiolucent rim (suggestive of connective tissue capsule histologically), which in turn is circumscribed by a thin sclerotic line. The radiological appearance of complex odontomas depends on their development stage and corresponding degree of mineralization. The first stage is characterized by radiolucency sans any calcification, the intermediate stage by partial calcification; while in the third stage, the lesion usually appears completely radiopaque with disorganized masses of mineralized dental tissue surrounded by a radiolucent halo.⁽¹⁰⁾

Histologically the complex odontoma is characterized by sheets of haphazardly arranged tubular dentin, pulp, and cementum, with enamel confined to small rims in cavities in the dentin mass, embedded in a loose, myxoid connective tissue stroma. Cementum-like tissues are often admixed with dentinoid structures, with presence of ghost cells, especially in complex odontoma. A thin fibrous connective tissue capsule is usually seen surrounding the lesion. The present case revealed similar histological findings.⁽¹¹⁾

Conservative surgical excision of the lesion is the treatment of choice. Since the lesion is encapsulated, recurrences are rare. In children and adolescents, odontomas should be removed when the permanent teeth adjacent to the lesion exhibit about one half of their root development because this ensures safety of the normal permanent teeth and prevents interference with their eruption. Kaban states that odontomas are easily enucleated and adjacent teeth are seldom harmed by the excision, since they are usually separated from the lesion by a septum of bone.⁽¹²⁾

As a differential diagnosis, complex odontomas has to be differentiated from cemento-ossifying fibromas by the tendency of odontomas to associate with unerupted molar teeth and their property of being more radiopaque than fibromas. Periapical cemento-osseous dysplasia/focal cementoosseous dysplasia (PCOD/FCOD) are mature fibro-osseous osseous lesions, which must be differentiated from mature complex odontomas. Usually the PCOD or FCOD form, in persons in their fourth and fifth decades of life, whereas a complex odontoma develops in patients in second or third decade of life. PCOD has a predilection for mandibular anterior region, and is situated deep in the alveolar bone, whereas a complex odontoma often extends high into the alveolus towards the crest of the ridge. Ameloblastic fibro-odontoma, believed to be an early, undifferentiated complex odontoma, is another differential, with more connective tissue as seen in ameloblastic fibroma. Odontoameloblastoma is an extremely rare condition and involves the simultaneous occurrence of an ameloblastoma and a complex odontome.^(1,13)

Conclusion

An infected unerupted complex odontoma in the mandibular molar region has been reported. Symptomatic cases associated with pain, inflammation should be treated promptly. Simultaneously, the patients' families should provide adequate psychological and nutritional support to cope with the process. Early diagnosis and proper management of odontomas also prevents future craniofacial complications and other developmental anomalies.

References

1. Shafer WG, Hine MK, Levy BM. Cyst and Tumours of Odontogenic origin. A Textbook of Oral Pathology 7th ed. Philadelphia: Elsevier Noida; 2009. pp. 292–94.
2. Gurdal P, Seckin T. Odontomas. Quintessence Int 2001;4:32-8.
3. Worth HM. Principles and Practice of oral radiographic interpretation. Year Book Medical Publishers, Chicago 1963. pg 420-38.
4. Barnes L, Everson JW, Reichart P, Sidransky D. Eds., World Health Organization Classification of tumours. Pathology and Genetics of Head and Neck Tumours, IARC Press, Lyon, France, 2005.
5. Phillips MD, Closmann JJ, Baus MR, Torske KR, Williams SB. Hybrid odontogenic tumor with features of ameloblastic fibro-odontoma, calcifying odontogenic cyst, and adenomatoid odontogenic tumor: A case report and review of the literature. J Oral Maxillofac Surg 2010;68:470–4.
6. Bagewadi SB, Kukreja R, Suma GN, Yadav B, Sharma H. Unusually large erupted complex odontoma: A rare case report. Imaging Sci Dent 2015;45:49-54.

7. Levy SH. Cysts and Tumours of the Jaws. In Textbook of Oral Pathology. 4th ed. United States: W. B .Saunders Company; 2003.
8. De Visscher JG, Güven O, Elias AG. Complex odontoma in the maxillary sinus. Report of 2 cases. *Int J Oral Surg* 1982;11:276-80.
9. Seckinger C, Wang S, Anastasio D. Extrasosseous odontoma in the floor of the mouth: report of a case and literature review. *Cas Clinique Med Buccale Chir Buccale* 2015;21(4):253-56.
10. Philipsen HP, Reichart PA. Classification of odontogenic tumours. A historical review. *J Oral Pathol Med* 2006;35:525-9.
11. Cohen DM, Bhattacharyya I. Ameloblastic fibroma, ameloblastic fibro-odontoma, and odontoma. *Oral Maxillofacial Surg Clin N Am.* 2004 Aug;16(3):375-84.
12. Kaban LB: *Pediatric Oral and Maxillofacial Surgery.* Philadelphia: Saunders, 1990. pp 111-12.
13. Wood NK, Goaz PW. *Differential diagnosis of oral maxillofacial lesions.* 5th ed. St. Louis: Mosby; 2007. pp 492.