



Case Report

Indirect sinus lift with implant placement in maxillary right molar region

Sunil Kumar Singh¹, Ashish Kamboj^{2*}, Chandni Ghildiyal³, SS Chopra⁴, Paras Angrish⁵

¹Air Force Dental Center, Kanpur, Uttar Pradesh, India

²Military Dental Centre, Delhi Cantt, New Delhi, India

³Dept. of Periodontology, Rama Dental College Hospital and Research Centre, Kanpur, Uttar Pradesh, India

⁴Dept. of Orthodontics, Army Dental Centre (R&R), Delhi Cantt, New Delhi, India

⁵Govt. Dental Centre, Tangtse, (UT of Ladakh), India



ARTICLE INFO

Article history:

Received 05-08-2024

Accepted 14-09-2024

Available online 20-09-2024

Keywords:

Indirect sinus lift

Maxillary sinus

ABSTRACT

The maxilla has one of the least dense bone masses in the oral cavity and is composed of porous bone. Due to considerable alveolar bone resorption brought on by periodontal disease-induced tooth loss, there is an emphasis on bone reduction in both height and width. Pneumatization of the maxillary sinus, post-extraction bone resorption, and low-quality remaining alveolar bone all contribute to the difficulty in bone remodelling.

Indirect sinus augmentation is an effective solution for this problem. This case report presents the rehabilitation of maxillary right first molar by using indirect sinus lift with implant placement where the bone height and bone width was compromised.

This is an Open Access (OA) journal, and articles are distributed under the terms of the [Creative Commons Attribution-NonCommercial-ShareAlike 4.0 License](https://creativecommons.org/licenses/by-nc-sa/4.0/), which allows others to remix, tweak, and build upon the work non-commercially, as long as appropriate credit is given and the new creations are licensed under the identical terms.

For reprints contact: reprint@ipinnovative.com

1. Introduction

The residual bone in the right quantity and quality is essential for the implant to be positioned correctly.¹ Missing teeth can be functionally and aesthetically restored with dental implants. Inadequate bone quantity and quality frequently make implant placement in the posterior maxilla more difficult. Lack of sufficient bone height needed for effective implant therapy is a common issue when inserting implants in the posterior maxilla region. Sinus lift procedures are the treatment of choice. There are two treatment modalities for sinus lifting direct and indirect. The method of indirect sinus floor elevation is the recommended one. This case study describes how an indirect sinus lift technique was used to restore the maxillary right molar region with decreased height and width of bone.

*Corresponding author.

E-mail address: aashishkamboj@gmail.com (A. Kamboj).

2. Case Report

A 36-year-old male patient reported to the 8 AFDC Kanpur, with the chief complaint of missing teeth in upper right back region since 1 year. A complete clinical evaluation was done, followed by CBCT and OPG. The patient wanted implant as substitute of missing teeth. On evaluation of radiographs it was found that the right upper molar region had only 5.5 mm of bone height, and thus an indirect sinus lift procedure was planned.

2.1. Surgical phase

Implant selected was of 4.2 mm diameter and 8 mm length.

Local anesthesia was given and mid crestal incision was done using no 15 BP blade .

Flap was reflected. Initial depth was achieved using a 2-mm pilot drill at a speed of 800 RPM with saline irrigation.

Indirect sinus lifting was done using sinus elevation osteotomes of various gauges from 2.7, extended up to 3.7 into the sinus floor.

Gentle tap was given with a mallet on sinus lift osteotome to lift the sinus floor.

After final osteotomy, implant was driven at 20 rpm and 50 Ncm torque. Cover screw was placed and suturing was done.

The sinus lift procedure was evaluated using an OPG.

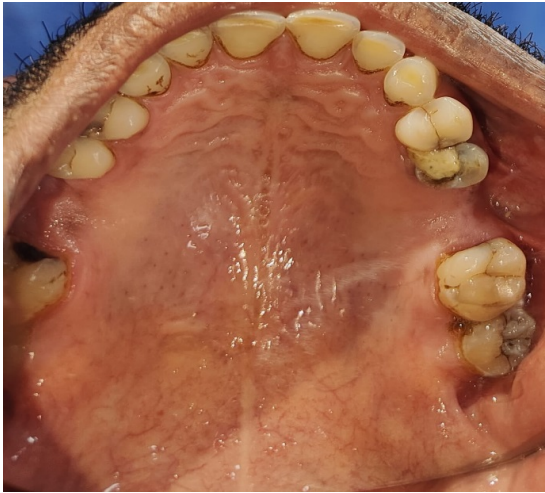

Figure 1: Pre-operative photograph showing missing 16

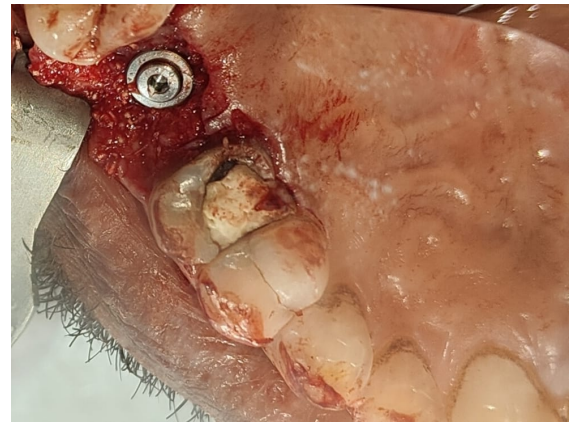


Figure 3: Implant placement

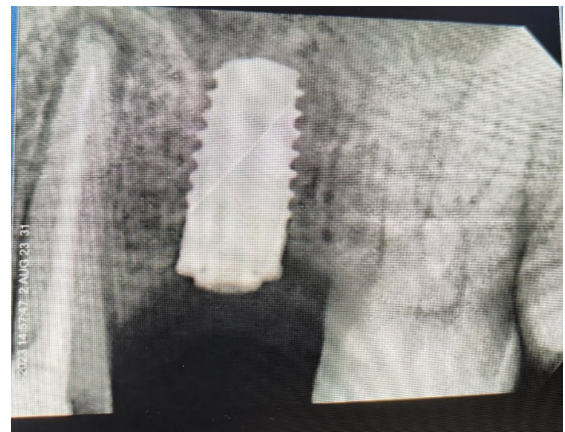


Figure 4: IOPA showing post implant placement

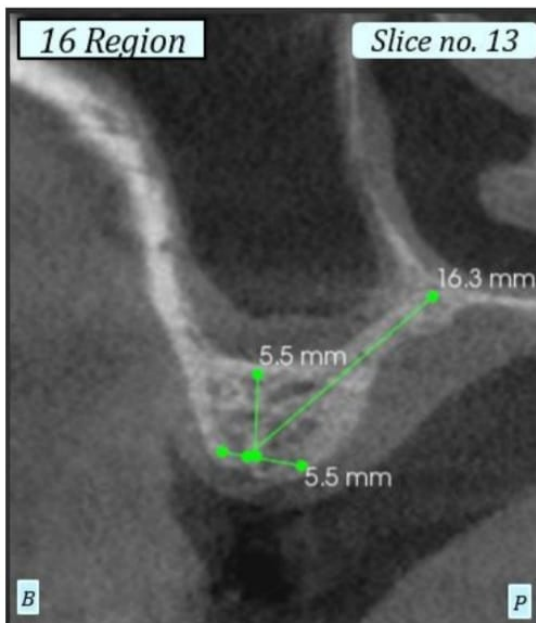


Figure 2: CBCT showing bone width and height

3. Discussion

Placement of implants has emerged as the most popular method of replacing lost teeth. Pneumatization of the maxillary sinus following tooth loss and dimensional changes to the remaining ridge frequently prevent implants of the appropriate length and diameter from being inserted in the posterior maxillary sextants.

The maxilla has one of the least dense bone masses in the oral cavity and is composed of porous bone. Maxillary sinus floor elevation has become a crucial preplacement process in dental implant treatment planning in order to accommodate, avoid, and treat this physiological as well as anatomical constraint.

Numerous methods have emerged to increase the thickness of maxillary sinus floor. The main aim of all such procedures is to increase the bone height. Certain methods entail the straightforward and minimal elevation of the maxillary sinus membrane, also known as the Schneiderian membrane. Other methods entail the implantation of grafts, such as autografts, allografts, bone morphogenetic proteins, and hydroxyapatite crystals.

Sinus floor elevation can be performed using different surgical techniques with a lateral window approach or a transalveolar approach. The transalveolar approach of sinus floor elevation using osteotomes with increasing diameters was described by Summers (1994).² Fugazzotto et al suggested that the maxillary sinus floor be elevated with bone graft and one- stage surgery when residual bone height is greater than 5mm.³ According to Kendrick DE two-stage lateral sinus augmentation is indicated when available bone height is 3mm, one- stage lateral sinus augmentation when 3- 4mm of bone height is available and one-stage crestal approach when available bone height is above 4-5mm.⁴ Also Krasny K et al recommend using two-stage closed sinus lift technique when alveolar ridge height is less than 3mm.⁵ The Lateral approach for sinus augmentation is more invasive and prone to more complications.⁶ The one- stage transalveolar approach also reduces healing time by 50% and omits the need of a second surgery to place implants. This technique has high survival rates, allows for localized sinus floor elevation, is more conservative, has low postoperative morbidity and shorter implant loading time. Osteotomes were used as they cause less trauma and generate little or no heat and also conserve bone by compressing it.⁷

While the indirect technique uses a crestal approach, the direct technique typically approaches the sinus through the lateral window.⁸ The present case showed a bone height of 5.5 mm radiographically and the sinus floor was elevated up to 2.5 mm for the placement of implant of 8 mm length and 5.5 mm diameter. Limited augmentation is possible with the indirect sinus lift/crestal techniques, despite their low invasiveness. In cases where there is inadequate preoperative residual ridge the crestal approach for sinus augmentation provides 97% success rate, minimizing Schneiderian membrane perforation and the bone would form around the implant in 4 months and could be loaded. The limitation of this technique is that it is a blind procedure and only 2 to 3 mm of sinus elevation can be achieved.⁹

4. Conclusion

This case study demonstrates a minimally invasive technique designed to raise the sinus floor for implant placement. Sometimes the insertion of implants can be cumbersome due to reduced alveolar bone height and presence of anatomical defects, such as maxillary sinus. The indirect sinus lift procedure helps by keeping the technique safe and with good success rate.

5. Source of Funding

None.

6. Conflict of Interest


None.

References

1. Sani E, Veltri M, Cagidiaco MC, Balleri P, Ferrari M. Sinus membrane elevation in combination with placement of blasted implants: a 3-year case report of sinus augmentation without grafting material. *Int J Oral Maxillofac Surg.* 2008;37(10):966–9.
2. Summers RB. A new concept in maxillary implant surgery: The osteotome technique. *Compendium.* 1994;15(2):152.
3. Fugazzotto PA, Vlassis J. Long-term success of sinus augmentation using various surgical approaches and grafting materials. *Int J Oral Maxillofac Implants.* 1998;13(1):52–8.
4. Kendrick DE. Vertical Implant Diagnosis and Treatment Planning for the Posterior Edentulous Maxilla Alveolar Ridge Augmentation. In: *Implant Dentistry: A Surgical Manual.* Joh Wiley Sons, S Inc; 2016. p. 135–43.
5. Krasny K, Krasny M, Kaminski A. Two-stage closed sinus lift: A new surgical technique for maxillary sinus floor augmentation. *Cell Tissue Bank.* 2015;16(4):579–85.
6. Bechara S, Kubilius R, Veronesi G, Pires J, Shibli J, Mangano FG, et al. Short (6-mm) dental implants versus sinus floor elevation and placement of longer (≥ 10 -mm) dental implants: a randomized controlled trial with a 3-year follow-up. *Clin Oral Implants Res.* 2017;28(6):1097–107.
7. Rambla-Ferrer J, Peñarrocha-Diago M, Guarinos-Carbó J. Analysis of the use of expansion osteotomes for the creation of implant beds. Technical contributions and review of the literature. *Med Oral Patol Oral Cir Bucal.* 2006;11(3):267–71.
8. Toffler M. Osteotome-mediated sinus floor elevation: a clinical report. *Int J Oral Maxillofac Implants.* 2004;19(2):266–73.
9. Woo I, Le BT. Maxillary sinus floor elevation: review of anatomy and two techniques. *Implant Dent.* 2004;13(1):28–32.

Author biography

Sunil Kumar Singh, Oral & Maxillofacial Surgeon

Ashish Kamboj, Orthodontist  <https://orcid.org/0000-0002-1836-6786>

Chandni Ghildiyal, Post Graduate Student

SS Chopra, Professor and HOD

Paras Angrish, Pedodontist

Cite this article: Singh SK, Kamboj A, Ghildiyal C, Chopra SS, Angrish P. Indirect sinus lift with implant placement in maxillary right molar region. *J Dent Spec* 2024;12(2):151-153.