

# Restoring Esthetics by Clinical Crown Lengthening

Saxena S<sup>1</sup>, Khatri M<sup>2</sup>, Jain D<sup>1</sup>, Bansal M<sup>1</sup>,

## Abstract

Clinical crown lengthening is a procedure designed to increase the extent of supra-gingival tooth structure for restorative or esthetic purposes. Crown lengthening procedure involves combination of tissue reduction or removal, osseous surgery and/ or orthodontics for tooth exposure. Crown lengthening should be performed by taking into account some important principles, like respect for the biological width, creation of a ferrule, placement and location of restorative margins. Periodontal health is the corner-stone of any successful restorative procedure. Hence, condition of periodontal tissues during restoration of the tooth, is important to the restoration's future success. This article focuses on different surgical treatment modalities for clinical crown lengthening leading to healthy periodontal tissue, successful restoration and future success.

**Key words:** Biological Width, Crown Lengthening, Restorative Margins.

## Introduction

Clinical crown lengthening refers to procedures designed to increase the extent of supra-gingival tooth structure for restorative or esthetic purposes.<sup>1</sup> The concept of crown lengthening was first introduced by D. W. Cohen (1962) and is presently a procedure that often employs some combination of tissue reduction or removal, osseous surgery and/or orthodontics for tooth exposure. The amount of tooth structure exposed above the osseous crest must be enough to provide for a stable dentogingival complex and biologic width to permit proper tooth preparation and account for an adequate marginal placement, thus ensuring a good marginal seal with retention for both provisional and final restorations.<sup>2</sup>

The present case report depicts the use of

surgical crown lengthening as a treatment modality in reduced vertical dimension. The most common surgical modality used to increase the clinical crown length is gingivectomy and the apically positioned flap in conjunction with resective osseous surgery. This technique will increase the clinical crown length with maintenance of biological width and the dentogingival complex will be re-formed.<sup>3</sup> Resective osseous surgery for exposure of adequate clinical crown length provides the proper placement of margins, enhances the retention<sup>4</sup> and creates a periodontal environment in which plaque control procedures can be more effectively performed.<sup>5</sup>

## Case Series

### Case 1

A 20 year male patient was referred from the

**Corresponding Author :** Dr. Sameer Saxena, Senior Lecturer Department of Periodontics, Institute of Dental Studies & Technologies, Modinagar, U.P. 201201 (M) +919412619458 E-mail: saxena.sameer27@gmail.com

1. Senior Lecturers, Department of Periodontics, Institute of Dental Studies & Technologies, Modinagar, U.P.

2. Professor & Head, Department of Periodontics, Institute of Dental Studies & Technologies, Modinagar, U.P.

Department of Conservative dentistry to the department of Periodontics, IDST, Modinagar for the lengthening of clinical crown. Clinical examination revealed carious left canine, with inadequate tooth structure on distal and palatal aspect for restoration. A post and core was planned and exposure of tooth structure was required for proper placement of margins. The gingiva consisted of a wide zone of keratinized tissue and sulcus depth was 2mm on disto-buccal and the palatal aspect as measured by William probe. The biotype was also relatively thick.

**Case 2**

A 24 year male patient, with carious right central incisor, involving the distal, buccal and disto-palatal aspect, leaving very less tooth structure available for placement of restoration margins. The sulcus depth was 2mm on buccal, distal and palatal aspect with sufficient width of keratinized tissue.

**Case 3**

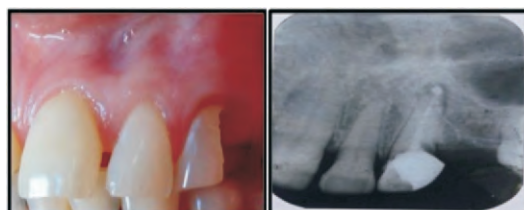
This case was of a 22 years old patient with Ellie's class III fracture of upper right central incisor. A sulcus depth of 3mm on all aspects with thick and adequate keratinized tissues was seen on examination. A post and core was planned for restoration of crown. Gingivectomy was again required for the exposure of tooth structure, on all aspects for placement of margins without violating the biological width. Radiographic examination showed the osseous crest close to CEJ. The crown to root ratio was favourable.

After discussion with the restorative operator, surgical crown lengthening with osseous reduction was planned for the first two cases and gingivectomy was planned for the last case.

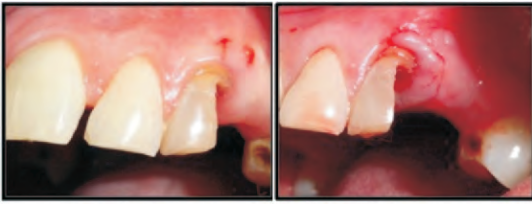
**Treatment**

**Case 1:** The apical extent of gingival excision

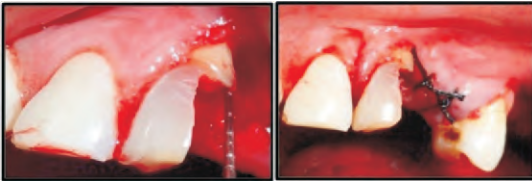
was marked by bleeding points on the outer surface of the gingiva with the periodontal probe. The initial internal bevel incision was carried out in a scalloped manner. The thinning of the flap was done with the initial incision because it is easier to accomplish that at this time, than later with a loose reflected flap, which is difficult to manage. This initial incision was blended with a crestal incision given in the adjacent edentulous space and a second or crevicular incision made from the bottom of the sulcus to the bone to detach the connective tissue from the bone. The sulcus lining was then removed with the help of curette and the flap was reflected with a periosteal elevator (blunt dissection). The granulation tissue was also removed with a curette. Intra-surgical measurement was done from the newly created margin to the bone. As it was less than 3mm, osseous resection was performed by the use of rotary handpiece with carbide burs under copious irrigation. It was ensured that 3mm distance between the new gingival margin and the alveolar crest was maintained all over, so as, not to violate the biological width. Finally, the flap was sutured at the crest level, with 3-0 silk suture and periodontal dressing was given. The patient was given postoperative instructions and was asked to come after one week for suture removal. Final preparation (post and core) was done after eight weeks and the restoration margins were placed adequately in relation to the new gingival sulcus. (Figure 1-4)



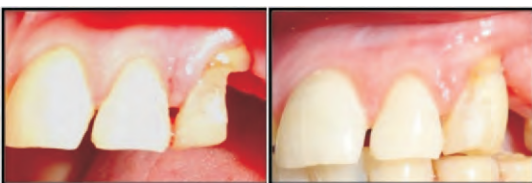**Figure 1. :** Preoperative view of canine with inadequate tooth structure for restoration



**Figure 2 :** Bleeding points marked followed by initial incision



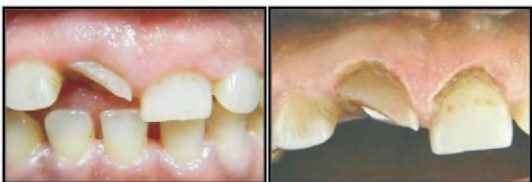**Figure 3 :** Intra-surgical measurement and sutured flap



**Figure 4 :** Postoperative view with post and core build up

**Case 2:** An internal bevel gingivectomy was performed as described above followed by restoration of the crown.

**Case 3:** In this case as there was sufficient sulcus depth and there were short clinical crowns a gingivectomy with gingivoplasty was performed with an electrocautery. This was followed by temporization immediately and a final restoration after 8 weeks. (Figure 5)



**Figure 5 :** Fractured incisor treated by gingivectomy

**Discussion**

The preservation of a healthy periodontium is critical for the long term success of the restored tooth.<sup>6</sup> The health of the periodontal tissues is dependent on properly designed

restorative margins. Although, supra-gingival restorative margins are preferred, sub-gingival margin placement is often unavoidable. Supragingival placement allows for ease of impression making<sup>7</sup>, cleansing, detection of secondary caries and is associated with maintainable probing depths and healthy soft tissue.<sup>8</sup> However in cases of extensive caries, fractured tooth, inadequate crown lengths and increased esthetic demands the restorative margins have to be placed at or apical to the gingival margin. This results in deleterious effects on the periodontium, leading to inflammatory response and attachment loss especially when they encroach on the junctional epithelium and supracrestal connective tissue.<sup>9</sup> If restorative margins need to be placed near the alveolar crest, crown-lengthening surgery or orthodontic extrusion should be considered to provide adequate tooth structure while simultaneously assuring the integrity of the biologic width. Surgical crown lengthening is a useful procedure to provide tooth length for proper restoration of a tooth without compromising the periodontium or the retentive qualities of the restoration.<sup>6</sup>

The clinical examination revealed two carious teeth in first two cases and a fractured incisor in last case with reduced dimension for restorative margins. An internal bevel gingivectomy was performed in the first two cases with osseous resection. The initial incision accomplishes three important objectives: 1) it removes the pocket lining; 2) it conserves the relatively uninvolved outer surface of the gingiva, which, if apically positioned, becomes attached gingiva; and 3) it produces a sharp, thin flap margin for adaptation to the bone-tooth junction.<sup>10</sup>

The basic concept of crown lengthening for

restorative ease is to surgically move the bone crest to a more apical position, providing for sufficient coronal tooth structure for restoration, while allowing space for re-establishment of a new physiologic dentogingival dimension (biologic width).<sup>11</sup> The term biologic width is used to describe the junctional epithelium and connective tissue that attach to the root surface. Studies have indicated that the average lengths of the connective tissue attachment and junctional epithelium are 1.07 and 0.97 mm, respectively. Therefore the average length of the biologic width is about 2.04mm. The healthy gingival sulcus coronal to the junctional epithelium, which is not attached to the tooth surface, has an average depth of 0.69 mm.<sup>12</sup>

In contemporary practice, it generally is accepted that a 3-mm distance would significantly reduce the risk of periodontal attachment loss induced by subgingival restorative margins. Placing the restoration in close proximity to the osseous crest has been demonstrated in a human clinical study to induce chronic inflammation.<sup>13</sup> Moreover, results from an animal investigation involving histologic evaluation indicated that restorative margins impinging on the osseous crest may result in bone resorption and pocket formation.<sup>14</sup> A distance of at least 3 mm was maintained between the most apical extension of the restoration margin and the alveolar bone crest. This space allows sufficient room for the supracrestal collagen fibers that are part of the periodontal support mechanism, as well as providing a gingival crevice of 2 to 3 mm. If this guideline is used, the margin of the crown is finally positioned at its correct level, approximately halfway down the gingival crevice.<sup>15</sup>

The gingivectomy procedure was performed

in the last case without reflection of flap and osseous resection procedure due to sufficient keratinized tissue and normal osseous crest relationship to CEJ. This procedure exposed more of the clinical crown and improved the appearance.

The final prosthesis was placed after a period of 8 weeks. Refinement of the tooth preparation should be performed 4 weeks later (8 to 10 weeks after the surgical procedure) as this will enable the proper placement of the margin of the restoration in relation to the new gingival sulcus.<sup>3</sup> Depending on the esthetic needs, the margin can be placed at the gingival crest or 0.5 mm into the healthy gingival sulcus. It does not have to be placed at the same level all around the tooth; a combination of supragingival, crestal and intracrevicular margins can be placed around the same tooth.<sup>16</sup>

### **Conclusion**

Crown-lengthening is a viable option for facilitating restorative therapy or improving esthetic appearance. Surgical crown lengthening procedure with lowering of bone level is an effective technique that can be used to increase the height of clinical crowns in cases with reduced clinical crown heights for reestablishment of biologic width for placement of restorative margins.

### **References**

1. Glossary of periodontal terms, the American Academy of Periodontology. 4th ed. Chicago, 2001.
2. Cohen DW. Crown Lengthening. In: Cohen ES editor. Atlas of cosmetic and reconstructive periodontal surgery. 3<sup>rd</sup> ed. BC Decker Inc;2007:249.
3. Bensimon GC. Surgical crown lengthening procedure to enhance esthetics. *Int J Periodontics Restorative Dent* 1999;19:333-41.
4. Willey RL. Retention in the preparation of teeth for cast restorations. *J Prosthet Dent* 1976;35:526.

5. Burch J. Ten rules for developing crown contours in restorations. *Dent Clin North Am* 1971;15:611-8.
6. Lanning SK, Waldrop TC, Gunsolley JC, Maynard JG. Surgical crown lengthening: Evaluation of the biologic width. *J Periodontol* 2003;74:468-74.
7. Silness J. Periodontal conditions in patients treated with dental bridges. II. The influence of full and partial crowns on plaque accumulation, development of gingivitis and pocket formation. *J Periodont Res* 1970;5:219-24.
8. Bader JD, Rozier RG, McFall WT, Ramsey DL. Effect of crown margins on periodontal condition in regularly attending patients. *J Prosthet Dent* 1991;65:75-9.
9. Newcomb G. The relationship between the location of subgingival crown margins and gingival inflammation. *J Periodontol* 1974;45:151-4.
10. Takaie HH, Carranza FA. The periodontal flap. In: Newman MG, Takei H, Klokkevold PR, Carranza FA. *Carranza's Clinical Periodontology*. 10<sup>th</sup> ed. Missouri. Saunders 2006;926-36.
11. Camargo PM, Melnick PR, Camargo LM. Clinical Crown Lengthening in the Esthetic Zone. *CDA Journal* 2007;35(7):487-98.
12. Gargiulo A, Wentz F, Orban B: Dimensions and relations of the dentogingival junction in humans. *J Periodontol* 1961; 32:261.
13. Günay H, Seeger A, Tschernitschek H, Geurtsen W. Placement of the preparation line and periodontal health: a prospective 2-year clinical study. *Int J Periodontics Restorative Dent* 2000;20(2):171-81.
14. Parma-Benfenali S, Fugazzoto PA, Ruben MP. The effect of restorative margins on the postsurgical development and nature of the periodontium: part I. *Int J Periodontics Restorative Dent* 1985;5(6):30-51.
15. Spear FM, Cooney JP. Restorative Interrelationships. In: Newman MG, Takei H, Klokkevold PR, Carranza FA. *Carranza's Clinical Periodontology*. 10<sup>th</sup> ed. Missouri. Saunders 2006;1050-69.
16. DeWaal H, Castellucci G. The importance of restorative margin placement to the biologic width and periodontal health. Part I. *Int J Periodontics Restorative Dent* 1993;13:461-71.