

Surgical And Orthodontic Treatment Of Skeletal Class III, Long Face Syndrome

Batra P¹, Sadhu P², Srivastava M³

Abstract

Class III malocclusion associated with skeletal anterior open bite pattern in adults can be a challenging orthodontic problem, especially if treated nonsurgically. Conventionally, several treatment alternatives are available such as tooth extraction, molar intrusion, and absolute anchorage system or orthognathic surgical correction. A correction with surgery may be the most effective and stable way. The article presents a case report of a 20 years old unilateral cleft lip and palate patient with skeletal Class III and long face syndrome (severe anterior open bite) treated by orthodontic compensation (lower first premolars extraction) followed by vertical reduction genioplasty. Post treatment the patient obtained satisfactory occlusion as well as functional results with correction of severe anterior open bite and reverse overjet.

Key words: Class III Malocclusion, Open Bite, Orthodontic Treatment, Genioplasty.

Introduction

Class III malocclusion is considered to be one of the most difficult and complex orthodontic problems to treat. Individuals with class III malocclusion frequently show combinations of skeletal and dent alveolar components. Skeletal class III malocclusion may either be associated with maxillary retrusions, mandibular protrusion, or a combination of the two^{1, 2}. These complex cases require careful treatment planning, an integrated approach and patient cooperation². A poor facial appearance is often the patient's chief complaint, but it may be accompanied by functional problems, temporomandibular disorders, or psychosocial handicaps³.

Several distinct cephalometric features have been reported in class III patients, such as a short anterior cranial base length, acute

cranial base angle, a short and retrusive maxilla, proclined maxillary incisors, retroclined mandibular incisors, an excessive lower anterior face height and obtuse gonial angle.

An important aspect of comprehensive orthodontic therapy is managing the vertical dimension of the patient's face. Many of the most difficult orthodontic cases involve long face syndrome. A "long face" is characterized by an excessively vertical face, also referred to as long face pattern,^{4,5} "long face syndrome",⁶ and hyper divergent facial type.⁷ Characteristics include excessive eruption of posterior teeth, normal or excessive eruption of anterior teeth, short posterior facial height, and a steep mandibular plane angle⁷. Facial syndromes related to excessive vertical dimension, such as Class III malocclusion

Corresponding Author : Dr Mudita Srivastava, Senior Lecturer Department of Orthodontics and Dentofacial Orthopaedics IDST, Modinagar.U.P (M) 09910930544 Email-mudi2007@rediffmail.com

1. Prof & Head, Department of Orthodontics IDST, Modinagar,U.P

2. Director, Department of Plastic Surgery Global Hospital Mount Abu, Rajasthan, India.

3. Senior Lecturer, Department of Orthodontics and Dentofacial Orthopaedics IDST, Modinagar.U.P

with long-face syndrome, can be treated by means of surgical manipulation of the jaws, thereby improving the skeletal-dental relationship and resulting in a more aesthetic proportion. Extraction mechanics with orthodontic compensation is also frequently used for correction of anterior open bite with large vertical dimension.

The article presents and discusses the treatment of a case of unilateral cleft skeletal class III malocclusion with long face syndrome treated by combination of orthodontic compensation and reduction genioplasty.

Case Report

A 20 years old male UCLP (left side) patient reported with a chief complaint of poor facial aesthetics, with difficulty in closing lips, mastication and chewing. The lip was operated at six months of age and palate at 2 years of age. There was no previous history of orthodontic treatment. He denied ever having had any temporomandibular joint dysfunction signs or symptoms, and maximal opening and lateral and anterior movements were within normal limits. Also there were no deviations on opening and closure, and no joint sounds

On extraoral examination (Fig:1) face appeared symmetrical and elongated, unilateral scar noted on left side of upper lip. Patient had concave profile with prominent chin and retrusive middle third of face, upper lip was retrusive and protrusive lower lip with increase in lower anterior face height and high clinical FMA. There was excessive contraction of mentalis muscle during closing of lips at rest (lip sealing). On intraoral examination (Fig: 2) all compliment of teeth were erupted in mouth except for third molars. Upper lateral incisors were missing bilaterally. Presence of complete open bite of

6-7mm extending from second molar bilaterally. Patient presented with Class III molar and canine relation bilaterally with reverse overjet of 4 to 5mm. Maxillary arch was severely constricted “v” shaped while mandibular arch was wide and squarish. Scar tissue on upper lip and fistula in palatal area was also noticed. Moderate crowding present in upper and lower anteriors with mesially tipped lower canines. There was tongue thrusting habit which was secondary to complete open bite.

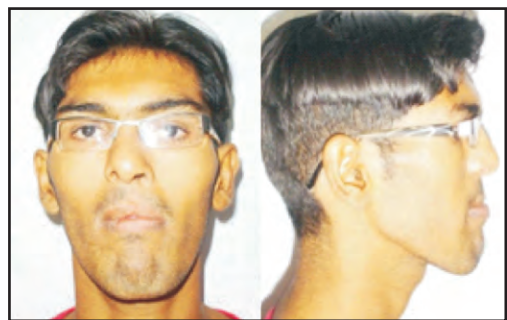

Figure 1 : Pre Treatment Extraoral

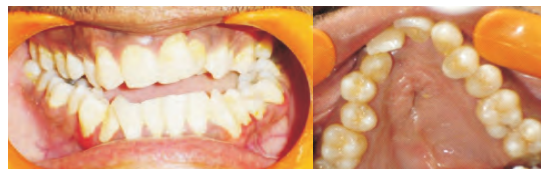

Figure 2 : Pre Treatment Intraoral

Radio graphical examination using a lateral cephalogram and OPG was done. On doing the cephalometric analysis (Fig:3) it was found that the patient had skeletal Class III malocclusion because of retrognathic maxilla and prognathic mandible with prominent chin. Mandibular basal length was also increased with short ramal height. There is steep mandibular plane and gonial angle with severe increase in lower anterior facial height (LAFH). Sassouni's skeletal analysis revealed that the palatal, oclussal and mandibular plane are divergent. There was increase in posterior

maxillary height in vertical plane along with supra eruption of maxillary and mandibular second molars resulting in downward and backward rotation of mandible. Dentally, there was proclination of lower anteriors with normal angulation of upper anteriors with respect to SN plane. OPG Examination revealed all compliment of teeth (except upper lateral incisors) with vertically impacted maxillary and horizontally impacted mandibular third molars. The condyles appeared normal in size and form.

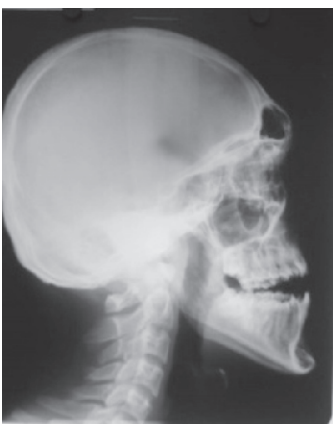

Figure 3 : Pre Treatment Lateral Cephalogram

The case was diagnosed as a case of skeletal Class III malocclusion with downward and backward rotation of mandible resulting in skeletal open bite.

It was decided to treat the case in combination of orthodontic and surgical treatment. Orthodontically, it was decided to extract lower first premolars followed by vertical reduction genioplasty.

Fixed orthodontic appliance was placed (022 slots MBT mechanics) in patient s mouth from second molar bilaterally in both upper and lower arch.

Lower first premolars were extracted and the extraction space was utilized to relieve the mild lower anterior crowding and, retracting the lower anteriors. Upper arch was expanded

along with coordination of lower arch. The severe open bite was corrected by intrusion of upper and lower molars along with supra eruption of upper and lower anterior teeth thereby rotating the occlusal plane anti clockwise.(Fig:4,)

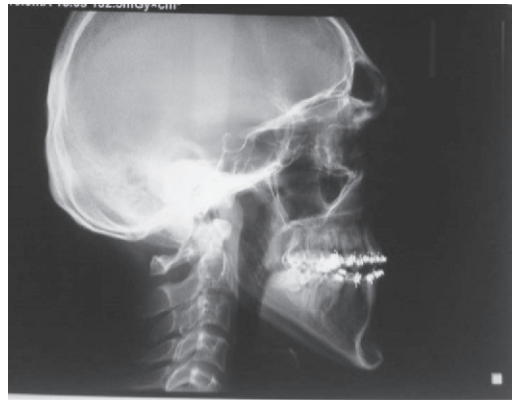

Figure 4 : Mid Treatment Lateral Cephalogram

Vertical reduction genioplasty was performed for reducing the anterior facial height and the chin prominence, after the orthodontic treatment. This combine orthodontic and surgical treatment resulted in giving the patient an acceptable and stable occlusion and facial aesthetics. (Fig: 5)

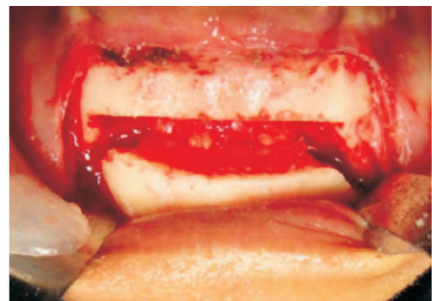


Figure 5 : Genioplasty



Figure 6 : Post Treatment Extraoral

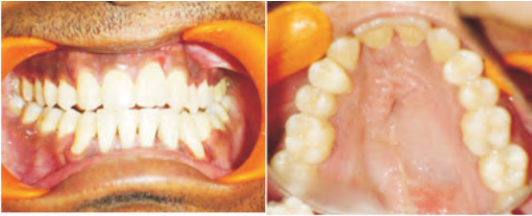

Figure 7 : Post Treatment Intraoral

Discussion

Skeletal Class III malocclusion is one of the most common finding in patient having history of cleft lip and palate. This is because surgical scar tissue which is formed at the time of repair of palate retards the growth of nasomaxillary complex, if the palatal surgery is done before completion of growth.

In the present case, patient presented with retruded premaxillary segment and prognathic mandible and prominent chin. The present malocclusion was complicated with complete open bite and downward and backward rotation of mandible having increased lower anterior facial height. Surgical reduction of facial height and proper alignment of the teeth by orthodontic means are common denominators of successful treatment of this kind of situation. As the patient was non growing adult, there are many other possible treatment options for the present scenario like maxillary impaction with maxillary advancement causing forward autorotation of mandible with or without mandibular setback, Mandibular setback with vertical reduction genioplasty or just orthodontic compensation of the case by proclining the upper anteriors and retroclination of lower anterior by first premolar extraction in lower arch along with vertical reduction.

Maxillary impaction and advancement are major surgical procedures; moreover in this case as there was no vertical maxillary excess, downward and backward rotation of mandible

was because of wedge effect created by extrusion of second molars resulting in severe open bite. As the patient had long lower anterior facial height, maxillary impaction and advancement with or without mandibular setback would have not addressed this situation.

Only surgical treatment of mandibular setback or reduction genioplasty or only orthodontic compensation of the malocclusion was not justified as patient presented with severe skeletal open bite and retrusive premaxillary segment and skeletal class III malocclusion.

The present case was treated by orthodontic and surgical means both. Orthodontic ally the lower second premolars were extracted and lower anteriors were retracted in the extraction space and moderate crowding in the lower arch was relieved. Most of the non-surgical approaches involve extractions, which are used in these patients not only to address the typical indications--crowding, incisor flaring, and bimaxillary protrusion- but also to allow forward movement of the posterior teeth (burning anchorage), thus closing the maxillomandibular angle and reducing anterior facial height.

In upper arch, anteriors were proclined there by compensating the retruded premaxillary segment. As the patient was skeletal Class III and there was prominent chin, the vertical reduction genioplasty was justifiable to reduce the prominent chin and increased lower anterior facial height.

Vertical Genioplasty is the adjunctive surgical procedure used in treatment of long face syndrome with skeletal Class III malocclusion. Most genioplasty procedures are done to improve the mandibular profile in order to obtain a more natural profile. Genioplasty can shorten or lengthen the lower

third of the face like in the present case it helped in reduction of facial height and chin prominence. Facial asymmetry may also be corrected by rotation of the chin-point to coincide with the midline. The advantages genioplasty are versatility, reliability and consistency in correcting problems in the sagittal and vertical planes to achieve adequate chin projection.

Post treatment patient achieved acceptable facial and smile aesthetics with good functional correction.(Fig:6,7)

Conclusion

Treatment of skeletal Class III malocclusion along with long face syndrome remains a challenge to clinicians. Careful diagnosis and appropriate treatment approach whether nonsurgical, surgical or combination of orthodontic treatment and surgical should be analyzed. The one of the treatment approach that is orthodontic compensation followed by vertical reduction genioplasty is highlighted through this article. The approach of treatment presented has practical clinical relevance.

References

1. Vig KD, Ellis E., 3rd Diagnosis and treatment planning for the surgical orthodontic patient. *Dent Clin North Am.* 1990; 34:361–84.
2. Proffit WR. Psychosocial aspects of dentofacial deformity and its treatment. In: Proffit WR, White RP Jr, Sarver DM, editors. *Contemporary Treatment of Dentofacial Deformity.* St. Louis: Mosby;
3. Bailey LJ, Sarver DM, Turvey TA, Proffit WR. In: *Contemporary Treatment of Dentofacial Deformity.* Proffit WR, White RP Jr, Sarver DM, editors. St. Louis: Mosby; 2003. p. 507
4. Cardoso MA, Bertoz FA, Capelloza L Filho, Reis SAB. Características cefalométricas do Padrão Face Longa. *Rev Dental Press Ortodon Ortop Facial.* 2005 mar-apr; 10(2):29-42.
5. Cardoso MA, Bertoz FA, Reis SAB, Capelloza L Filho. Estudo das características oclusais em portadores de padrão face longa com indicação de tratamento ortodôntico-cirúrgico. *Rev Dental Press Ortod Ortop Maxilar.* 2002 nov-dec;7(6):63-70.
6. Fitzpatrick BN. The long face and V.M.E. *Aust Orthod J.* 1984 Mar;8(3):82-9.
7. Houston WJ. The analysis of errors in orthodontic measurements. *Am J Orthod.* 1983 May;83(5):382-90.