

Customised Ocular Prosthesis: A Case Report

Gupta S¹, Bhargava A², Sehgal M³, Gupta RK⁴

Abstract

It's a god given right of every human being to appear human. After enucleation, evisceration and exenteration of the eye, the goal is to replace the missing tissues with an artificial prosthesis and restore the facial symmetry and normal appearance of the anophthalmic patient. Therefore the combined efforts of the ophthalmologist, the plastic surgeon, and the maxillofacial Prosthodontist are essential in order to restore the patient's quality of life. Custom made prostheses provide more esthetic and precise result as compared to stock eye prosthesis. Simplification of the technique with the commonly available materials makes it easier. This case report describes the fabrication of eye prosthesis in a cost effective manner with a unique fabrication technique.

Keywords : Ocular Prosthesis, Anophthalmic Patient, Congenital Defect Iris Painting.

Introduction

A congenital defect, pathology or accidental trauma may necessitate surgical intervention, which can lead to removal of the eye ball¹. Ocular disfigurement can cause significant physical and emotional disturbances². The combined efforts of the ophthalmologist and the maxillofacial prosthodontist are required to provide a satisfactory ocular prosthesis, which can restore the patient's quality of life.

Various literature reports advocate the use of the stock eye for ocular replacement although it is well documented that customised prostheses offer excellent esthetics.^{3,4} The custom-made ocular prosthesis has improved aesthetics only when the iris colour is perfectly matched with the fellow eye. A properly planned and customized ocular prosthesis maintains its orientation, when patient performs various movements. Exact

color match of the iris and sclera with the adjacent eye can be achieved.^{5,6} In the technique described in this article, a perforated acrylic resin tray reinforced with disposable syringe is used. The anatomy of the enucleated socket and overlying tissues is obtained with greater detail with proper tissue contours. Thus the prosthesis obtained will have closed adaptation to the tissues, simulating natural mobility of the eye ball.

The following clinical report demonstrates a custom-made ocular prosthesis with a special emphasis on iris painting to create aesthetically pleasing results.

Clinical Report

A 65-year-old male patient complaining of a missing left eye was referred to the Department of Maxillofacial Prosthodontics I.T.S-CDSR Muradnagar, Ghaziabad. The enucleation had been carried out 12 years ago

Corresponding Author : Dr. Sharad Gupta, Professor, Dept. of prosthodontics, I.T.S Centre for Dental Studies & Research, Delhi Meerut Road, Muradnagar-201206, Ghaziabad (Uttar Pradesh) (M) +91-9873435895 E mail: sharadssv@gmail.com

1. Professor, I.T.S Centre for Dental Studies & Research, Delhi Meerut Road, Muradnagar-201206, Ghaziabad (Uttar Pradesh)

2. Professor & Head, I.T.S Centre for Dental Studies & Research, Delhi Meerut Road, Muradnagar-201206, Ghaziabad (Uttar Pradesh)

3. P.G Student, I.T.S Centre for Dental Studies & Research, Delhi Meerut Road, Muradnagar-201206, Ghaziabad (Uttar Pradesh)

4. Sr. Lecturer, I.T.S Centre for Dental Studies & Research, Delhi Meerut Road, Muradnagar-201206, Ghaziabad (Uttar Pradesh)

following a thorn prick and subsequent infection. On examination of the defective eye socket it was found that patient had a defect with a shrunken orbit and intact tissue bed. (Figure 1)

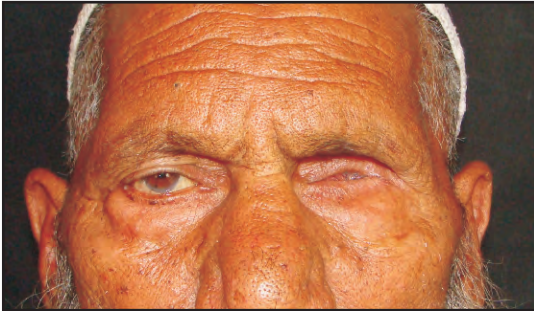

Figure 1 : Preoperative

Treatment

An impression of the anophthalmic socket was made with irreversible hydrocolloid (Zelgan 2002, DENTSPLY) mixed in thin consistency, which was injected into the socket through the hollow stem of the plastic impression tray. The impression was then poured in sections using dental stone (Kalastone, Kalabhai Pvt. Ltd, Mumbai, India). After complete setting the two halves of the cast were separated and a special tray with clear acrylic having hollow passage was fabricated. The patient's eye socket was coated with a thin layer of Vaseline and an impression was made using light viscosity polyvinyl siloxane impression material (Aquasil LV, DENTSPLY) (Figure 2). Patient was asked to do various movements to record all anatomical details of the socket.

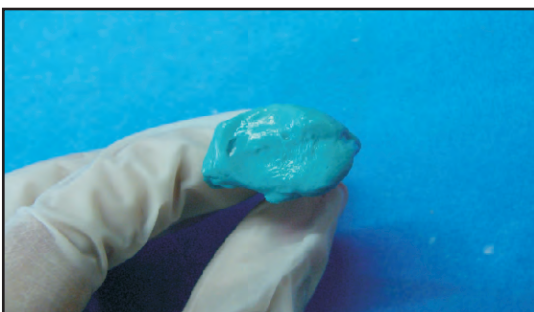

Figure 2 : Final impression of anophthalmic socket

Soft putty consistency polyvinyl siloxane (Aquasil soft putty/regular DENTSPLY) set was wrapped around the final impression to obtain a mould for wax pattern fabrication. Then putty was separated horizontally into two halves. The mould space was ready for wax pattern fabrication into which molten white wax (Surana dental wax Mangalore Dent Corp) was poured through the channel formed by tray handle (Figure 3). When the wax had set the putty mould was separated and the wax pattern was retrieved and carved.

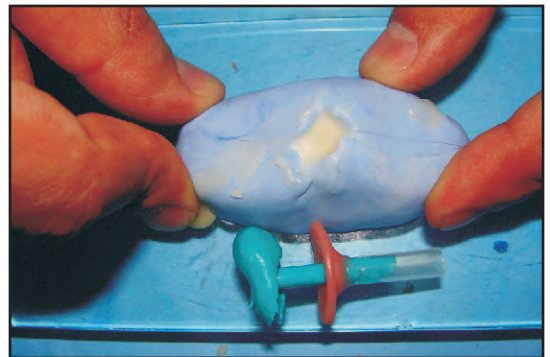

Figure 3 : Putty mould for wax pattern fabrication.

Wax pattern trial

Fullness of the defect was checked along with the extensions. This was confirmed by asking the patient to perform various movements and patient was inspected from the frontal view. The prefabricated black iris disc with handle was positioned maintaining the symmetry with the iris of the adjacent unaffected right natural eye of the patient.

Flasking

After trial wax pattern was sealed on the cast and the whole assembly was invested in special small aluminium flask (Figure 4). After dewaxing the mould was packed with tooth coloured heat cure polymethylmethacrylate acrylic (PMMA). Shade selection was done for sclera as per the contralateral natural eye. After acrylization

conformer was retrieved and invested mould was preserved for final processing. Later 1.5mm of the acrylic was trimmed from the outer surface to create space for iris and scleral painting followed by processing of the definitive prosthesis with clear acrylic.

Iris and Scleral Painting

Iris painting was carried out to match the colour of the natural iris, using acrylic-based pigments (Acrylin, Camlin Ltd, Mumbai, India), including white, blue, black and brown. To begin with a brown and black mix was painted as the base colours. The stroma was then painted with a lighter intensity colour. Thin radial strokes were given to form the striations with the very fine brush point. A small area around the pupil was left forming the collarette and was painted slightly brighter than the base colour. Finally, the limbus was painted with a mix of light blue and white to simulate the light bluish haziness that was present on the inferior portion of the right iris. The black pupil was then painted. The painted iris disc was fixed with a special Monopoly Syrup solution which was formed with 10 parts of heat-cure acrylic monomer and 1 part of clear acrylic polymer⁷ and checked for accuracy against the natural eye and found to be well-matched (Figure 5). Appropriate shade of sclera acrylic resin that matched well with natural eye sclera was selected. Further characterization was done by extrinsic staining and attaching veins by using the red-coloured silk threads.

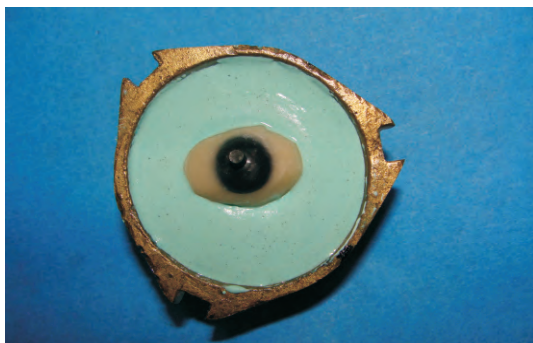


Figure -4 :Investment of wax trial

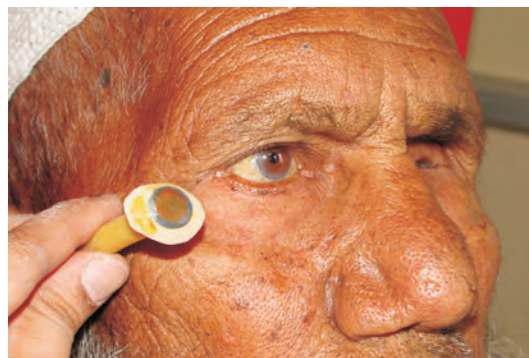

Figure -5 :Colour Match with Natural Eye

The prosthesis was finally cured with clear heat-polymerising acrylic (Ashwin Clear Heat Cure PMMA) resin. The prosthesis was finished, polished and placed in the eye socket. The colour match or the iris was excellent and the patient was satisfied with the outcome. Patient was taught insertion, removal and hygiene of the prosthesis. Follow-up evaluation was carried out once a week for the first month. At the time of the follow-up appointment, the prosthesis was working well and the patient had no problems (Figure 6).

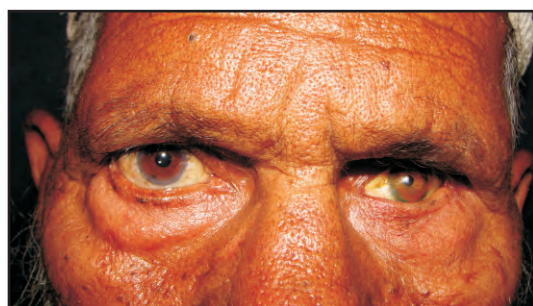

Figure 6 : Postoperative- Prosthesis in Situ

Discussion

A customized ocular prosthesis maintains its orientation when patient performs various movements. With the development of newer materials the socket can be finely recorded on which custom made ocular acrylic prosthesis (Sykes, 1996)⁸ can be fabricated with exact fit and esthetics although the prosthetic rehabilitation may be enhanced with the use of

implants.

Artopoulou et al.⁹ has presented a technique of replicating the patient's iris using digital photography. The photographs are adjusted using graphics software and the final image is printed on 20 lb white paper with brightness 87 using a laser printer. The suggested technique is reliable but the digital photography equipment and settings, computer software as well as the patient co-operation for the photographs is required as it is technique sensitive. Conversely, if the iris anatomy and colour science are studied, custom iris synthesis can be accomplished just with the help of a paint brush and colours.

Although the literature^{10,11} suggests modifying and characterising the sclera of stock eyes, it may not be possible to change the iris colour. The colour of stock eyes may blend with younger patients but may not match older patients. These patients may have a smattering of brown throughout the sclera and more in the area of limbus and conjunctiva because of deposition of hepatic by-products. The case reported had the characteristic light bluish tinge on the iris of the natural eye. Hence, it was more difficult to achieve exact matching with a stock eye, so we decided to customize our prosthesis in the present case report.

Summary

The use of custom-made ocular prosthesis has been a boon to the patients who cannot afford for the implant replacements. Also, as discussed above, the esthetic and functional outcome of the prosthesis are better than the stock ocular prosthesis. A hand-painted technique in the presence of the patient seems to gain credence in the long-term. This procedure may be more time-consuming and entails a trial and error approach, but the aesthetic and functional results justify the extra effort. Hence, custom-painting of the iris should be encouraged.

References

1. Raflo GT. Enucleation and evisceration. In: Tasman W, Jager E eds. *Duane's Clinical Ophthalmology*. vol 5, 2nd edn. Philadelphia, PA: Lippincott, 1995: 1–25.
2. Lubkin V, Sloan S. Enucleation and psychic trauma. *Adv Ophthalmic Plast Reconstr Surg* 1990; 8: 259–62.
3. Benson P. The fitting and fabrication of a custom resin artificial eye. *J Prosthet Dent* 1977; 38: 532–9.
4. Gordon B. The ancient origins of artificial eyes. In: *Annals of Medical History*, 3rd edn, Series. 2
5. Martin O, Clodious L. The history of artificial eyes. *Ann Plast Surg* 1979; 3: 168–70.
6. Murphey PI, Schlossberg L. Eye replacement by acrylic maxillofacial prosthesis. *US Nav Med Bull* 1944; 43: 1085.
7. Beumer J III, Zlotolow I: Restoration of facial defects: etiology, disability, and rehabilitation, in Beumer J III, Curtis TA, Firtell DN. *Maxillofacial rehabilitation: prosthodontic and surgical considerations*. St. Louis: Mosby; 1979:311-71.
8. Skyes ML. Custom made ocular prostheses. A clinical report. *J Prosthet Dent* 1996; 75: 1–3.
9. Artopoulou I, Montgomery CP, Wesley IP, Lemon CJ. Digital imaging in the fabrication of ocular prostheses. *J Prosthet Dent* 2006; 95: 227–30.
10. Allen L, Webster HE. Modified impression method of artificial eye fitting. *Am J Ophthalmol* 1969; 67: 189.
11. Taicher S, Steinberg HM, Tubiana I, Sela M. Modified stock-eye ocular prosthesis. *J Prosthet Dent* 1985; 54: 95–8.