

## Ultrasonography With Colour Power Doppler Of Radicular Cyst- A Case Report

Suma GN<sup>1</sup>, Bharat Modi<sup>2</sup>, Shivanand<sup>3</sup>, Bhuvana Vijay<sup>3</sup>, Rahul kukreja<sup>4</sup>

### Abstract:

Ultrasonography is dynamic & readily available technique that is particularly useful in the examination of superficial structures. Ultrasonography is non-invasive, rapid, painless, inexpensive & easily reproducible. To evaluate the efficacy of Ultrasonography compared to clinical diagnosis, radiography and histopathological findings in the diagnosis of maxillofacial swellings, we report a case of 25yr old female patient who presented with a swelling in the maxilla.

**Key Words:** Ultrasonography, power Doppler, Radicular cyst

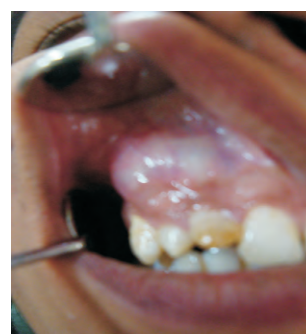### INTRODUCTION

For many years ultrasonography has played a major role as a diagnostic tool in various medical fields. Only recently it has been used for maxillofacial imaging<sup>1</sup>. It is non-invasive, rapid, painless, inexpensive and easily reproducible<sup>2</sup>. Ultrasonography is useful in measuring the size of the lesion precisely and along with colour power Doppler it is effective in determining the nature of a lesion whether it is cystic or solid, based on the amount of vascularisation present. This case report demonstrates the use of ultrasonography with colour power Doppler in maxillofacial swellings.

### CASE REPORT

A 25 year-old girl came to the Department of Oral Medicine and Radiology, ITS Dental College, Muradnagar, with a slow growing painless swelling in the anterior region of maxilla since 1-2years.

Extra oral examination showed a solitary diffuse swelling on right ala-tragal line of 1.5cm x 2cm in size causing obliteration of the nasolabial fold which was tender on palpation. Past medical, dental history and general physical examination were non contributory. On intra oral examination, a well defined solitary swelling present in the right upper labial vestibule extending anteriorly from the mesial aspect of 12 till mesial aspect of 13 posteriorly. It measured 2.8cm in size and was bluish in colour. On palpation it was soft, tense, firm to hard in consistency and non tender in nature.



**Fig.1.**  
*Preoperative picture of lesion.*

**Corresponding Author :** Dr Rahul Kukreja, Post Graduate Student, Department of Oral Medicine & Radiology, ITS Dental College, Muradnagar, Ghaziabad. Ph.No.: 09899788798 Email id: drrahulkukreja2088@gmail.com

1 Prof. & Head of Department of Oral Medicine & Radiology, ITS Dental College, Muradnagar, Ghaziabad.

2 Professor, Department of Oral Medicine & Radiology, ITS Dental College, Muradnagar, Ghaziabad.

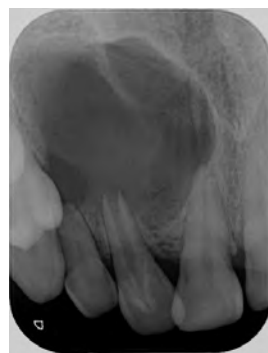3 Associate Professor, Department of Oral Medicine & Radiology, ITS Dental College, Muradnagar, Ghaziabad.

4 Post Graduate Student, Department of Oral Medicine & Radiology, ITS Dental College, Muradnagar, Ghaziabad.

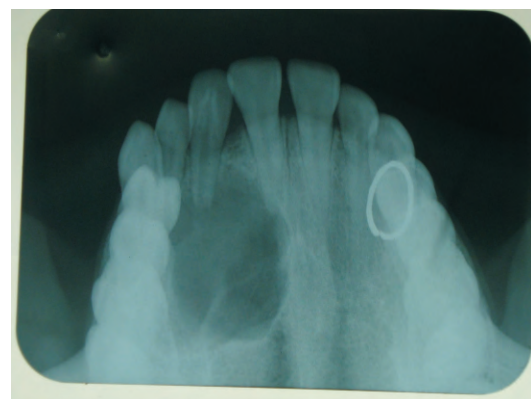
There was expansion of buccal cortical plate. The tooth i.e 12, was non-carious, non-mobile, non-tender. On the palatal side, an invagination of crown with deep palatal pit was observed. Also it was found to be non-vital when electric pulp test was performed. (Fig.1)

With the above history and clinical examination a provisional diagnosis of radicular cyst secondary to dens invaginatus with respect to 12 was made. Differential diagnoses included nasolabial cyst, cementoma, traumatic bone cyst.

Investigative workup included an intra oral periapical radiograph (IOPAR), maxillary occlusal and pantomography, fine needle aspiration and ultrasonography with colour power Doppler.

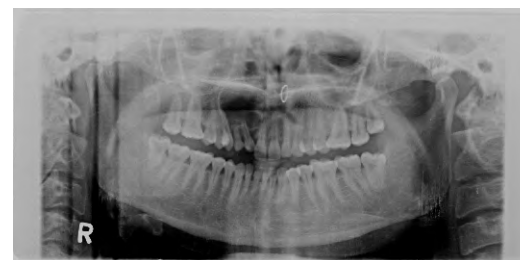

*Fig.2. Intraoral periapical radiograph well defined radiolucency with sclerotic border.*

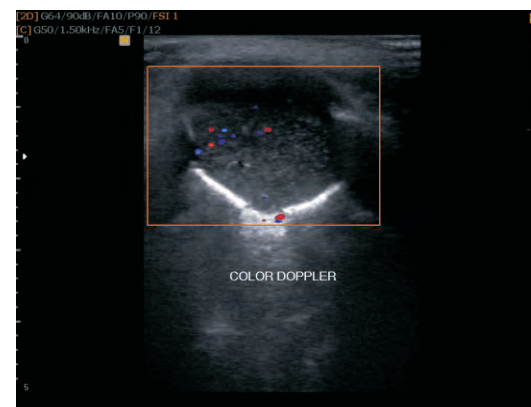

*Fig.3. Occlusal radiograph showing the well defined radiolucency w.r.t 12 & 13.*

IOPAR showed enamel invagination of crown lined by enamel upto the cemento-enamel junction suggestive of Type I dens invagination, with widened root canal with respect to 12. IOPAR, maxillary occlusal and pantomography, revealed well-defined round radiolucency involving the periapical area of 12 and 13 with sclerotic border of size 1.5x2cm. (Fig.2,3 and 4)



*Fig.4. OPG showing a radiolucent area extending from periapex of 11 till 13.*

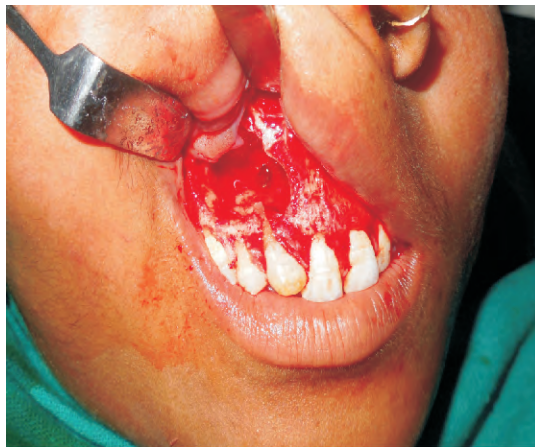

*Fig.5. Ultrasonography with colour power Doppler, showing the anechoic area with posterior wall enhancement with absence of vascularity suggestive of cystic lesion.*

Ultrasonography with colour power Doppler was performed (Fig.5). It revealed a well-defined round cystic lesion of 2.4x2.2cm in size with thin and smooth margins, posterior acoustic enhancement was present and vascularity was absent, which indicated that it was a cyst.

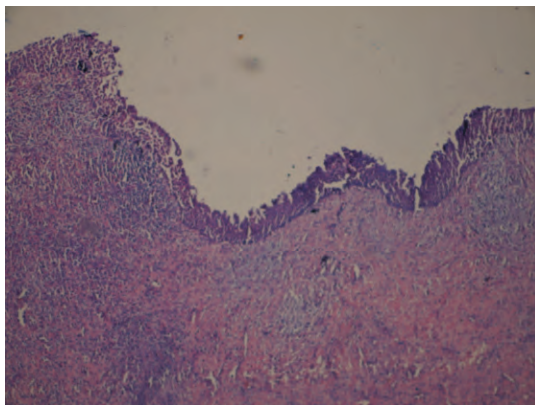
Fine needle aspiration was performed which revealed straw coloured aspirate. The total protein content of the aspirate was 8.05gm/dl.

The cystic site was then exposed under local anesthesia following root canal treatment of 12 (Fig.6).



*Fig.6. Postoperative picture of lesion*

The cyst was enucleated and was sent for histopathologic examination. The histopathological examination revealed a cystic cavity lined by parakeratinized epithelium with inflammatory cell infiltrates. Hence we confirmed our diagnosis of radicular cyst secondary to the dens invaginatus Type I (Fig.7).



*Fig.7. Histopathological picture showing parakeratinized stratified Squamous lining epithelium supported by connective tissue capsule suggestive of a radicular cyst.*

#### **DISCUSSION**

The various lesions manifesting in maxillofacial region have a different treatment

plan and thus it is necessary to have accurate information on the pathological nature of the lesion as stated by Peterson et al in 2003<sup>4</sup>. Radicular cyst develops from various etiologies like trauma, caries, non-vital tooth or dens invaginatus, like in our case. Dental invagination is a rare malformation with a widely varied morphology<sup>5</sup>. Radiographically, the affected tooth shows an infolding of the enamel and dentin that can extend to within the pulp cavity and root and sometimes to the root apex. Both the crowns and the roots of the teeth can show alterations in their size and form<sup>6</sup>. Although radicular cyst can be well appreciated radiographically but ultrasonography acts as an adjunct to the diagnosis.

Ultrasonography has over the past few years emerged as an important tool for a variety of applications in the field of medicine<sup>7</sup>, and has recently been introduced to dentistry. To corroborate this fact, this technology was used in the present case for the diagnosis of maxillofacial swellings. Cysts on ultrasound examination appear as anechoic because it is fluid filled which is homogenous. There is little or no attenuation of the sound as it passes through a cystic structure, which creates the appearance of enhanced transmission of the sound at the distal aspect of a cystic mass<sup>8</sup> though ultrasound waves do not pass through hard tissues like bone. Bhosale GR and associates<sup>9</sup> observed in their study that when bone expanded or resorbed upto a certain extent, as seen in various odontogenic cysts, it does carry the sound waves to the tissue beyond it.

Magnetic resonance imaging (MRI) and computed tomography (CT) are valuable diagnostic aids in imaging soft tissue lesions and the spread of infections into facial spaces;

but they are not readily available in many dental clinics, are expensive and time-consuming and CT exposes the patient to large doses of radiation<sup>10</sup>. Ultrasonography is quick, widely available, inexpensive, relatively painless, and can be repeated as often as necessary without risk to the patient<sup>11</sup>. A review article by Ramirez-Schrempp, et al<sup>12</sup>, stated “ultrasound is an efficient, non invasive diagnostic tool which can augment the physician's clinical examination. Ultrasound has been shown to be superior to clinical judgement alone in determining the presence or the absence of occult abscess formation, ensuring appropriate management, and limiting unnecessary invasive procedures”<sup>12</sup>. The best probe to use for the assessment of superficial structures, such as abscess or cellulitis, is a high-frequency linear probe (8-12 MHz or higher)<sup>12</sup>. In a study by Bassiony and co-authors<sup>11</sup>, the echogenicities of the ultrasound were described as hyperechoic (brighter), isoechoic (equal), hypoechoic (darker), anechoic (no internal echoes), or mixed as compared to the adjacent tissues<sup>11</sup>. Normal skin on an ultrasound has a very organized pattern where the dermis and epidermis appear as a single hyperechoic and bright layer relative to the subcutaneous tissue, which is hypoechoic<sup>12</sup>. The echogenicities described by Bassiony et al<sup>11</sup>. were the key in their staging of the infections from the acute phase to the complete abscess formation phase. The use of colour Doppler allows visualization of vascular structures so that they can be avoided during treatment of the swelling<sup>12</sup>.

#### **CONCLUSION**

Most of the practitioners are not aware of the utilities of ultrasonography and colour power Doppler for the diagnosis of various

maxillofacial lesions. The present case illustrates the usefulness of diagnostic ultrasound imaging in cystic jaw swellings and gives future hopes for its use in assessment of all maxillofacial swellings.

#### **REFERENCES**

1. Srinivas K, Sumanath KN, Chopra SS. Ultrasonography evaluation of inflammatory swellings of buccal space. *Indian J Dent Res*,20(4)2009:458-62.
2. Yoshida H, Akizuki H and Michi K. Intraoral Ultrasonic Scanning as a diagnostic Aid. *J. Cranio-Maxillo. Fac. Surg.*15 (1987)306-11.
3. Baatenburg de Jong RJ, Rongen RJ. Guidelines for the use of ultrasound in the head and neck. *ORL* 1993;55:309-12.
4. Peterson LJ, Ellis E, Hupp JR, Tucker MR. Contemporary oral and maxillofacial surgery. 4th ed. St. Louis: C.V. Mosby Co.; 2003, ISBN 0323-01887-4. p. 18.
5. McNamara CM, Garvey MT, Winter GB. Root abnormalities, talon cusp, dens invaginatus with reduced alveolar bone levels: Case report, *Int J Paediatr Dent* 1998;8:41-45.
6. Hulsmann M, Dens invaginatus: Aetiology, classification, prevalence, diagnosis and treatment considerations. *Int Endod J*1997;30:79-9Q.
7. Bagewadi SB, Guledgudda MV, Patil K. Ultrasonography of swellings in orofacial region. *JIAOMR* 2010; 22(1):18–26.
8. Wicks JD, Howe KS. Fundamental of Ultrasonography techniques(3rd ed). Chicago, Yearbook Medical Publishers, Inc, 1983.
9. Bhosale GR, Muthe KV, Shah A. Gray

- scale ultrasonography as a new diagnostic aid in oral and maxillofacial surgery. *Journal of Indian Dental Association* 1992;63:165-67.
10. Peleg M, Heyman Z, Ardekian L, Taicher S. The use of ultrasonography as a diagnostic tool for superficial fascial space infections. *J Oral Maxillofac Surg* 1998;56:1129-31.
11. Bassiony M, Yang J, Abdel-Monem T, Elmogy S, Elnagdy M. Exploration of ultrasonography in assessment of fascial space spread of odontogenic infections. *Oral Surg Oral Med Oral Pathol Oral Radiol Endod* 2009;107:861-69.
12. Ramirez-Schrempp D, Dorfman DH, Baker WE, Liteplo AS. Ultrasound soft-tissue applications in the pediatric emergency department: to drain or not to drain? *Pediatr Emerg Care* 2009;25:44-8.