

"See the Unseen - Building The True Cornerstone of Diagnosis!"

Upasana Sethi Ahuja¹, Siddharth Gupta², Samta Mittal³, Mayank Jain⁴, Priti Gupta⁴

Abstract

Hippocrates has rightly said, "The wise should consider that health is the greatest of human blessings" and Oro-dental Diagnosticians work on this similar principle as they are concerned not only with the diseases involving the oral and perioral structures but also the systemic diseases having oral manifestations. By adapting a systematic approach to medical history taking and with appropriate clinical investigations; oral medicine experts have a role in providing oral health for overall health. We report a case on similar grounds wherein a patient has reported for routine dental care and our expertise in clinical history recording and examination, proved instrumental in making the patient aware of systemic condition. A case of systemic sarcoidosis with pulmonary involvement diagnosed on the basis of distinct radiological, haematological and biopsy findings along with the review of literature concerning this disease is included.

Keywords

Diagnosis; Sarcoidosis; Investigations.

INTRODUCTION

Sarcoidosis (sarc meaning flesh, -oid, like, and -osis, process), also known as sarcoid, Besnier-Boeck disease or Besnier-Boeck-Schaumann disease.

It is a multisystem inflammatory disease of unknown etiology that predominantly affects the lungs and intrathoracic lymph nodes.¹ It is manifested by the presence of noncaseating granulomas (NCGs) in affected organ tissues. The cause of sarcoidosis is unknown. Efforts to identify a possible infectious etiology have been unsuccessful². Clinical sequelae results from the impact of non caseating granulomas on various organ tissues.

The prevalence and severity of sarcoidosis differs among various races, ethnicities, and geographic locations. Sarcoidosis occurs twice more frequently in females than in males and blacks are ten times more likely to be affected than whites. It may present at any age, but most cases reported are in the second to fourth decade. . When the disease develops in persons over the age of 40 years, it is often persistent and progressive.³ Although its incidence may be low, the disease remains hidden and often is misdiagnosed as tuberculosis.

Although oral involvement in sarcoidosis is rare, it may be the initial manifestation of the

Corresponding Author : Dr. Siddharth Gupta, Reader, Dept. Oral Medicine & Radiology, I.T.S. Dental College, Hospital & Research Centre, Greater Noida (U.P.)
Drsiddharthgupta13@gmail.com

¹ Upasana Sethi Ahuja, Reader, Department Of Oral Medicine & Radiology, I.T.S. Dental College, Hospital & Research Centre, Greater Noida, Uttar-Pradesh

² Siddharth Gupta, Reader, Department Of Oral Medicine & Radiology, I.T.S. Dental College, Hospital & Research Centre, Greater Noida, Uttar-Pradesh

³ Samta Mittal, Senior Lecturer, Department Of Oral Medicine & Radiology, I.T.S. Dental College, Hospital & Research Centre, Greater Noida, Uttar-Pradesh

⁴ Mayank Jain, Post Graduate Student, Department Of Oral Medicine & Radiology, I.T.S. Dental College, Hospital & Research Centre, Greater Noida, Uttar-Pradesh

disease in some patients, presenting as nonspecific painless, submucosal nodular growth or swelling. In some cases, ophthalmic involvement has also been reported as an initial sign in sarcoidosis. We hereby, present a case of a male patient who was examined for routine dental check up. A detailed medical history and a comprehensive examination in conjunction with judicious knowledge of investigations led to the diagnosis of sarcoidosis.

CASE REPORT

A thirty-five year old male patient had reported for routine dental check up. General examination revealed that the patient had redness in right eye since one week. The redness developed progressively in the right eye and was associated with heaviness and slight blurring of vision. (Figure 1)

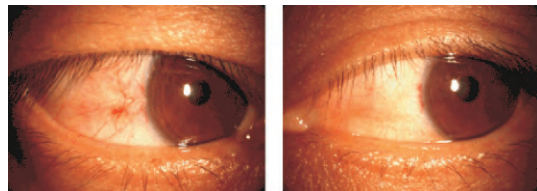


Figure 1: Redness of right eye

The patient also gave a positive history of non-productive cough present on and off since two years for which self medication was taken for symptomatic relief. Patient also gave history of loss of appetite and weight loss since two to three months.

Based on these findings a provisional diagnosis of tuberculosis was made.

X-Ray chest PA view was advised which revealed clear cardio-phrenic angles and lung fields and prominent hilar shadow with presence of bulge in the right suprahilar location. (Figure 2) Haematological investigations revealed raised ESR and negative tuberculin test. Ophthalmologic evaluation revealed the presence of anterior

uveitis in the right eye.

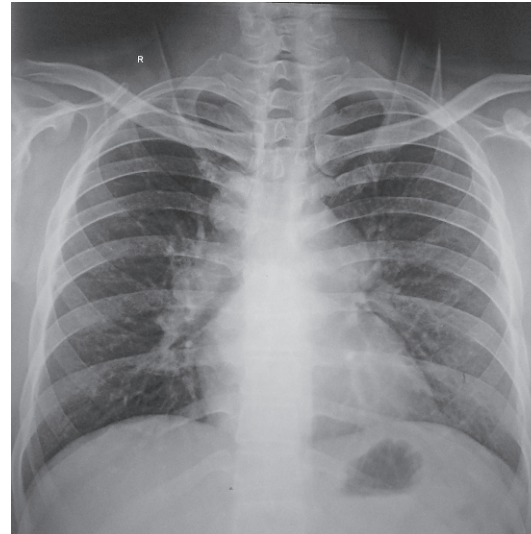


Figure 2: Chest X-ray PA View showing prominent hilar shadow with presence of bulge in the right suprahilar location

High resolution CT scan of chest with contrast revealed multiple discrete enlarged lymph nodes in the right paratracheal left para-aortic, subcarinal and hilar regions with normal trachea and both bronchi. (Figure 3)

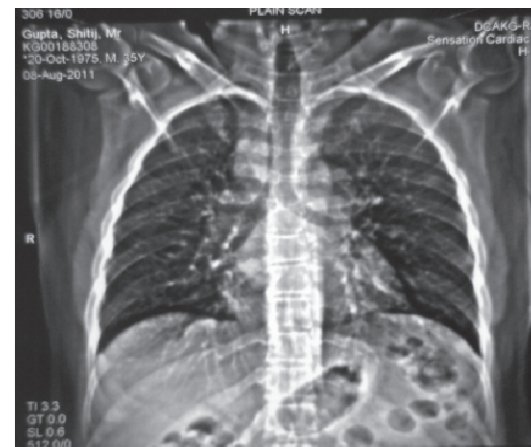

Figure 3: High resolution CT scan of chest with contrast showing multiple discrete enlarged lymph nodes in the right paratracheal left para-aortic, subcarinal and hilar regions

This led to the suspicion of sarcoidosis and patient was referred for pulmonologist's opinion where he was advised serum ACE levels and transbronchial node aspiration and

transbronchial lung biopsy.

Serum ACE levels were found to be raised. Transbronchial smears showed epitheloid cell granulomas, reactive lymphoid cells with predominant bronchial epithelial cells against haemorrhagic background conclusive of granulomatous lymphadenitis. The fragmented bit of biopsied specimen section comprising of stromal fragment and mural connective tissue showed few ill-organized granulomas (non-necrotizing) with modest lymphocytic infiltrate. (Figure 4)

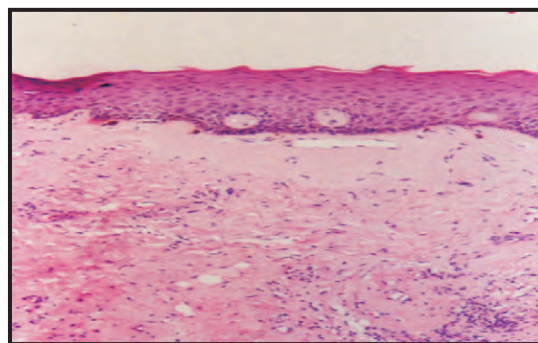


Figure 4: Smears showing epitheloid cell granulomas, reactive lymphoid cells conclusive of granulomatous lymphadenitis. Connective tissue stroma showing few ill-organized granulomas (non-necrotizing) with modest lymphocytic infiltrate.

Based on the clinical presentation, radiological findings, node aspiration and histopathology the diagnosis of sarcoidosis was suggested.

DISCUSSION :

Sarcoidosis is a relatively uncommon multisystem disease of unknown aetiology. Usually host and environmental factors are important in the development of the disease but such agents are yet to be identified that result in spatial, seasonal and occupational related cases.^{4,5} Moreover, current consensus documents that sarcoidosis is a Th1 disorder but the role of an external agent in the disease progression remains unanswered. In addition, oligoclonal expansion of T cells expressing

specific T-cell receptors has also been identified in sarcoidosis.⁶

Sarcoidosis is an antigen-driven disease but till date, neither organism nor specific external agent has been consistently implicated in pathogenesis and association. Sarcoidosis also seems to be characterized by genetic heterogenic behaviour, as a number of candidate genes have been identified that may influence disease susceptibility.⁷ Evidence of polymorphisms in various non- major histocompatibility (MHC) class II genes, including the genes that encode for TNF-alpha and angiotensin converting enzyme (ACE), influencing disease progression and severity have also been reported.^{8,9}

The signs and symptoms associated with the disease often wax and wane over time, with or without treatment. Non specific clinical findings including constitutional symptoms such as fever, malaise, arthralgia, and weight loss; ocular inflammation and visual changes; peripheral lymphadenopathy and hepatosplenomegaly have also been reported.¹

Rarely, neurologic deficits, seizures, recurrent syncope, or life-threatening arrhythmias may be the presenting sign of disease.² Cutaneous manifestations of sarcoidosis are identified in 33% to 50% of patients. In most cases, the skin findings are nonspecific and may present as erythema nodosum, scaling plaques, papules or nodules.¹

Oral involvement in sarcoidosis is rare. Although in some patients the oral lesions presenting as painless, submucosal nodular growth or swelling, may be the initial manifestations of the disease but are usually nonspecific. An unusual clinical variant of sarcoidosis known as Heerfordt's disease (uveoparotid fever) is characterized by parotid gland enlargement, fever, uveitis, and facial

palsy.^{10,11,12}

Additionally, sarcoidosis can arise in the lungs, major salivary glands and eyes. Lymph node involvement is also typical, with most patients exhibiting hilar or mediastinal nodal involvement. Sarcoidosis sometimes presents as a restrictive disease of the lungs, causing a decrease in lung volume and decreased compliance.

In our case patient presented with non-productive cough, weight loss, loss of appetite, anterior uveitis and enlargement of hilar lymph nodes.

Granulomatous inflammation are usually associated with a variety of conditions including foreign body reactions, infections like tuberculosis, leprosy, tertiary syphilis, Crohn's disease and orofacial granulomatosis.¹³⁻¹⁷

Sarcoidosis is often a diagnosis of exclusion as there are no specific tests that can accurately be used to diagnose the disease.¹⁵ A microscopic finding of non-necrotic granulomatous inflammation is necessary for sarcoidosis to be considered as a confirmatory diagnosis. Chest radiographs, pulmonary function tests and the use of CT scans are significant in identifying the pulmonary involvement of this particular multi-system disorder though the findings remain non-specific for sarcoidosis.¹⁸

On laboratory examination, thrombocytopenia, leucopenia, eosinophilia, and elevation of various serum markers, including calcium, alkaline phosphatase, and erythrocyte sedimentation rate have been identified in association with sarcoidosis.^{1,10}

Elevated serum ACE, IL-2 and IL-8 levels do seem to correlate with the disease activity and progression. Moreover, elevated levels of

macrophage inflammatory protein 1 and TNF- α , obtained from bronchoalveolar lavage, may also be associated with chronic and persistent disease.¹⁹ A higher proportion of CD4- positive T cells in bronchoalveolar lavage also has been identified in some patients, especially those with the acute form of the disease (Lofgren's syndrome-bilateral hilar lymphadenopathy).²⁰ Transoral open biopsy is not recommended prior to definitive treatment because of the risk of seeding the oral mucosa.

Corticosteroids, most commonly prednisolone, have been the standard treatment for many years. In some patients, this treatment can slow or reverse the course of the disease, but other patients do not respond to steroid therapy. The use of corticosteroids in mild disease is controversial because in many cases the disease remits spontaneously. Additionally, corticosteroids have many recognized dose- and duration-related side effects, and their use is generally limited to severe, progressive, or organ-threatening disease.²¹

Rarely, cyclophosphamide has also been used. As the granulomas are caused by collections of immune system cells, particularly T cells, there have been some early indications of success using immunosuppressants, interleukin-2 inhibitors or anti-tumour necrosis factor- α .⁸

Recently, medications aimed at neutralizing TNF α , including thalidomide, infliximab, and etanercept, have also been used to treat sarcoidosis. Nonetheless, thalidomide has been used successfully in a number of patients with marked mucocutaneous disease.²²

CONCLUSION :

A variety of systemic conditions may be

associated with granuloma formation in the body. For sarcoidosis, an extensive clinical, radiological, laboratory and microscopic evaluation is mandatory to identify the source of the granulomatous inflammation. Nevertheless, with prompt identification and appropriate understanding of early oral manifestations of a systemic disease, the oral physician plays an important role in the diagnosis and management of any such patient.

REFERENCES:

1. Baughman RP, Lower EE, Bois du RM. Sarcoidosis. *Lancet* 2003; 361(963):1111-8.
2. Thomas KW, Hunninghake GW. Sarcoidosis. *JAMA* 2003; 289(24):3300-3.
3. Rybicki BA, Kirkey KL, Major M, Maliarik MJ, Popovich J Jr, Chase GA, et al. Familial risk ratio of sarcoidosis in African-American sibs and parents. *Am J Epidemiol* 2001; 153(2):188-93.
4. Bois du RM, Goh N, McGrath D, Cullinan P. Is there a role for microorganisms in the pathogenesis of sarcoidosis? *J Intern Med* 2003; 253(1):4-17.
5. Ishige I, Usui Y, Takemura T, Eishi Y. Quantitative PCR of mycobacterial and propionibacterial DNA in lymph nodes of Japanese patients with sarcoidosis: *Lancet* 1999; 354(9173):120-3.
6. Moller DR. T-cell receptor genes in sarcoidosis. *Sarcoidosis Vasc Diffuse Lung Dis.* 1998; 15(2):158-64.
7. Rybicki BA, Iannuzzi MC, Frederick MM, Thompson BW, Rossman MD, Bresnitz EA, et al. Familial aggregation of sarcoidosis. A case-control etiologic study of sarcoidosis (ACCESS). *Am J Respir Crit Care Med* 2001; 164(11):2085-91.
8. Somoskovi A, Zissel G, Seitzer U, Gerdes J, Schlaak M, Muller-Quernheim J. Polymorphisms at position-308 in the promoter region of the TNF-alpha and in the first intron of the TNF-beta genes and spontaneous and lipopolysaccharide induced TNF-alpha release in sarcoidosis. *Cytokine* 1999; (11): 882-7.
9. Schurmann M. Angiotensin-converting enzyme gene polymorphisms in patients with pulmonary sarcoidosis. *Am J Pharmacogenomics* 2003; 3(4):233-43.
10. Blinder D, Yahatom R, Taicher S. Oral manifestations of sarcoidosis. *Oral Surg Oral Med Oral Pathol Oral Radiol Endod* 1997; 83(4):458-61.
11. Clayman L, MacLennan M, Dolan RL. Nonpainful swelling of the palate and loosening of the maxillary incisors. *J Oral Maxillofac Surg.* 1998 Nov; 56(11):1327-35.
12. Tarpley TM Jr, Anderson L, Light body P, Sheagren JN. Minor salivary gland involvement in sarcoidosis. Report of 3 cases with positive lip biopsies. *Oral Surg Oral Med Oral Pathol.* 1972; 35(5):755-62
13. Cotran RS, Kumar V, Collins T. Acute and chronic inflammation. In: Robbins pathologic basis of disease. 6th ed. Philadelphia: W.B.Saunders; 1999.83-4.
14. Neville BW, Damm DD, Allen CM, Bouquot JE. Oral and maxillofacial pathology. 2nd ed. Philadelphia: W.B.Saunders; 2002.292-7
15. Eveson JW. Granulomatous disorders of the oral mucosa. *Semin Diagn Pathol* 1996; 13(2):118-27
16. Rinaggio J. Tuberculosis. *Dent Clin North Am* 2001; 47(3):449-65.

17. Samaranayake P. Re-emergence of tuberculosis and its variants: implications for dentistry. *Int Dent J* 2002;52(5):330-6.
18. Faizan Alawi. Granulomatous diseases of the oral tissues: differential diagnosis and update. *Dent Clin North Am* 2005;49(1):203-21.
19. Shigehara K, Shijubo N, Ohmichi M, Takahashi R, Kon S, Okamura H et al, IL 12 and IL 18 are increased and stimulate IFN-gamma production in sarcoid lungs. *J Immunol* 2001; 166(1):642-9.
20. Capelli A, Di Stefano A, Lusuardi M, Gnemmi I, Donner CF. Increased macrophage inflammatory protein-1 alpha and macrophage inflammatory protein-1 beta levels in bronchoalveolar lavage fluid of patients affected by different stages of pulmonary sarcoidosis. *Am J Respir Crit Care Med* 2002; 165(2):236-41
21. Moller DR. Treatment of sarcoidosis-from a basic science point of view. *J Intern Med* 2003; 253(1):31-40.
22. Baughman RP, Judson MA, Teirstein AS, Moller DR, Lower EE. Thalidomide for chronic sarcoidosis. *Chest* 2002; 122(1):227-32.