

Management Of Complicated Crown-Root Fracture By Fragment Reattachment- A Review And Report of Two Cases

Shirazi Mutreja¹, Sumeet Setia², Mousumi Goswami³, Shahid Shaikh⁴

Abstract

Trauma to anterior teeth as a result of injury is commonly seen among school children, creating serious psychological, esthetic and functional problems. Reattachment of the fractured tooth fragment is an effective and efficient, conservative and economical procedure that restores the strength, function and esthetics close to that of an intact tooth. This report demonstrates the procedure of tooth fragment reattachment in two cases of complicated crown-root fracture. After six month follow-up both cases showed clinical and radiographic success.

Keywords : Fracture, Complicated crown-root fracture, Reattachment.

INTRODUCTION

Trauma to anterior teeth majorly has a psychological impact on the minds of young patients. It is therefore desirable that any treatment which does not compromise the esthetics, function and form should be considered the best. Fractures involving the crown and root include enamel, dentine and cementum and are classified as complicated or uncomplicated depending on the involvement of the pulp. Crown-root fractures affect 5% of permanent teeth and 2% of primary teeth.¹

Many treatment options have been explored for the treatment of such cases, like periodontal crown lengthening procedure to expose the fractured site and restoration with a prefabricated or custom made post and core followed by prosthodontic restoration, orthodontic extrusion of the tooth and forced surgical extrusion. Each of these procedures

have their own drawbacks.^{2,3} Reattachment of fractured incisor fragment as a treatment modality was first reported in 1964 by Chosack and Eidelman.⁴ Since then there have been many reports of such successful cases of reattachment with or without reflection of surgical flap. Andreasen FM et al⁵ made a detailed description of the clinical protocol when treating uncomplicated and complicated crown fractures by reattachment. Many clinical and experimental studies have shown that reconstruction of the fractured tooth with the fracture fragment has many advantages over other methods as it restores the esthetics to the greatest extent using the original shape, color, translucency and surface structure.⁶

CASE REPORT

CASE ONE

A 12 yr old boy reported to the Department Of Pedodontics and Preventive Dentistry I.T.S

Corresponding Author : Dr. Shirazi Mutreja, Senior lecturer, Deptt. of Pedodontics and Preventive Dentistry, I.T.S. Dental College, Hospital and Research Centre, Plot no 47, Knowledge Park III, Greater Noida. **Email:** shirazi82@yahoo.co.in (M) : 08826084656

1 Senior Lecturer, Department Of Pedodontics And Preventive Dentistry, I.T.S Dental College, Hospital And Research Centre, Greater Noida.

2 Professor, Department Of Pedodontics And Preventive Dentistry, I.T.S Dental College, Hospital And Research Centre, Greater Noida.

3 Prof & HOD, Department Of Pedodontics And Preventive Dentistry, I.T.S Dental College, Hospital And Research Centre, Greater Noida.

4 Post Graduate Student, Department Of Pedodontics And Preventive Dentistry, I.T.S Dental College, Hospital And Research Centre, Greater Noida.

Dental College and Hospital, Greater Noida, with complaint of injury to the upper front tooth two days back. Clinical examination showed a complicated crown-root fracture with the fracture line extending beyond the cervical line mesially and subgingivally in relation to 11. The fractured fragment showed grade III mobility. Radiographic examination revealed a complicated crown-root fracture with the fracture line extending into the cervical third of the root approximately 1mm above the alveolar bone. The tooth was also tender on vertical and horizontal percussion.

After determining the pros and cons of various treatment modalities it was decided to treat the involved tooth by root canal treatment and reattachment of the fractured tooth fragment. The fractured mobile tooth fragment was removed and placed in saline. Single sitting root canal treatment was done. One third of the gutta-percha from the cervical third was removed with the help of a bur (Fig 1) and a thin layer of glass ionomer cement (Universal Restorative GC Gold Label) was placed over it. The fractured fragment and the tooth were prepared for reattachment with a bur, the subgingival extension of the tooth and the fractured fragment were left untouched to guide in the reattachment procedure. The tooth structure and the fractured fragment were etched with 34% phosphoric acid gel (3M ESPE) for 15 seconds, washed and dried moist. Prime and Bond NT (Dentsply, USA) was then applied over the etched surfaces and cured for 20 seconds. The fractured fragment was then reattached with microfilled anterior composite (3M). The correct reattachment of the fragment was determined with the help of clinical judgment and an intraoral periapical radiograph (Fig 2). The rest of the access cavity was restored with composite and

composite veneering was done (Fig 3). The tooth was clinically and radiographically examined for the first two weeks and then monthly for the next six months, with no signs of clinical or radiographic failure at the end of six months.

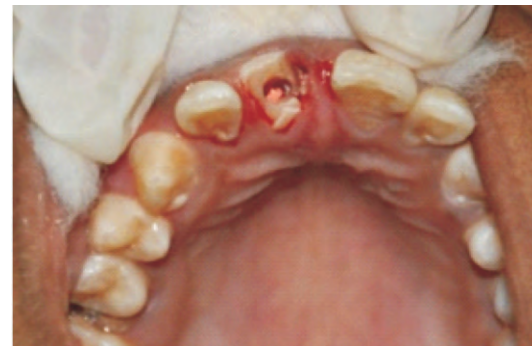

Fig. 1: One third of the gutta-percha removed after obturation.

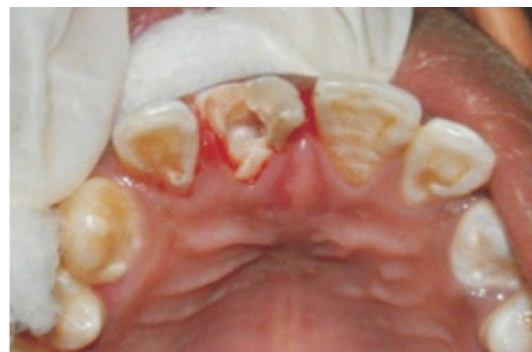

Fig.2: Clinical determination of correct position of reattachment

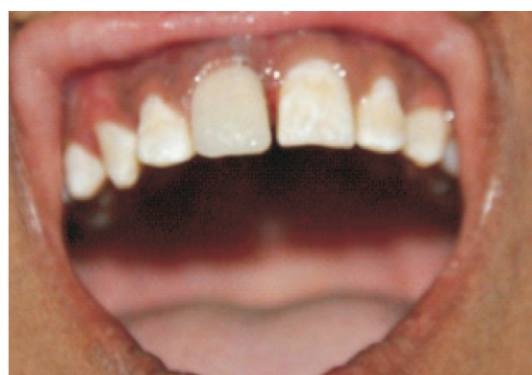

Fig.3: Post composite veneering

CASE TWO

A 12yr old girl reported to the department with a complain of injury to the upper two front teeth three days back. Clinical examination revealed a complicated crown-root fracture with the fracture line extending subgingivally and Ellis Class II fracture in relation to 21. The fractured fragment in relation to 11 showed grade II mobility. Radiographic examination revealed a complicated crown-root fracture with the fracture line extending approximately 2mm above the alveolar bone (Fig 4). Similar to case one, 11 was treated by root canal treatment and tooth fragment reattachment.

The procedural steps performed for this case were similar to case one, with the exception of gingival flap reflection to expose the fractured segment (Fig 5). The gingival flap was sutured back in position after fragment reattachment, followed by composite buildup of the tooth with composite veneering (Fig 6). Ellis Class II fracture in relation to 21 was restored with composite build up (Fig 7). The tooth was clinically and radiographically examined for the first two weeks and then monthly for the next six months. At the end of six months no clinical and radiographic failure was observed.

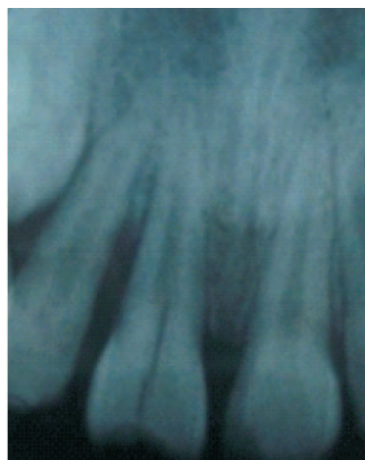

Fig.4: Pre-operative radiograph

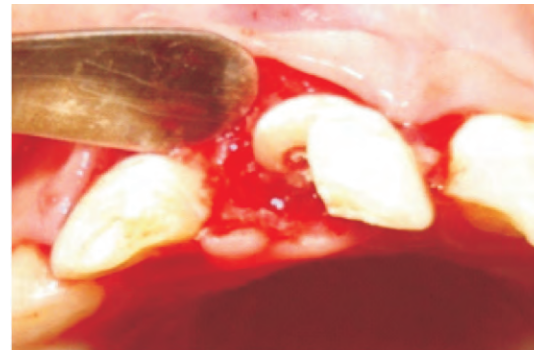


Fig.5: Gingival retraction to expose fractured segment

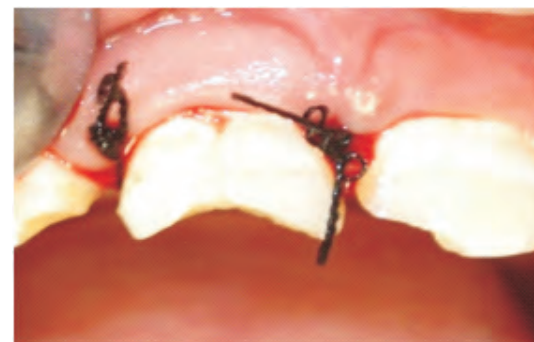

Fig.6: Gingival flap repositioned with sutures

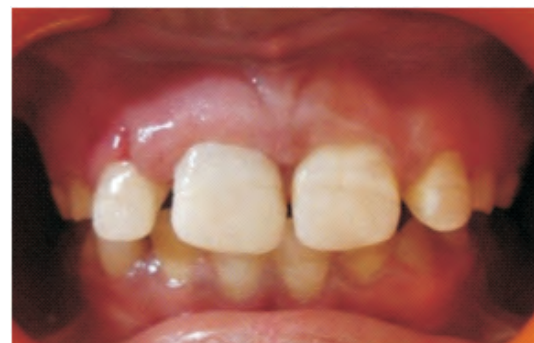

Fig.7: Post composite build-up

DISCUSSION

Many studies on the incidence of dental traumatic injuries suggest that they affect one third of the total child population. These studies have indicated that one out of every four individual under the age of 18 yrs sustain dental traumatic injuries in the form of anterior tooth fractures.^{3,4,7} Complicated crown-root fractures have a number of treatment

modalities, one of them is prosthodontic restoration with a prefabricated or custom made posts, but have the disadvantage of large pulp size in young patients and the relative instability of the gingival margin. In case of orthodontic tooth extrusion we may be faced with problems of excessive pain, damage to the tooth, failure of the tooth to extrude or tilting of the abutment tooth.² Andreasen and Andreasen in 1994 suggested that the reattachment procedure can act as an alternative procedure in young patients until the gingival margins become stable.⁹ Although the application of the rubber dam would have been the best method of maintaining isolation, it was not used in this case as the application of the clamp may have led to excessive bleeding as the base of the fracture line was subgingival. Therefore, cotton rolls and gauze pieces were used for isolation. It has been studied that the occlusal forces generated during protrusive mandibular movements are extremely destructive to the tooth fragment-bonding agent interface.¹⁰ Therefore, many authors recommend placement of composite or porcelain veneers to increase the value of strength close to that of an intact tooth¹⁰⁻¹². Vijayakumaran V¹³ showed 80% level of survival after 5 yrs in a prospective investigation made on 50 cases of reattached fragment. Cavalleri G and Zerman N¹⁴ in a clinical investigation, compared treatment of fractured crowns using direct adhesive buildup and reattachment of the tooth fragment, concluding that more esthetically stable results were achieved by tooth fragment reattachment after a 5yrs follow-up. Farik et al¹⁵ analyzed that the strength of reattached fractured tooth fragments dehydrated for more than one hour showed significant reduction in the fracture resistance which was retained after rehydration for 24hrs. Andreasen et al⁵ in

a clinical trial concluded that the reattachment of the fractured tooth fragment is a realistic alternative to composite build up. Reattachment of the tooth fragment in case of fractured anterior teeth is an economical method that ensures increased incisal strength and thus creates better function.

CONCLUSION

Reattachment of the fractured tooth fragment is a minimally invasive procedure that provides better esthetics with the advantage of being less time consuming, less elaborate and more cost effective when compared to other treatment modalities.

REFERENCES

1. Andreasen JO, Andreasen FM, Crown-root fractures. In Andreasen. JO Andreasen FM (Eds). Textbook and color atlas of traumatic injuries to the teeth (3rd ed), munksgaard, 1994;257-77
2. Chosack A, Eidelman E. Rehabilitation of a fractured incisor using the patient's natural crown — case report. J Dent Child 1964; 71: 19–21.
3. Hamilton FA, Hill FJ, Hollway PJ. An investigation of dentoalveolar trauma and its treatment in an adolescent population. Part 1: The prevalence and incidence of injuries and the extent and adequacy of treatment received. British dental journal 1997;182:91-5.
4. Andreasen JO, Ravn JJ. Epidemiology of traumatic dental injuries to primary and permanent teeth in a Danish population sample. International journal of oral surgery 1972;1:235-9.
5. Andreasen FM, Noren JG, Andreasen JO et al. Long term survival of fragment bonding in the treatment of fractured crowns: a multicenter clinical study. Quintessence Int 1995;26:669-81.

6. Reis A, Kraul A, Francci C et al. reattachment of fractured teeth: a review of literature regarding techniques and materials. *Oper dent* 2004;29:295-300.
7. Petti S, Tarsitani G. Traumatic injuries to anterior teeth in Italian school children; Prevalence and risk factors. *Endod Dent Traumatol* 1996;12:294-7.
8. GJ Brown, RR, Welbury. Root extrusion, a practical solution in complicated crown-root incisor fractures. *British Dental Journal* 2000;189(9):477-8.
9. Andreasen JO, Andreasen FM. Textbook and color atlas of traumatic injuries to the teeth (3rd ed). Copenhagen, munksgaard, 1994;240.
10. Dean JA, avery DR, swartz ML. attachment of anterior tooth fragments. *Pediatr dent* 1986;19:731-43.
11. Magne P, douglas WH. Cumulative effect of successive restorative procedures on anterior crown flexure: intact verses veneered incisors. *Quintessence int* 2009;31:5-18
12. Strassler HE. Aesthetic management of traumatized anterior teeth. *Dent clin north am* 1995;39:181-204
13. Vijayakumaran V. evaluation of crown restoration of fractured anterior teeth using original tooth fragment. *J dent res* 1998;77:696.
14. Cavalleri G, zerman N. traumatic crown fractures in permanent incisors with immature roots: a follow-up study. *Endod dent traumatol* 1995;11:294-6.
15. Farik B et al. drying and rewetting anterior crown fragment prior to bonding. *Endod dent traumtol* 1999;15:113-6.