

# Foreign Material in Root Canals: A Series of Two Cases

Kaur T<sup>1</sup>, Kochhar GK<sup>2</sup>, Bansal B<sup>3</sup>, Chachra S<sup>4</sup>

**Abstract:** Self injurious behavior is a deliberate alteration. Children often have a habit of inserting everything that comes in their hand. This case report portrays self introduced unusual foreign body and its retrieval from the root canals of the two primary maxillary anterior teeth.

**Keywords:** Foreign body, Pen nib, Pencil lead, Self injurious behavior.

## Introduction

Foreign bodies may be deposited in the oral cavity either by traumatic injury or iatrogenically. This condition is more common in children as it is a well known fact that children more often tend place foreign objects in the mouth. Sometimes the foreign objects get stuck in the root canals of the teeth which is not very often observed by parents also. These foreign objects may cause painful conditions by acting as a potential source of infection.

The occurrence of foreign bodies such as metal screws<sup>1</sup>, staple pins<sup>2</sup>, darning needles<sup>3</sup>, pencil leads<sup>4</sup>, beads<sup>1</sup> and tooth picks lodged in the exposed pulp chambers of carious or traumatically injured deciduous and permanent teeth has been reported.<sup>5</sup>

Diagnosis of these cases is often made accidentally on the radiographic examination or may be associated with pain, swelling and recurrent abscesses.

Size, location and the type of the foreign object can only be confirmed by clinical and radiographic examinations.<sup>5</sup> Retrieval of foreign objects in the root canal is a

challenging part in pediatric practice.<sup>6</sup>

This paper discusses the presence of unusual foreign body- a pen nib, in the root canal of the primary central incisor and its management.

## Case Report

### Case 1

A 4 year old male child reported to the Out Patient Department of Pedodontics and Preventive Dentistry, Swami Devi Dyal Hospital and Dental College, Barwala, Panchkula with the chief complaint of blackish discolouration and occasional pain in the upper front teeth. Pain was spontaneous, dull aching, intermittent and localised with no associated aggravating and relieving factors.

Clinical examination revealed grossly decayed primary maxillary central incisor (61). It was associated with a sinus on the labial mucosa over the tooth. (Fig.1)

Intra oral periapical radiograph revealed periapical radiolucency associated with 61 along with an unusual radio-opaque linear foreign body which appeared like a post in the root canal. (Fig. 2)

There was no history of previous dental

**Corresponding Author :** Dr. Taranjot Kaur, Reader, Department Of Pedodontics & Preventive Dentistry, Swami Devi Dyal Hospital and Dental College, Barwala, Panchkula, Haryana (India) (M) +91-9729224047,7508792012 Email : taranjot.kaur@gmail.com

1. Reader, Department Of Pedodontics & Preventive Dentistry, Swami Devi Dyal Hospital and Dental College, Barwala, Panchkula, Haryana (India)

2. Assistant Professor, Department Of Pedodontics & Preventive Dentistry, Swami Devi Dyal Hospital and Dental College, Barwala, Panchkula, Haryana (India)

3. PG Student, Department Of Pedodontics & Preventive Dentistry, Swami Devi Dyal Hospital and Dental College, Barwala, Panchkula, Haryana (India)

4. Professor & Head of the Department, Department Of Pedodontics & Preventive Dentistry, Swami Devi Dyal Hospital and Dental College, Barwala, Panchkula, Haryana (India)

treatment. On further exploration the parents confirmed that the patient had the habit of inserting foreign objects in the tooth to remove the food debris. Diagnosis of irreversible pulpitis associated with #61 along with foreign body lodgement was made.

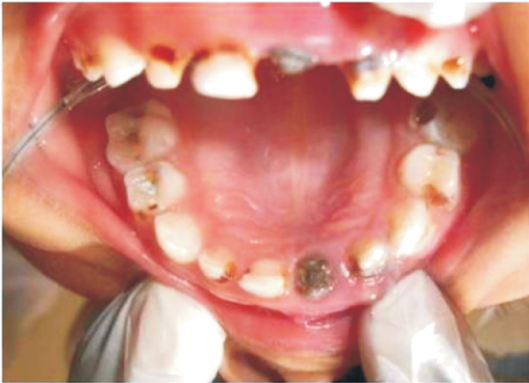

Fig. 1: Intra-oral photograph showing the foreign object in the canal and sinus opening.

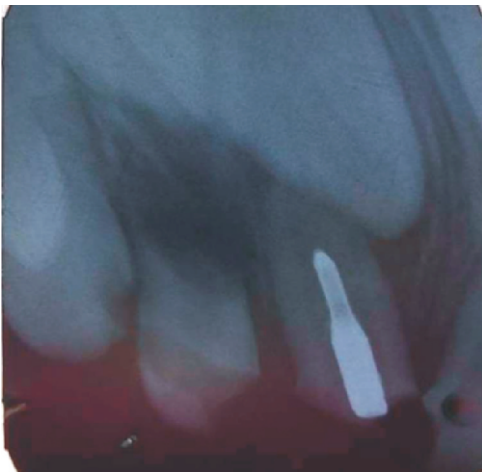


Fig. 2: Preoperative radiograph showing radiopacity in the root canal of 61 likely a foreign body.

Patient was advised to undergo endodontic therapy following the retrieval of foreign object. The food debris and the necrotic contents were removed from the pulp chamber. The foreign body was visible but it was inaccessible for removal. The object was engaged with the twizzer and pulled coronally. Pen nib approximately 1 cm long was retrieved. (Fig. 3) Canal was cleaned; dried and closed dressing was given. In the

subsequent visit canal was obturated with Endoflas paste and pulpectomy with #51 was also done. (Fig. 4)



Fig. 3 : Pen nib retrieved from the canal.

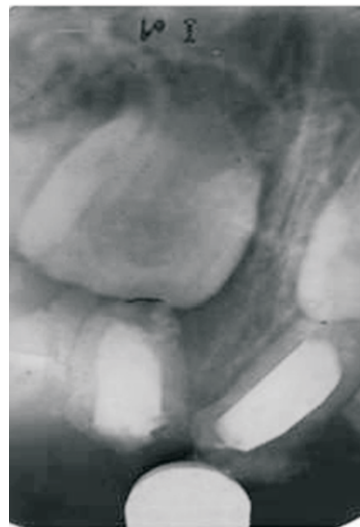


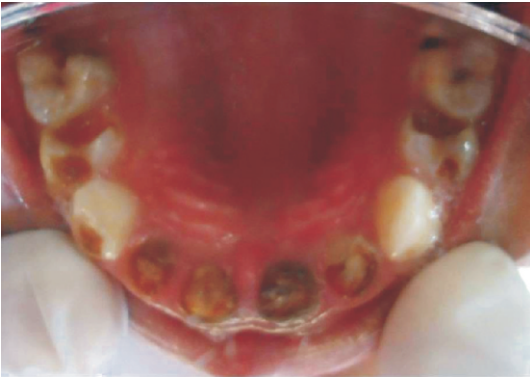Fig. 4: Post-operative radiograph with obturated 51 and 61.

Patient was kept under observation and recalled after at an interval of 3, 6 and 12 months until subsequent healing occurred.

**Case 2**

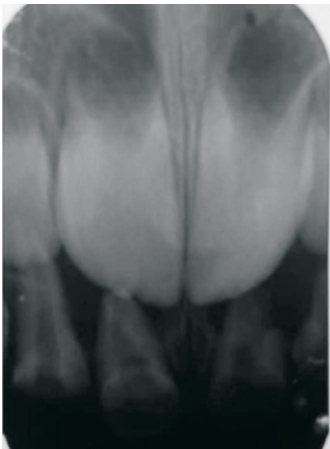
A 4 year old male child with the chief complaint of pain in the upper front teeth reported to the Out Patient Department of Pedodontics and Preventive Dentistry, Swami Devi Dyal Hospital and Dental College, Barwala, Panchkula. Pain started few days

back which was localized, spontaneous, dull aching, and intermittent in nature. Once started pain lasted for 5-7 minutes and relieved by itself. No postural variations were present. Clinical examination revealed complicated Class IX fracture with a large carious cavity of primary maxillary central incisor #61 (Fig. 5).



**Fig. 5 :** Intra-oral photograph showing the foreign object in the canal and fractured incisors.

The tooth was associated with sinus on the labial mucosa. Intra oral periapical radiograph revealed large periapical radiolucency in relation to #61. An atypical radio-opaque object appearing like a silver point was observed in the root canal of #61. (Fig. 6)



**Fig. 6:** Preoperative radiograph showing radiopacity in the root canal of 61 likely a foreign body.

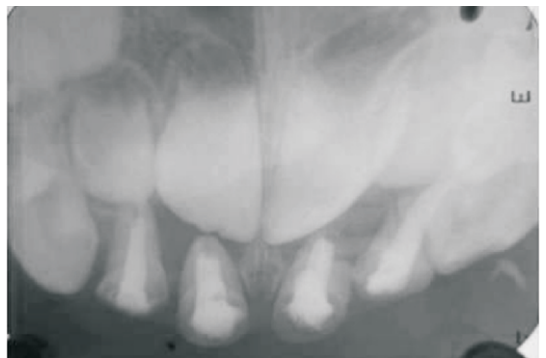
History revealed that the patient had the habit of introducing everything into the mouth. The case was diagnosed as irreversible pulpitis

with respect to #61 along with foreign body lodgement. Endodontic therapy was planned for #61. Following caries removal access was obtained and subsequently the food debris and necrotic contents were removed. Foreign body was visible but not approachable. The foreign body was engaged in the twizzer and pulled coronally. 0.8mm long pencil lead was retrieved (Fig. 7).



**Fig. 7:** Pencil lead retrieved from the canal of 61

Canal was cleaned and dried and closed dressing was given. In the successive appointment obturation was done with Endoflas paste. (Fig. 8) Patient was kept under regular observation.



**Fig. 8:** Post-operative radiograph with obturated 51, 52, 61, and 62.

## Discussion

Self-inflicted oral injuries can be premediated or accidental or can result from an uncommon habit.<sup>1</sup>

Foreign bodies discovered from the root canal have varied from radiolucent objects like wooden tooth pick, plastic chopstick, and fingernail to radio-opaque materials like staple pins, sewing needles, pencil lead etc. children often tend to insert foreign objects in their mouth, therefore it is more common to find these objects in children's teeth.<sup>7</sup> Impaction of foreign bodies in the teeth can cause pain, bleeding and infection.<sup>8</sup>

These foreign objects may act as a potent source of infection and painful conditions. To localize a radio-opaque object various radiographic methods such as Parallax views, Vertex Occlusal views, Triangulation techniques, Stereo Radiography and Tomography were suggested McAuliffe.<sup>5</sup> Moreover, Radiovisiography, 3D CAT scans can also help in the localization of the exact position of these foreign objects.<sup>9</sup>

Method of retrieval of the object from the tooth canal depends on the position where the foreign object is present. It is difficult when it is lodged in the periapical region. Prabhakar suggested the various orthograde techniques which can avoid the need for surgery or intentional reimplantation for successful recovery of a foreign object located in the apical portion of an immature root canal. Whereas, Shrivastav and Vineeta have proposed periapical surgery or intentional reimplantation to remove such foreign objects.<sup>9</sup>

Nadkarni reported a case of 12 years old child who presented with a fracture of a sewing needle in the palatal root canal of the maxillary first

molar. The fractured needle was removed with a tweezers. So removal of the foreign object was carried out causing minimal damage to the root structure.<sup>10</sup>

In our case the pen nib was visible but the grip could not be made for removal so the removal was done using a tweezer with narrow beak. Stegiltz forceps have also been described for the removal of silver points from the root canal.<sup>5</sup> Different methods used for the retrieval of foreign bodies from root canal include Masserann kit and modified Castroveijo needle holders. Some researchers recommended the use of the operational microscope with ultrasonic filing for the retrieval of metallic objects. McCulloch suggested the removal of small amount of tooth structure to get the entrapped foreign object free.<sup>7</sup>

## Conclusion

Though the presence of foreign objects retrieved from the root canal and pulp chambers of the permanent teeth have been reported, the presence of such objects in the deciduous teeth is an uncommon situation. Timely diagnosis and management of the foreign object embedded in the tooth should be done to avoid further complications.

## References

1. Passi S, Sharma N. Usual foreign bodies in the orofacial region. Case reports in dentistry. 2012; 2012:191873.
2. Aduri R, Reddy RE, Kiran K. Foreign objects in teeth: Retrieval and management. J Ind Soc Pedod Prev Dent 2009; 27(3):179-83.
3. Nernst H. Foreign body in the root canal. Quintessenz. 1972; 23(8):26.
4. Hall JB. Endodontics - Patient performed. J Dent Child 1969; 36:213-6.
5. Holla G, Baliga S, Yeluri R, Munshi AK. Unusual objects in the root canal of deciduous teeth: A report of two cases. Contemp Clin Dent. 2010; 1(4):246-8.

6. BN, Moses J, Reddy NV. Self-injurious behavior and foreign body entrapment in the root canal of a mandibular lateral incisor. *J Ind Soc Pedod Prev Dent.* 2011; 26(6):95-8.
7. Sen OG, DalkilicE ,Ungor M. An unusual foreign object in the root canal of central incisor tooth: retrieval and management. *Int J Dent Case Reports* 2012; 2(4): 85-8.
8. Chaturvedi R, Kumar A, Kumar V. Unusual foreign bodies in permanent dentition. *Indian J of Dental Research and Review* 2012:62-3.
9. Shenoi P, Kandhari A, Gunwal M. Simple means of management of teeth with foreign body in root canal. *Indian J of Multidisciplinary Dentistry* 2011; 1(2):78-81.
10. Nadkarni UM, Munshi A, Damle SG, Kalaskar RR. Retrieval of foreign object from palatal root canal of a permanent maxillary first molar: a case report. *Quintessence Int* 2002; 33(8):609-12.

**Source of Support:** NIL

**Conflict of Interest:** None Declared