

# An Unusual Case of Juvenile Psammomatoid Ossifying Fibroma Presenting as a Soft Tissue Growth: A Case Report

Gothe P<sup>1</sup>, Chidambaram YS<sup>2</sup>, Rudagi BM<sup>3</sup>, Holikatti K<sup>1</sup>

## Abstract :

Juvenile Ossifying Fibroma (JOF) is a fibro-osseous lesion which is further classified as Juvenile Psammomatoid Ossifying Fibroma (JPOF) and Juvenile Trabecular Ossifying Fibroma (JTOF). Juvenile Psammomatoid Ossifying Fibroma (JPOF) has been distinguished because of its location, clinical behaviour, and age of occurrence. It is generally seen in younger age group and occurs more commonly in paranasal sinuses, orbits, and fronto-ethmoidal complex. The lesion has showed a potential to proliferate, invade and destroy tissues extensively. It is also important to note that this lesion has a very strong tendency to reoccur. Complete excision of the lesion is the treatment of choice and it can be curative. In this case paper we are describing an unusual case of JPOF involving the posterior mandible and clinically presenting as a soft tissue overgrowth.

**Keywords:** Fibro Osseous Lesion, Juvenile Ossifying Fibroma (JOF), Psammomatoid, Trabecular.

## Introduction

Ossifying fibromas (OF) of the craniofacial skeleton, as described in WHO classification of odontogenic tumors are benign fibro-osseous neoplasm's characterized by the replacement of normal bone by a fibrous cellular stroma containing foci of mineralized bone trabeculae and cementum-like material that vary in amount and appearance<sup>1</sup>. Ossifying Fibromas are classified in to Conventional OF and Juvenile OF. The juvenile ossifying fibroma is also known as "Aggressive ossifying fibroma or Active ossifying fibroma".<sup>2</sup> It has been distinguished from the larger group of ossifying fibroma on the basis of age of occurrence, most common site of

involvement and clinical behaviour.<sup>3</sup>

Juvenile ossifying fibroma (JOF) is further divided into juvenile trabecular ossifying fibroma (JTOF) and juvenile psammomatoid ossifying fibroma (JPOF). JPOF has been distinguished because of its location, clinical behaviour, and age of occurrence. It is generally seen in younger individuals and occurs overpoweringly in paranasal sinuses, orbits, and fronto-ethmoidal complex where as JTOF has fondness for the jaw bones especially the maxilla<sup>4</sup>. In this case paper we are describing an unusual case of JPOF involving the posterior mandible and clinically presenting as a soft tissue overgrowth.

**Corresponding Author :** Dr. Pavan Gothe, Sr. Lecturer, Department of Oral Pathology and Microbiology, A.C.P.M Dental College, Dhule-424001, Maharashtra, India (M)+91-9164518365 E-mail: gothe.pavan14@gmail.com

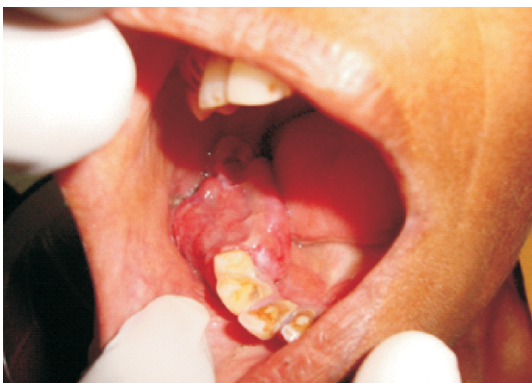1. Senior Lecturer, Department of Oral Pathology and Microbiology, ACPM Dental College, Dhule, Maharashtra.

2. Reader, Department of Oral and Maxillofacial Surgery, ACPM Dental College, Dhule, Maharashtra.

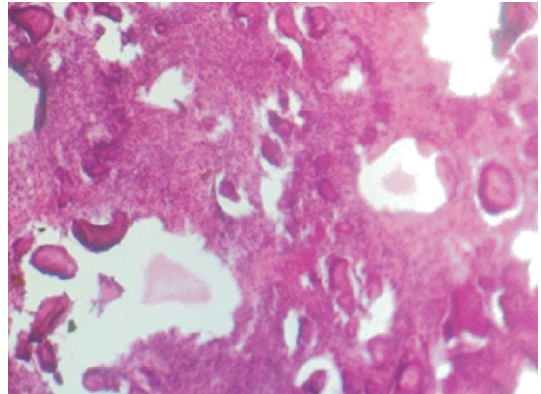
3. Professor, Department of Oral and Maxillofacial Surgery, ACPM Dental College, Dhule, Maharashtra.

## Case Report

A 42 year old female patient presented with a chief complaint of swelling in the right side of the face since from 3 years. The patient was well built and she was a known diabetic since 2 years. She had no other relevant medical history. Intraoral examination revealed a single large growth measuring about 2 x 4 cm is seen in the right side of the alveolar ridge over 45, 46, 47 & 48 regions. The growth was smaller in size initially and has grown gradually to the present size. Overlying mucosa was erythematous and the growth was sessile and confluent with the underlying hard tissue. Growth was firm in consistency and nontender on palpation. Clinically 45, 46 & 47 were missing and 48 was firm but showed slight displacement posteriorly (Fig.1). Patient gave the history of exfoliation of the missing teeth 2 years back. Radiograph showed a radiolucent area with focal radioopacities. Incisional biopsy revealed cellular connective tissue consisting of stellate and spindle shaped cells. Multiple foci of acellular osteoid were noted which resembled the psammoma bodies (Fig. 2). Diagnosis of Psammomatoid ossifying fibroma was arrived at and surgical excision of the lesion was carried out.



**Fig. 1:** Intraoral photograph showing swelling on the mandibular right alveolar ridge



**Fig. 2:** Low power photomicrograph showing multiple round ossicles resembling 'psammoma' bodies interspersed in a cellular connective tissue stroma (100X).

## Discussion

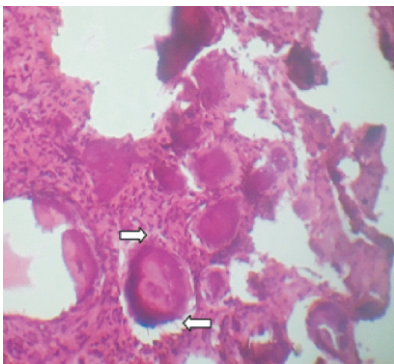
JOFs are benign, potentially aggressive fibro-osseous lesions of the craniofacial bones. The word "Psammomatoid" is derived from Greek word "psammos" which means sand<sup>4</sup>. JPOF shows fondness for the orbit and paranasal air sinuses accounting for about 72% of cases followed by calvarium, maxilla, and mandible<sup>5</sup>. Among the sinuses, JPOF generally involves the ethmoidal sinus followed by the frontal sinus, maxillary sinus and sphenoid sinus<sup>6</sup>.

JPOF occurs most commonly occurs in males and in the younger age group<sup>7</sup>. The lesion has showed a potential to proliferate, invade and destroy tissues extensively<sup>8</sup>. It is also important to note that this lesion has a very strong tendency to recur and recurrence rates as high as 30%-56% are reported<sup>9</sup>. The present case was a middle aged female patient with swelling on the right posterior mandible, which makes it a rare presentation since JPOF occurs in younger age group and mainly occurs in the bony walls of the paranasal sinuses<sup>1</sup>.

Radiographically, JOFs show mixed radiolucent and radiopaque areas depending

up on the degree of calcification. The lesion can cause root resorption, cortical expansion as well as perforation<sup>10</sup>. Juvenile ossifying fibromas tend to be more radiopaque than conventional lesions and sometimes may have a 'ground glass' appearance or may form dense lobulated masses.<sup>11</sup>

Histologically JPOFs show densely cellular connective tissue stroma that has a whorled appearance composed of uniform, stellate, and spindle shaped cells. Multiple small acellular calcified structures, round and uniform and with concentric lamellar calcification, are observed which resemble the typical "psammoma bodies". They may have a peripheral brush borders which was also seen in our case (Fig. 3). The psammomatoid bodies are basophilic and bear superficial resemblance to dental cementum, but may have an osteoid rim.<sup>12</sup> Mineralization is often not complete so that only areas of hyalinized collagen or osteoid are seen. Elsewhere the psammoma bodies may be densely mineralized and basophilic with resting and reversal lines or they may fuse into globular masses. Sheets of osteoblast-like cells resembling osteoblastoma may also be seen and scattered normal mitoses are encountered. Occasional psammomatoid calcifications will often be seen in the trabecular variant and



**Fig. 3:** High power photomicrograph showing the brush border of the ossicles (arrows) (400X).

trabeculae are often seen in psammomatoid lesions, especially towards the periphery.<sup>11</sup> Cystic degeneration and aneurysmal bone cyst like formation is commonly reported.<sup>13</sup>

The clinical differential diagnoses include aneurysmal bone cyst, central giant cell granuloma, osteogenic sarcoma, osteoblastoma, odontogenic cysts and tumors. Histologic differential diagnoses include focal cemento osseous dysplasia (FCOD), fibrous dysplasia (FD), psammomatous meningioma and central cementifying fibroma.

FCOD is a non-neoplastic process that occurs around the roots of mandibular teeth and fails to expand bone. Instead OF is a potentially aggressive lesion that causes cortical expansion and often causes divergence of adjacent teeth. Both lesions may show similar histological features with trabecular bone and cementifying areas.

In contrast to FD, JPOF shows osteoclasts and osteoblasts characteristically lining the trabeculae, which are composed of entrapped lamellar bone.

Psammomatous meningioma is histologically indistinguishable from JPOF. However both can be distinguished by immunohistochemistry. Epithelial membrane antigen (EMA) is frequently negative in JPOF however few cases have reported positivity. JPOF is negative for S100, CD34 and cytokeratins. Thus the diagnosis should be based on morphological, clinical and radiographic findings.<sup>4,14,15</sup>

Central cementifying fibroma consists of fibrous stroma with dense cellularity and small spherical basophilic calcifications (cementicles).

Complete excision of the lesion is the treatment of choice and it can be curative. Radiotherapy is generally contraindicated

because of the risk of malignant transformation and the potentially harmful late effects in children.<sup>16</sup>

### Conclusion

JPOF is an aggressive neoplasm that is most commonly encountered in children, however it can rarely occur in elderly individuals and seen mainly as intrabony mass. In the present case it was mimicking as a soft tissue growth. Hence it becomes important to diagnose such cases accurately and treat accordingly. Histologic criteria for the accurate diagnosis remain controversial since many other lesions share the similar histologic features. Diagnosis should be based on morphological, clinical, radiographic and histologic findings. Complete resection is advised since partial removal of tumor is associated with the risk of recurrences.

### References

1. Barnes L, Eveson J, Reichart P, Sidransky D, editors (2005). "World Health Organization. Classification of Tumours, Pathology and Genetics of Head and Neck Tumours. Lyon." IARC Press: 283–328.
2. Neville BW, Damm DD, Allen CM, Bouquot JE: Bone pathology. In: Oral and Maxillofacial Pathology. 2nd Edn.; Elsevier a division of Reed Elsevier, India Pvt. Ltd. New Delhi, 2002, pp564–6.
3. Granados R, Carrillo R, Najera L, Villanueva MG, Patron M: Psammomatoid ossifying fibroma: Immunohistochemical analysis and differential diagnosis with Psammomatous meningiomas of craniofacial bones: Oral Surgery, Oral Medicine, Oral Pathology, Oral Radiology and Endodontics, 2006;101(5):614–9.
4. Sarode SC, Sarode GS, Wanknis P, Patil A, Jashika M. Juvenile psammomatoid ossifying fibroma: a review. Oral Oncol. 2011 Dec;47(12):1110–6.
5. Guruprasad R, Gupta SD, Dua N, Mehta R. Juvenile psammomatoid ossifying fibroma: A case report. People's J Sci Res. 2011;4:31–4.
6. Chrcanovic BR, Freire-Maia B. An expanded juvenile ossifying fibroma in maxillary sinus: A case report. J Korean Assoc Oral Maxillofac Surg. 2011;37:127–32.
7. Malathi N, Radhika T, Thamizhchelvan H, Ravindran C, Ramkumar S, Giri G, et al. Psammomatoid juvenile ossifying fibroma of the jaws. J Oral Maxillofac Pathol. 2011;15:326–9.
8. Weing BM, Vinh TN, Smirnitopoulos JG, Fowler CB, Houston GD, Heffner DK. Aggressive psammomatoid ossifying fibromas of the sinonasal region. A clinicopathological study of a distinct group of Fibro-Osseous Lesions. Cancer 1995;76:1155–65.
9. Waldron CA. Fibro-osseous lesions of the jaws. J Oral Maxillofac Surg 1993;51:828–35.
10. El-Mofty S. Psammomatoid and trabecular juvenile ossifying fibroma of the craniofacial skeleton: Two distinct clinicopathologic entities. Oral Surg Oral Med Oral Pathol Oral Radiol Endod 2002;93:296–304.
11. Paul M. Speight, Roman Carlos. Maxillofacial fibro-osseous lesions. Current Diagnostic Pathology (2006) 12, 1–10.
12. Bruno Carvalho, Manuel Pontes, Helena Garcia, Paulo Linhares and Rui Vaz. Ossifying Fibromas of the Craniofacial Skeleton. Histopathology – Reviews and Recent Advances.
13. Su, L., D. R. Weathers, et al. (1997). "Distinguishing features of focal cemento-osseous dysplasias and cemento-ossifying fibromas: I. A pathologic spectrum of 316 cases." Oral Surg Oral Med Oral Pathol Oral Radiol Endod 84(3): 301–9.
14. Hasselblatt, M., G. Jundt, et al. (2005). "Juvenile psammomatoid ossifying fibroma of the neurocranium. Report of four cases." J Neurosurg 102(6): 1151–4.
15. Noudel, R., E. Chauvet, et al. (2009). "Transcranial resection of a large sinonasal juvenile psammomatoid ossifying fibroma." Childs Nerv Syst 25(9): 1115–20.
16. Nakagawa, K., Y. Takasato, et al. (1995). "Ossifying fibroma involving the paranasal sinuses, orbit, and anterior cranial fossa: case report." Neurosurgery 36(6): 1192–5.

<p><b>Source of Support:</b> NIL  <b>Conflict of Interest:</b> None Declared</p>
--