

## A Simple Template to Locate Position of the Access Hole in Cement Retained Implant Crowns

Harianawala H<sup>1</sup>, Sethi T<sup>1</sup>, Kantharia N<sup>1</sup>, Kheur M<sup>2</sup>, Jambhekar S<sup>3</sup>

### Abstract

With the use of implant therapy and its various benefits in dentistry, comes a handful of post treatment complications. The most commonly reported technical complication in implant retained restorations is screw loosening. In screw retained crowns, accessing the access hole is simple and it can be tightened immediately. In contrast, cement- retained crowns do not provide access to the abutment screw as they lack an access hole. Retrieving this type of restoration often may lead to damage of the components. This clinical tip presents the use of a vacuum formed template that can be conveniently used to locate the occlusal position of the abutment screw in the event of a screw loosening for cement retained crowns.

**Keywords:** Screw Loosening, Template, Access Hole.

Osseointegrated implants have revolutionized the treatment of edentulous and partially edentulous situations. Implant supported restorations can either be screw-retained or cemented on standard or customized abutments. Both the cement- retained and screw- retained restorations have their inherent advantages and disadvantages in clinical applications. The major advantage of screw-retained restorations are their retrievability and lesser potential for biological complications.<sup>1,2</sup> However, these restorations exhibit limited tolerance for the implant position and angulation due to the presence of an access hole which should preferably be located in non visible areas of restorations. Furthermore, the technical fabrication of screw- retained restorations is also more complex and

demanding than cement- retained restorations. Due to the ease of fabrication, adjustments and wide range of clinical applications, the cement retained restorations are more commonly used and have become the restoration of choice especially for posterior regions.

The most commonly reported technical complication in implant retained restorations is screw loosening.<sup>3</sup> However, the design of a screw-retained restoration permits easier management of the situation with ease in accessing and retrieving the screw , thus avoiding the need for complicated procedures/remakes of restorations.<sup>1,2</sup>

In contrast, cement- retained crowns do not provide access to the abutment screw as they lack an access hole. Retrieving this type of

---

**Corresponding Author :** Dr. Tania Sethi, PG Student, Dept of Prosthodontics, M.A. Rangoonwala Dental College and Research Centre, Pune, India. (M) +91 8793377303, +91 9823004331 Email : drtaniasethi@gmail.com

1. PG Student, Department of Prosthodontics, M.A. Rangoonwala Dental College and Research Centre, Pune, India.

2. Professor, Department of Prosthodontics, M.A. Rangoonwala Dental College and Research Centre, Pune, India.

3. I.T.I. Scholar and Lecturer, Terna Dental College, Navi Mumbai.

restoration often may lead to damage of the components, needing the clinician to remake the restoration, thereby increasing costs, time and effort.

Various techniques to manage the screw loosening have been reported in literature like staining of ceramic<sup>4</sup>, fabrication of a putty index<sup>5</sup>, use of a removing driver<sup>6</sup> and the use of digital photography<sup>7,8</sup>. However, these techniques provide an estimated guess for the position of access hole of the abutment. This may not be adequate information especially in clinical situations when custom and/or angled abutments have been utilized.

This report presents a simple, innovative and cost effective technique using a vacuum formed template to record and store the position of the abutment screw. This rescue template allows accurately locating and accessing the abutment screw in the event of

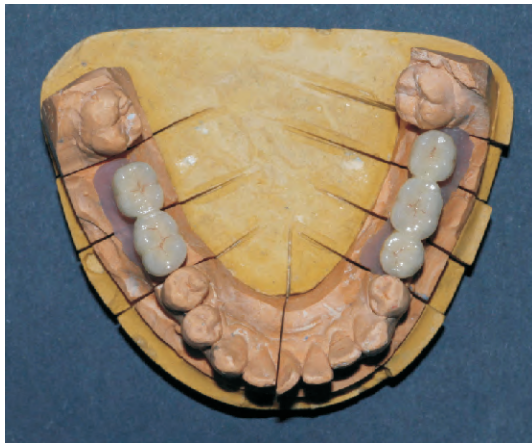

Fig 1: Definitive restorations

1. With the definitive restorations on the master cast, a vacuum formed sheet (12.7cm X 12.7cm, Proform, USA) is used to fabricate a template/stent.

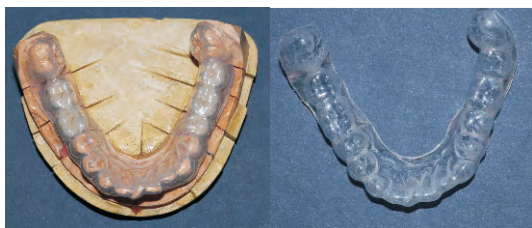

Fig 2: Stent fabricated on working cast

2. The stent is repositioned onto the cast after removing the restorations from the abutments. The positions of the access holes are marked onto the occlusal surfaces of the stent using a permanent marker. Also the angulation of the abutment is marked on the buccal and lingual surface of the stent.

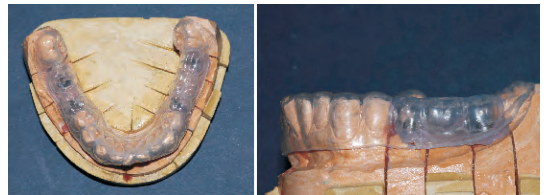

Fig 3: Repositioning stent and marking of access hole

3. A hole is drilled through this occlusal mark using a bur or a hot instrument.

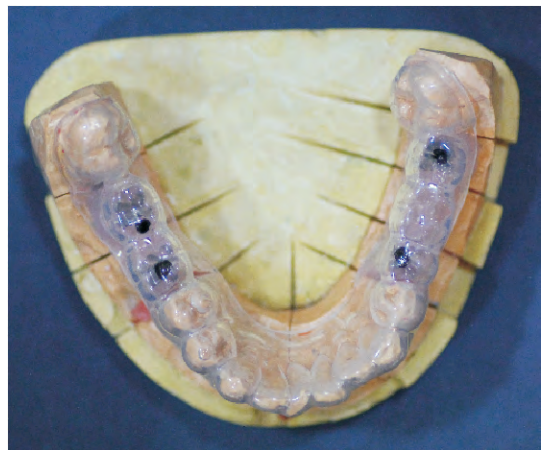

Fig 4: Access hole drilled through stent

4. The holes are verified by passing a cylindrical instrument through the stent and into the abutment.
5. A photographic record of the location is also made as an additional visual record.

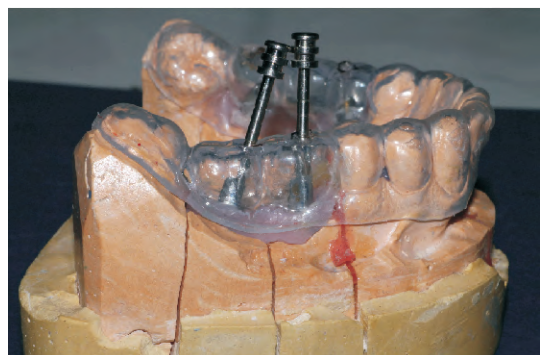


Fig 5: Location of access hole to abutments

6. In event of abutment screw loosening, this rescue template is seated intraorally. The marking will allow accurate drilling of an access hole through the restoration towards the abutment screw.

### Discussion

Advantages of this technique include its ability to be used in single/multiple implant restorations with custom/angulated abutments as well as multiple implants in the same arch. It allows accurate location of the position of the access hole thus avoiding damage to restoration, abutment and other components. It saves chairside time in the event of a screw loosening in future.

### Conclusion

The vacuum formed sheet is used as a guide for the location of the access for the abutment screw. In situations where implants are non-axially placed, as commonly happens in the posterior regions of the jaws, the position of the access to the abutment may not coincide with the central fossa of the tooth.

### References

1. Shadid R, Sadaqa N. A Comparison Between Screw- and Cement-Retained Implant Prostheses. A Literature Review. *J Oral Implantol* 38(3):298-307.
2. Sailer I, Muhlemann S, Zwahlen M, Hammerle CH, Schneider D. Cement and screw-retained implant reconstructions: a systematic review of the survival and complication rates. *Clin Oral Implants Res* 2012 oct, 23 Suppl 6:163-201.
3. Weber HP, Sukotjo C. Does the type of implant prosthesis affect outcomes in the partially edentulous patient? *Int J of Oral Maxillofac Implants* 2007, 22 Suppl: 140-72.
4. Schwedhelm ER, Raigrodski AJ. A technique for locating implant abutment screws of posterior cement-retained metal-ceramic restorations with ceramic occlusal surfaces. *J Prosthet Dent* 2006;95(2):165-7.
5. Hill EE. A simple, permanent index for abutment screw access for cemented implant-supported crowns. *J Prosthet Dent* 2007; 97(5):313-4.
6. Okamoto M, Minagi S. Technique for removing a cemented superstructure from an implant abutment. *J Prosthet Dent* 2002, 87(2):241-2.
7. Figueras-Alvarez O, Cedeno R, Cano- Batalla J, Cabratosa-Termes J. A method for registering the abutment screw position of cement-retained implant restorations. *J Prosthet Dent* 2010;104(1):60-2.
8. Patil PG, Patil SP. Occlusal-view photograph of a cement-retained implant prosthesis as a permanent guide for access-hole preparation. *J Prosthet Dent* 2013;109:343-4.