

# Guided Implant Surgery Using A Tissue Level Stent : A Clinical Application

Kantharia N<sup>1</sup>, Harianawala H<sup>1</sup>, Kheur M<sup>2</sup>

## Abstract

The revolution in computer software programs and 3D radiographic techniques has greatly influenced the implant surgery. Guided implant surgery helps in determining pre-surgically, the most optimal implant position hence, producing less post-operative pain, swelling, shorter surgery time, reduced healing period etc. This article is a case report providing an insight into the level of accuracy attained in the placement of implants by using a surgical guided stent, hence enlightening the privileges and the procedure of this sophisticated approach which has modified the mode of treatment in the field of restorative dentistry.

**Keywords :** Guided Stent Surgery, Computer-Aided / Computer-Assisted, Stereolithography.

## Introduction

According to the concept of prosthetically driven implantology, the position of the implant has to be planned during the diagnostic phase of the treatment.<sup>1</sup> With the advances in the field of implantology, new devices and techniques have been introduced which provide function, aesthetics and comfort with a minimally invasive surgical approach.

The position of the implant should be judged according to the following three criteria<sup>2</sup>:

- (i) Implant should remain completely covered by the bone or bone replacement material at the apex and along the sides.
- (ii) Implant should be placed at a safe distance from the significant anatomic structures like mandibular nerve, sneiderian membrane, incisive canal etc.
- (iii) The final position of the implant should

be compatible with the planned definitive restoration.

This demand for high accuracy in the positioning of the implant can be accomplished by computed tomography, 3D implant planning software, image-guided stent production techniques and computer aided navigation surgery.<sup>3</sup> The above mentioned techniques, navigated systems and surgical guided stent systems for transferring the prosthetic plan to surgical field, are not statistically different in their accuracy of implant positioning.<sup>4</sup>

Computer assisted surgical guided stents are developed by two different techniques namely:

- (a) A rapid prototyping additive process called stereolithography;
- (b) A numeric controlled subtractive process of computer assisted milling.

**Corresponding Author :** Dr. Nidhi Kantharia, Dept of Prosthodontics, M A Rangoonwala College of Dental Sciences and Research Centre, Pune, Maharashtra. (M) +91-9595398928 Email: nidhikantharia12@gmail.com

1. PG student, Dept of Prosthodontics, M A Rangoonwala College of Dental Sciences and Research Centre, Pune, Maharashtra.

2. Professor and PG Guide, Dept of Prosthodontics, M A Rangoonwala College of Dental Sciences and Research Centre, Pune, Maharashtra.

In stereolithography, a LASER is used for illuminating a basin of light polymerizing resin and developing a model layer by layer.<sup>5</sup>

Literature has reports that have shown that the use of computer designed stereolithography guides can lead to deviation of the implant in its post-operative position from the pre-operative plan.<sup>6</sup>

This case report provides an insight into the level of accuracy attained in the placement of implants by using a surgical guided stent and highlights the advantages of this technique over conventional.

### Materials and Method

A Double scan method(In2Guide™ Software, Cybermed Inc) is utilized as it is recommended for completely edentulous patients with few or no supporting teeth.

For fabricating a scan denture, a minimum number of 8 radio opaque markers (gutta-percha points) are attached to the buccal and labial flange of the denture in a zigzag pattern. This pattern of positioning the markers prevents their overlapping when viewed tangentially along the bucco-palatal aspect. The computer converter program is set to recognize the size and density of the markers. The first scan( i-CAT vision, Imaging Sciences International, Inc, Hatfield, PA, USA) is taken of the patient with the scan denture in the mouth. The denture should be in close approximation to the mucosal surface. The second scan is taken of the scan denture individually. This creates two different Dicom files which are imported into the converter part of the program. The converter translates the Dicom files to software specific file format. (Fig. 1)

According to the ISO threshold value set by the operator, the three dimensional surface is drawn in a volumetric data. Both the virtual

models created, are then paired. In most of the cases the computer automatically recognizes the radio opaque markers (gutta-percha points) of both the scans and superimposes the files accordingly. .

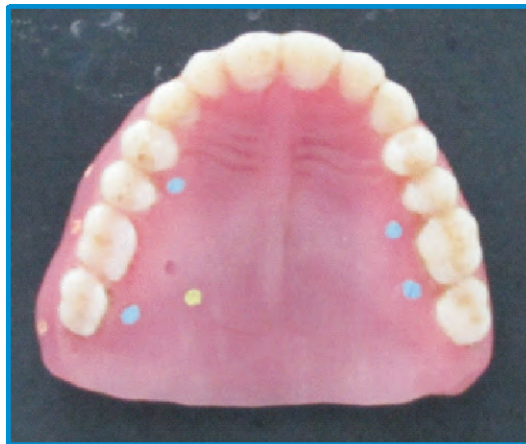

Fig. 1- The radioopaque markers (gutta-percha points) attached to the scan denture in a zigzag pattern.

This results in a file with a scan denture which is clearly demarcated from the mucosal surface. Next, this file is imported into the planning module of the software (On Demand 3D™, Cybermed). This software helps in virtual positioning of the implants as per the desired prosthesis; giving simultaneous consideration to the bone and significant anatomical structures around.

After obtaining the approval from the operator for the implant positions, the proposed model of the surgical guide is sent to the production faculty via the internet. The surgical guided stent is manufactured based on the information provided by the scan denture along with the guide sleeves incorporated in the stent as per the planned position of the implants.<sup>7</sup>

### Case Report

A 57 years old male reported to the department of Prosthodontics for the replacement of missing maxillary teeth. The

patient had lost his maxillary posterior teeth 4 years ago and underwent extraction of the anteriors 3 months prior to implant placement. He was wearing an interim complete denture. The medical history of the patient was uneventful. An implant supported fixed restorative option was explained to the patient for his approval. Following his desire to have the same, the following procedures were carried out.

#### A. Obtaining the Cone Beam Computerized Tomography (CBCT) scan.

The diagnostic impressions were made using irreversible hydrocolloid (Chromatic Jeltrate, Dentsply) and the casts were articulated to plan for the fixed implant supported restoration. The denture was relined so as to ensure close adaptation of the intaglio surface of the denture with the mucosa. 16 radio opaque markers( gutta-percha points) were attached along 8 teeth in the denture-maxillary central incisors, maxillary canines, maxillary first premolars and first molars of either sides; both on the buccal and palatal flanges of the denture. The markers were attached in a zigzag pattern. The CBCT scan(i-CAT vision, Imaging Sciences International, Inc, Hatfield, PA, USA) was carried out with the scan denture in the mouth. Another CBCT scan of the denture individually was recorded.

Both the scans superimposed to obtain a single file with scan denture and demarcated mucosal surface. (Fig. 2 & 3)

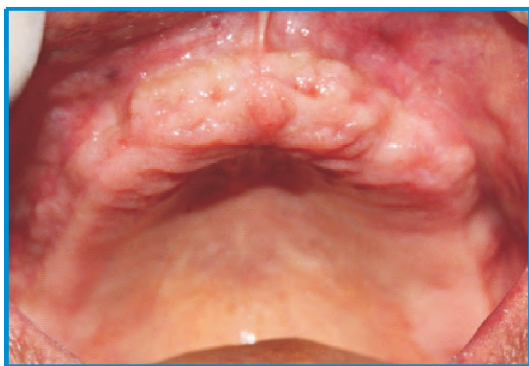

Fig. 2- Pre-operative intraoral picture.

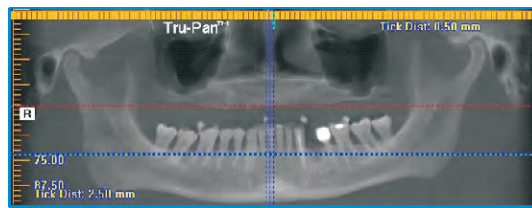


Fig. 3- Pre-operative intraoral orthopantomogram with scan denture placed intraorally.

#### B. Virtual positioning of the implant

After thoroughly studying the scans, 8 implants in the position of maxillary lateral incisors, maxillary canines, maxillary first and second premolars on either sides of the arch were planned. During this phase best possible surgical and prosthetic location of the implant site was chosen taking care to ensure adequate bone was present along the perimeter of the implant. (Fig. 4)

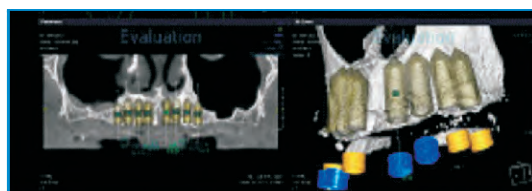


Fig. 4- The plan showing the virtual positioning of the implants in the mouth pre-surgically.

#### C. Fabricating stereolithographic stent and placing implants using surgical guided stent.

Upon finalizing the position of the implants, the order for fabrication of the guided stent was placed via the internet. On the day of surgery, the patient was administered 1000 mg Amoxicillin 1 hour prior to surgery. The surgical site was anaesthetized and the surgical guided stent was fixed using stabilising screws (dimension 2x20mm) provided along with the stent. The surgical kit used for initial osteotomy preparation was a universal kit. (In2Guide™ Universal Kit, Cybermed Inc). The length of the osteotomy was controlled by the length of the sleeve in the stent plus the depth of the mucosa. The depth of the mucosa was measured by the



manufacturer and compensated for in the length of the sleeve. Sequential drilling was carried out through the stent sleeves. After the final drill, the stent was removed and the implants (Biohorizons Implant Systems, Inc, USA) were placed respectively in their sites of osteotomy. (Fig. 5, 6 & 7)

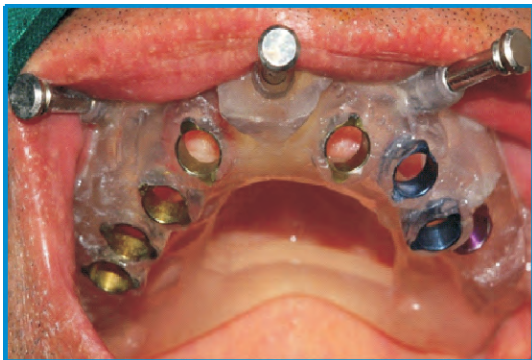

Fig. 5- The stereolithographic guided surgical stent stabilized in the mouth.

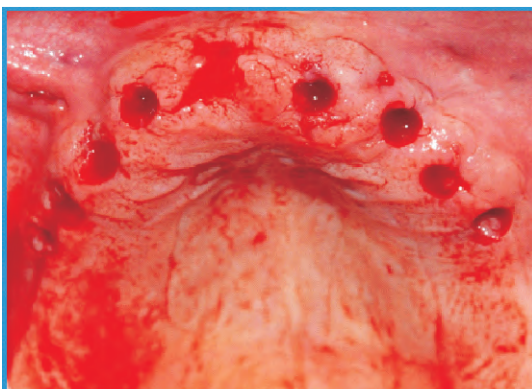

Fig. 6- The osteotomy sites prepared using the guided stent.

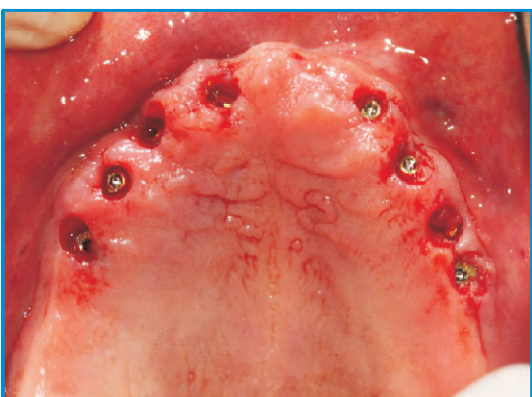


Fig. 7- Implants placed in their respective osteotomy sites.

A scan(i-CAT vision, Imaging Sciences International, Inc, Hatfield, PA, USA) was taken to ascertain the positioning of the implants 1 week after surgery. (Fig. 8)

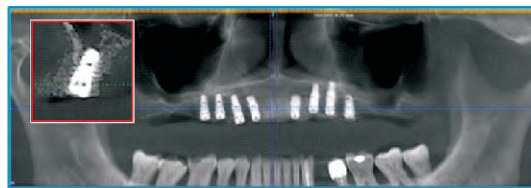


Fig. 8- Post-operative orthopantomogram taken 1 week after the surgery. Inset picture showing the accuracy of the implant position in the bone (Region of 15) as planned virtually pre-surgically.

### Discussion

The oral cavity is relatively a restricted space which requires a high degree of precision in placement of implants. A slight deviation from the ideal position can result in difficulty in fabrication of final prosthesis and can hamper the final functional and aesthetic outcome of the treatment.<sup>8</sup> A guided surgical stent ensures the accurate three dimensional positioning of the implant in the bone.

Some of the advantages of this technique are that it is a minimally invasive, flapless surgical procedure, with reduced surgical time and reduced post operative complications. It is preferred in patients who are medically compromised or anxious or in whom bone grafting is not required.<sup>6</sup>

Many reports have documented the significant linear and angular deviation in the implant position, resulting due to stereolithographic shrinkage or magnification errors in the CBCT scans.<sup>7</sup> Hence, some authors believe in maintaining a safety zone of at least 2mm from vital anatomical structures to avoid complications.

For a completely edentulous patient, 2 types of guided stents are available namely, tissue supported guided stents and bone supported guided stents.<sup>3</sup> As bone supported stents

require the reflection of flap for stent stabilization, they are not indicated while performing minimally invasive procedure.

In spite of its documented advantages, some authors have reported that flapless guided surgery can hamper visibility and tactile control during surgical procedures which might increase the risk of damaging the vital anatomical structures.<sup>9</sup> But keeping the advent of revolution by computer assisted techniques in mind, flapless implant surgery is an influential treatment option in today's era of implantology.

## References

1. Talwar N, Singh BP, Chand P, Pal US. Use of diagnostic and surgical stent: a simplified approach for implant placement. *J Indian Prosthodont Soc.* 2010 Dec;10(4):234-9.
2. Brief J, Edinger D, Hassfeld S, Eggers G. Accuracy of image-guided implantology. *Clin Oral Implants Res.* 2005;16:495-501.
3. Ramasamy M, Giri, Raja R, Subramonian, Karthik, Narendrakumar R. Implant surgical guides: From the past to the present. *J Pharm Bioallied Sci.* 2013 Jun;5(Suppl 1):S98-S102.
4. Rupp J, Popovic A, Strauss M, Spüntrup E, Steiner A, Stoll C. Evaluation of the accuracy of three different computer-aided surgery systems in dental implantology: optical tracking vs. stereolithographic splint systems. *Clin Oral Implants Res* 2008; 19:709-716.
5. Lal K, White GS, Morea DN, Wright RF. Use of stereolithographic templates for surgical and prosthodontic implant planning and placement. Part I. The concept. *J Prosthodont* 2006; 15:51-58.
6. D'haese J, Van De Velde T, Komiyama A, Hultin M, De Bruyn H. Accuracy and complication using computer designed stereolithographic surgical guides for oral rehabilitation by means of dental implants: a review of the literature. *Clin Implant Dent Relat Res.* 2012 Jun;14(3):321-35.
7. Stumpel LJ. Deformation of stereolithographically produced surgical guides: an observational case series report. *Clin Implant Dent Relat Res.* 2012 Jun;14(3):442-53.
8. Takeshita F, Suetsugu T. Accurate presurgical determination for implant placement by using computerized tomography scan. *J Prosthet Dent.* 1996;76:590-1.
9. Azari A, Nikzad S. Flapless implant surgery: review of the literature and report of 2 cases with computer-guided surgical approach. *J Oral Maxillofac Surg.* 2008 May;66(5):1015-21.